

FIRST RUSSIAN EXPERIENCE WITH ENDOVASCULAR BALLOON OCCLUSION OF THE AORTA IN A ZONE OF COMBAT OPERATIONS

REVA V.A., PETROV A.N., SAMOKHVALOV I.M.

Field Surgery Department, Military Medical Academy named after S.M. Kirov under the Ministry of Defence of the Russian Federation, Saint Petersburg, Russia

Resuscitative endovascular balloon occlusion of the aorta has increasingly been used all the world over for arresting ongoing intraabdominal and intrapelvic bleeding accompanied by unstable haemodynamics. However, the use of resuscitative endovascular balloon occlusion of the aorta in a zone of military operations has been limited to sporadic cases only. This article deals with 3 clinical case reports regarding rendering medical care for the wounded presenting with extremely unstable haemodynamics and/or a terminal state in a field hospital, where insertion of a balloon into the aorta made it possible to stabilize the condition, to perform the basic scope of diagnosis, and to finally control the continuing bleeding: in one case – intraabdominal (due to splenic rupture) and in 2 cases – intrapelvic (unstable fractures of pelvic bones). In two cases, despite low readings of blood pressure, puncture of the femoral artery was performed «blindly» and in one case – in an open fashion. The balloons used were the 7 Fr Rescue Balloon (Japan) and 10 Fr balloons manufactured by the Limited Liability Company “Minimally Invasive Technologies” (Russia).*

The balloons were positioned in the aorta also «blindly» and only in one case we managed to perform an X-ray examination confirming the correct position of the balloon. The mean time of occlusion of the thoracic aorta in the survivors amounted to 20 minutes. The operations were accompanied by intensive therapy and massive haemotransfusion. The introducers were removed using the fascia suture technique (without closure of the arterial wall). Two of the three wounded were saved, to be evacuated to a central hospital and discharged 170 and 75 days thereafter, which was due to long-term treatment of severe concomitant fractures of pelvic bones and lower extremities. No complications on the background of resuscitative endovascular balloon occlusion of the aorta were revealed. Two years after surgery both men continue serving in the Armed Forces, with no significant functional impairments. Our third injured patient delivered in a condition of clinical death, despite restoration of the rhythm after inflation of the balloon unfortunately died.

Our case reports demonstrate high efficacy of resuscitative endovascular balloon occlusion of the aorta in unstable haemodynamics induced by combat injury to the abdomen and pelvis. The technique of this method makes it possible not only to stabilize haemodynamics, to improve perfusion of the vital organs but also to staunch continuing haemorrhage, hence allowing additional time to carry out haemotransfusion. In future, resuscitative endovascular balloon occlusion of the aorta may become one of the methods of the extended protocol of prehospital care.

Key words: *resuscitative endovascular balloon occlusion of the aorta (REBOA), arterial catheterization, abdominal injury, pelvic injury, combat injury, aorta, bleeding, haemostasis, balloon catheter.*

INTRODUCTION

Combat casualty care has undergone colossal changes over the last decade. Specialists of various countries agree that we are currently witnessing a “military medical revolution” accompanied by an exceptionally unprecedented low level of lethality as compared with previous military conflicts [1–3]. This is related to the improved quality and rapidity of rendering first aid, modernization of the means of aeromedical evacuation of the wounded personnel, rendering improved en route care, implementation of the principles of shortened

interventions of damage control resuscitation in forward-positioned hospitals, as well as minimization of the operative wound and blood loss, frequently achieved by means of modern endovascular technologies [4, 5].

While stationary deployed hospitals equipped with a C-arm already have conditions to perform virtually the full spectrum of roentgenosurgical operations aimed at bleeding control or elimination of the lesion, in tent field medical units these possibilities are strictly limited. The use of resuscitative endovascular balloon occlusion of the aorta (REBOA) has been described

* V.A. Reva and I.M. Samokhvalov are co-authors of the patent for useful model № 172757 «Device for temporary occlusion of major vessels and aorta», with the patent holder thereof being the LLC “Minimally Invasive Technologies”.

for temporary bleeding control in conditions of advanced stages of evacuation. As late as during the Korean War (1950–1953), American military surgeon Carl Hughes used balloon catheters for occlusion of the aorta, but unsuccessfully [6]. Today, the REBOA technique is a commonly recognized procedure widely used in civil medicine to control ongoing intraperitoneal and intrapelvic haemorrhage, although reports concerning cases of its use in combat casualty care are still scarce [7–9].

We present herein a series of 3 clinical case reports regarding the use of REBOA in combat surgical wound, with the aim to demonstrate the possibilities of minimally invasive surgery even in austere environments with insufficient conditions for carrying out diagnosis and visualization.

INDICATIONS FOR AND TECHNIQUE OF REBOA

The technique of balloon occlusion of the aorta is used in unstable haemodynamics of the patient (systolic blood pressure lower than 90 mm Hg) and ongoing intraabdominal and/or intrapelvic bleeding [10–12]. The main goal is to temporarily maintain systemic haemodynamics at a level sufficient for adequate perfusion of the vital organs, along with arresting the continuing haemorrhage below the zone of balloon placement. Conventionally, REBOA techniques have been defined as continuous (CO) or non-continuous (NCO). A CO technique is described as using a balloon fully inflated from insertion for the entire duration of its use, and only deflated once it is no longer required clinically. This is in contrast to NCO REBOA techniques, which are a heterogeneous group of techniques, such as partial or intermittent inflation. Partial REBOA (pREBOA) is where the balloon volume is reduced to permit a level of flow-through, whereas intermittent occlusion (iREBOA) is where the balloon is deflated entirely at regular intervals [13]. The non-continuous REBOA techniques are accompanied by a lower risk for the development of severe reperfusion syndrome, but they are more technically demanding. The zones of REBOA occlusion are anatomically defined as follows: zone I extends from the ostium of the left subclavian artery to the celiac trunk (used for subphrenic bleeding control), zone II continues from the celiac trunk to the renal arteries (used rarely), and zone III is above the aortic bifurcation (for intrapelvic bleeding control). The time of complete occlusion in zone I is, as a rule, limited to 30–60 min., and in zone II – to 1.5 – 2 hours [14]. The choice of the zone of balloon inflation is usually made based on the main source of bleeding, determined by means of physical examination (examination of the abdomen, stress examination of the pelvic ring) and basic instrumental tests (radiography, ultrasonography). Performing REBOA envisages the following stages of the

operation: a vascular access, insertion and positioning of the balloon, inflation of the balloon, its slow deflation, removal of the balloon and introducer, elimination of the consequences of the vascular access (bandage with a pelot, if necessary, application of a fascial or lateral vascular suture) [10, 12]. The REBOA technique has comprehensively been described in the respective guidelines and articles [10, 14–17]. Regardless of the place and conditions of carrying out this operation, its stages remain the same. As a rule, REBOA is performed by surgical specialists – general and vascular surgeons, X-ray surgeons, however in different countries it may also be performed by emergency medicine physicians, as well as anaesthesiologists and resuscitators [11]. In the clinical cases described herein, all operations were performed by vascular surgeons with basic training in X-ray surgery.

Clinical case № 1

Wounded G., 29 years old, being in a dugout fell under artillery fire and was injured by shell splinters to the chest and extremities. At the stage of first medical aid he was haemodynamically stable and had his right leg immobilized. He was delivered simultaneously with several casualties by air transport to a medical detachment 4.5 hours after being injured.

The general condition was extremely severe, consciousness – profound stunning, with the skin of pale colour. Systolic blood pressure (BP) amounted to 50–60 mm Hg, with a heart rate of 110 b.p.m. Shallow breathing, diminished on both sides. In the chest area on the left there were two (as revealed later, tangential) wounds measuring 2.0x1.0 cm in the projection of V and X ribs along the mid axillary line. There was neither subcutaneous emphysema around the wounds nor bleeding therefrom. The abdomen was soft, nontender. In the middle third of the right crus there was a 5.0x4.0 cm gunshot injury with crepitation of fractured fragments, with no evidence of limb ischaemia. X-ray examination was unavailable at admission. Ultrasonography revealed a large amount of fluid in the abdominal cavity.

Intubation of the trachea was simultaneously accompanied by drainage of the left pleural cavity in the sixth intercostal space, with neither air nor blood obtained. «Blindly» performed was erroneous puncture of the right femoral vein, with a 10 Fr introducer sheath inserted therein for infusion-transfusion therapy. This was followed by puncture of the femoral artery and insertion of an 8 Fr introducer. Guided by the external reference points (the distance to the xiphoid process on Fig. 1), a Rescue Balloon (Tokai Medical, Japan) catheter was inserted into the thoracic aorta and inflated. Fig. 2 shows the external appearance of this

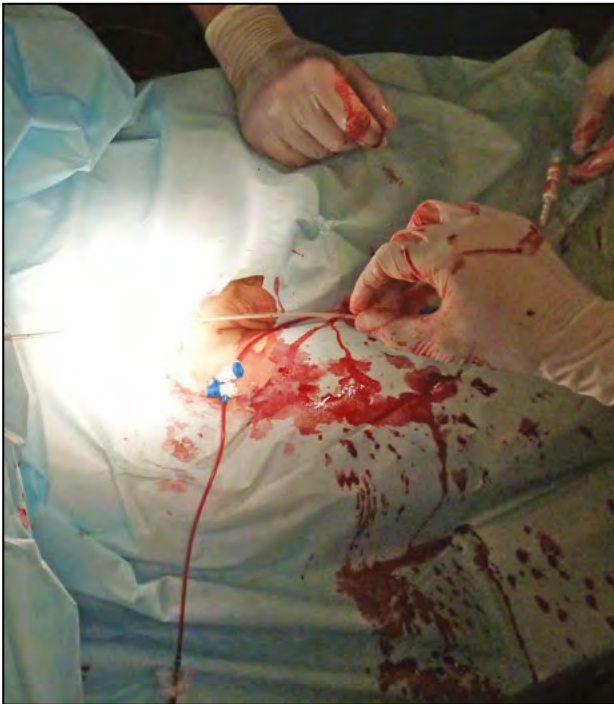

Fig. 1. REBOA in the first wounded. Measuring the depth of inserting the balloon catheter relying on the external landmarks. The lower edge of the balloon is positioned in the projection of the xiphoid process of the sternum

balloon catheter. BP increased to 120/60 mm Hg. Laparotomy was performed, revealing in the abdominal cavity up to 1500 ml of blood whose source was a grade III splenic lesion (according to the AAST classification) inflicted by crushed ribs IX and X. Blood in the amount of 1300 ml was taken for reinfusion, with splenectomy performed followed by slow (during 4–5 min.) deflation of the balloon. The total time of aortic occlusion amounted to 25 min. On the background of transfusion therapy (8 doses of red blood cell suspension, 300 ml of fresh-frozen plasma (FFP)) after deflation of the balloon, blood pressure did not drop below 90 mm Hg. The balloon catheter and introducer were removed using the fascia suture technique without closure of the arterial defect. We performed surgical debridement of the gunshot wound of the lower third of the crus, open reposition, and external fixation of the fracture of the right tibia.

The next day, the wounded patient was evacuated by air transport to a central hospital, to undergo secondary surgical debridement of the crural wound, reconstructive-restorative operations until wound healing and consolidation of crural bone fractures, which was the cause of a long hospital stay for 170 days. The abdominal and inguinal wounds healed with first intention. Two years after the injury, he continues serving in the Armed Forces of the Russian Federation, with no functional impairments.

Clinical case № 2

Wounded S., 25 years old, was injured resulting from a mine explosion under an armoured personnel carrier. Sitting on the armour, he was knocked over by a blast wave, however, held with his left leg inserted into a retaining strap at the level of the inguinal area. At the stage of first medical aid, BP was 120/70 mm Hg. After 3 hours he was delivered on a board to a medical detachment. The condition was terminal, consciousness – profound stunning, skin of pail colour. He had non-measurable BP, with a heart rate on the carotid artery of more than 120 b.p.m. Breathing was conducted to all portions, with a respiratory rate of 22–24 breaths per minute. Local swelling of the abdomen above the pubis (pelvic haematoma). Pressure on the pelvis was painful, accompanied by pathological motility (with a pelvic binder applied immediately at admission). In the upper third of the left femur there was a linear abrasion up to 10 cm wide. Both lower limbs were pail, cold to touch. Ultrasonography was suspicious for free liquid in the abdominal cavity. Tracheal intubation was simultaneously accompanied by «blindly» performed at the first attempt puncture of the right common femoral artery (CFA), with a 10 Fr introducer installed. Under X-ray guidance we performed endovascular occlusion of the thoracic aorta with the balloon catheter manufactured by the Limited Liability Company “Minimally Invasive Technologies” (town of Zheleznodorozhny, Russia). The external appearance of this balloon catheter is shown in Fig. 2, B. The correct position of the balloon was radiologically confirmed, as shown in Fig. 3. Systolic BP elevated to 130 mm Hg, immediately followed by laparotomy, revealing a huge retroperitoneal haematoma extending from the cavity of the small pelvis. A 10-cm-long separate linear access above the pubis was used to perform extraperitoneal tamponade of the pelvis, with the tampons left in situ, followed by deflation and removal of the balloon. The total time of occlusion of the aorta amounted to 16 min. Fractures of pelvic bones were fixed in the external fixation device from the kit for concomitant wounds, followed by removal of the introducer sheath using the fascia suture technique. BP during the operation remained at a level of not less than 100–110 mm Hg.

The patient intraoperatively received transfusion of 6 doses of red blood cell suspension and 4 doses of FFP. Upon completion of the operation (7 hours after the injury), a contracture was revealed in the left talocrural joint. Revision of the CFA in the area of abrasion (on the side opposite to the placement of the balloon catheter) revealed its subadventitial rupture and thrombosis in the zone of bifurcation.

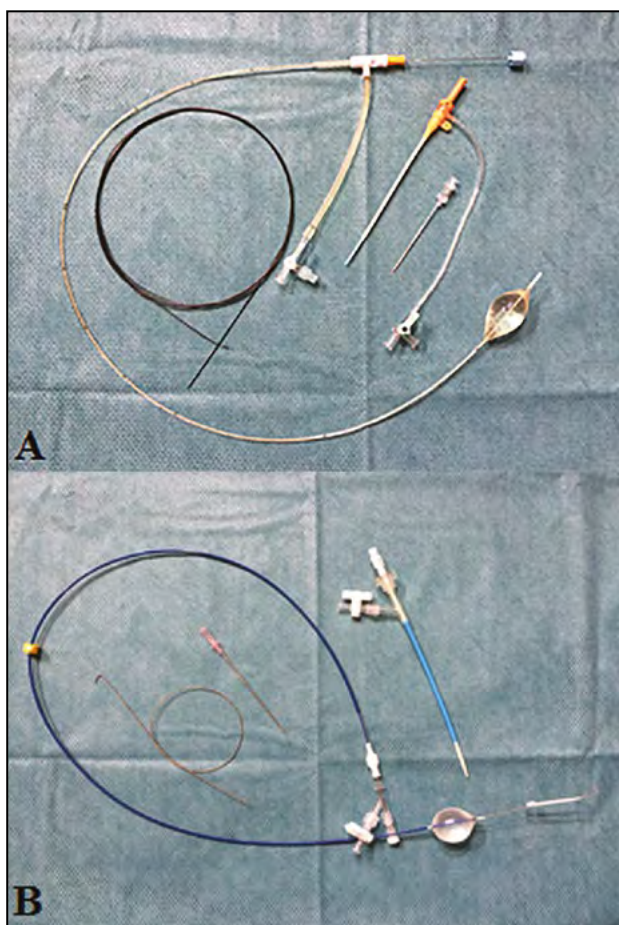


Fig. 2. External view of the catheters used: A – Rescue Balloon (Tokai Medical, Japan) compatible with a 7 Fr introducer sheath; B – catheter manufactured by the Limited Liability Company "Minimally Invasive Technologies" (city of Zheleznodorozhny, Russia) compatible with a 10 Fr introducer

A 5-cm-long linear temporal prosthesis from a polychlorovynil tube was inserted into the artery. Also performed was extended four-compartment fasciotomy at which all muscles were recognized as viable, with the wounds left open. Patency of the arterial bed was clarified by puncture angiography above the zone of the temporary prosthesis, confirming preservation of blood flow to the foot. The damaged portion of the CFA was reconstructed with an 8-cm-long reversed portion of the great saphenous vein of the femur harvested from the same incision.

On the next day, the patient was transported by air to a central hospital wherein a day after the tampons were removed from the small pelvis. Due to the development of reperfusion syndrome associated with restoration of blood flow in the ischaemized left lower limb, sessions of haemodialysis were initiated to continue for 30 days until complete restoration of the renal function. The wounds of the abdomen, pelvis, inguinal area, and crus healed with first

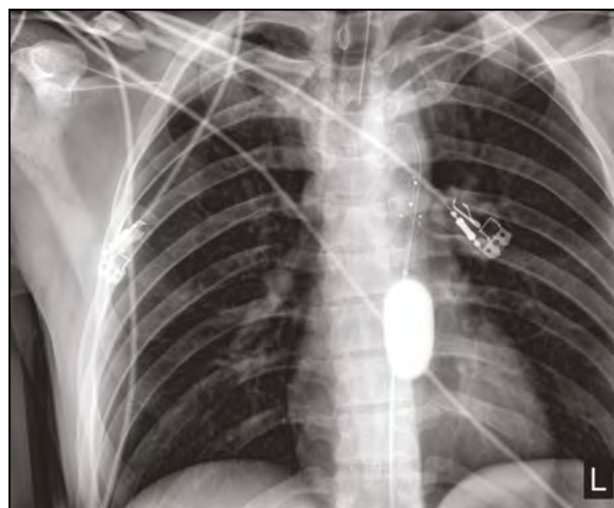


Fig. 3. REBOA in the second wounded patient. An X-ray image confirming the correct position of the balloon in the descending thoracic aorta. The balloon is filled with a mixture of a radiopaque medium and normal saline. The balloon used was manufactured by the Limited Liability Company "Minimally Invasive Technologies" with a built-in guidewire

intention. The patient was discharged in a satisfactory condition on day 75 after the injury. Two years thereafter his left leg performs the supporting function, with nearly complete restoration of active motions in the talocrural joint, however with lingering discomfort in the area of fractures of the pelvic bones. The patient still continues serving in the Armed Forces.

Clinical case № 3

Wounded L., 35 years old, sustained a severe concomitant injury of the head, chest, abdomen, pelvis and extremities after an armoured vehicle fell into a gorge (moreover, he was additionally pinned to the ground). At the place of the injury, he received anaesthesia, immobilization of fractures of bones of lower limbs with plywood splints, application of an improvised pelvic bandage, aseptic bandages onto the wounds. He was delivered to the nearest medical facility, with initiation of infusion therapy and transfusion of the RBC suspension (500 ml). The team of aeromedical evacuation (after 1 hour 40 minutes) assessed the victim as transportable, with catheterization of two central veins performed and in a helicopter two doses of the RBC suspension and 500 ml of FFP transfused. The pulse was determined only on the major arteries, with artificial pulmonary ventilation performed using a transport respirator.

Despite intensive therapy, he was delivered to a field hospital in a terminal condition 2 hours 20 minutes after the injury. At admission, cardiac arrest was diagnosed. The victim was immediately taken to an operating room. Resuscitative measures were in parallel with drainage of both pleural cavities

(with air obtained under pressure), and via an open access to the CFA a balloon catheter manufactured by the Limited Liability Company “Minimally Invasive Technologies” was inserted into zone I of the aorta, followed by renewal of cardiac activity, elevation of BP to 85/40 mm Hg at 20 minutes after admission. No blood was obtained by laparocentesis. A severe unstable pelvic injury was diagnosed: rupture of the right sacroiliac junction, fracture of the left pelvic, sciatic and iliac bones. The wounds of the lower limbs were tamponated using sterile gauze pads, with the limbs immobilized by splints.

After 40 minutes, the balloon was slowly deflated, BP was noted to decrease to 60/40 mm Hg, being non-measurable 10 minutes thereafter. Repeat inflation of the balloon in zone III of the aorta was performed, with relative stabilization of BP at 70/35 mm Hg. After 25 minutes, secondary asystole was noted to occur, resuscitative measures turned out ineffective, and biological death was certified. The total duration of the hospital stay amounted to 2 hours 15 minutes. The total volume of infusion-transfusion therapy amounted to 8000 ml, of which 1500 ml of FFP, 4 doses of blood, including prehospital haemotransfusion.

DISCUSSION

This article presents the first Russian experience with REBOA in combat environment at the stage of qualified surgical aid (role 2 combat casualty care), i. e., in the resource-restricted conditions and with the surgeons' efforts aimed only at performing operations on saving the wounded personnel's lives [18]. Two of the three severely wounded patients treated by REBOA survived with a good functional outcome and no REBOA-related complications. They currently continue serving in the Armed Forces. The third wounded delivered to a hospital 2.5 hours after the injury in a condition of clinical death, received REBOA as a “last resort” operation, but even in this instance, REBOA made it possible to temporarily stabilize haemodynamics (elevation of BP by 85 mm Hg), to carry out basic diagnostic and therapeutic measures.

The first experience in using this operation was published as long ago as in 1954 by C. Hughes who had installed balloons in two patients with severe gunshot wounds of the chest and abdomen, however they both had died soon [6]. The author noted a haemodynamically significant effect of such an intervention, but imperfection of the techniques did not allow wide implementation of this method. In the late 1980s and early 1990s after a short-term revival of the interest in the REBOA method by both foreign and Russian colleagues (dissertations of I.M. Samokhvalov, A.S. Zavrazhnov) the method was forgotten. Another wave of interest in REBOA arose in the late 2000s to continue up to now.

Used in ruptures of abdominal aortic aneurysms, gastroduodenal and postpartum haemorrhages, the REBOA method is becoming a means of rendering first medical and even premedical care. The U.S. Air Force Special Operations Surgical Teams, being completely autonomous, equipped with basic kits of tools, portable anaesthesiologic-respiratory and ultrasonographic devices, over 1.5 years of work in operating rooms, deployed in adapted premises near a battlefield zone performed a total of 20 REBOA procedures in patients presenting with injuries from explosion and gunshot wounds. All patients survived transport to the next level of care [8]. In 2018, along with transfusion of whole blood, REBOA was included into the protocols of the US Armed Forces for rendering “extended” prehospital care aimed at arresting haemorrhage, including intracavitary bleedings [19]. An indication for REBOA in accordance with these protocols is a decrease in systolic BP less than 90 mm Hg on the background of no or transient reaction to the carried out infusion-transfusion therapy, provided external haemorrhage is arrested, accompanied and followed by adequate monitoring of vital functions, and there is a possibility of transfusion of whole blood and/or its components, there is a lesion in the abdominal/pelvic cavity and there are no apparent lesions of the chest. It is for several years that REBOA has successfully been used by the London's Helicopter Emergency Medical Service [20]. Assessment of the possibility and feasibility of application of REBOA as early as during point-of-injury or en-route care was the purpose of numerous scientific studies showing promising results [21–23].

The main purpose of early application of REBOA is to temporarily arrest the ongoing internal bleeding for the period of performing the main stage of a cavitory operation. Besides, during the occlusion of the aorta, it is possible to induce anaesthesia, to perform catheterization of the central vein, shortened ultrasonographic examination, X-ray imaging (and sometimes also computed tomography) and to initiate transfusion therapy. Traditionally, cross-clamping of the aorta to arrest haemorrhage is performed during resuscitative thoracotomy which is time demanding, accompanied by additional trauma and intraoperative blood loss. In the three described herein cases, without REBOA it would have been required to perform thoracotomy or as in the first case subdiaphragmatic cross-clamping of the aorta for centralization of blood flow. Immediately available balloon catheters and trained specialists (vascular surgeons with an experience in 5–6 REBOA procedures each) allowed us to perform the intervention in a minimally invasive manner, even without X-ray control.

In the two successful cases we performed arterial puncture «blindly», however, despite extremely

low BP readings, we managed to avoid puncture-related complications. Removal of the 10 Fr and 8 Fr introducers was performed using the fascia suture technique described in detail in the available literature [24–26]. Advantages of this technique include simplicity, no need to expose the femoral artery (with application of only one U-shaped suture onto the artery-covering fascia), reliability and low cost (Fig. 4). The necessity of emergency strategic aeromedical evacuation of the patients for long distances made simple removal of the introducer sheaths followed by manual compression risky. A 3-cm-long inguinal skin incision required for the fascial suture became virtually invisible as soon as after several months (Fig. 5).

In the described case reports, the insertion and positioning of the balloon in the aorta were performed «blindly» relying on the external landmarks (with the lower edge of the balloon projected onto the xiphoid process). In one case (№ 2), it was possible to confirm the balloon's position with the help of an X-ray image. The literature has described variants of balloon placement with the help of ultrasonography when through the “hepatic window” it is possible to visualize the balloon travelling through the subdiaphragmal portion of the aorta, as well as with the help of contrast-enhanced ultrasonography [27].

An important aspect having contributed to wide implementation of REBOA into clinical practice was a decrease in the diameter of the devices used for occlusion. Until recently, the main balloon catheters used for REBOA were as follows: Cook Coda®, Medtronic Reliant®, and Boston Scientific Equalizer® which are intended for simulation of stent grafts and compatible with 12–14 Fr introducers. Currently, in the international market there exist 6–7 Fr low-profile balloon catheters (Tokai Rescue Balloon®, Japan, ER-REBOA®, Prytime Medical, USA, REBOA Medical, Norway), which, however, are not registered in Russia. The Russian-made balloon catheter manufactured by the Limited Liability Company “MIT” inflated to 40 mm and containing a built-in guidewire is compatible with a 10 Fr introducer, with a model measuring 6–7 Fr in diameter being under development.

The mean time of aortic occlusion in zone I for our cases amounted to 27 minutes, so there were no complications directly attributable to the technique itself. After inflation of the balloon it is extremely important to remember that with every minute «ischaemic debt» is accumulated and the surgeon has to resort to a maximally rapid method to control bleeding with immediate deflation of the balloon. The time of complete occlusion of the aorta in zone I should not exceed 30–60 min. [14, 19]. The interaction between the surgeon and anaesthesiologist appears to play the key role in the success of using this method, since

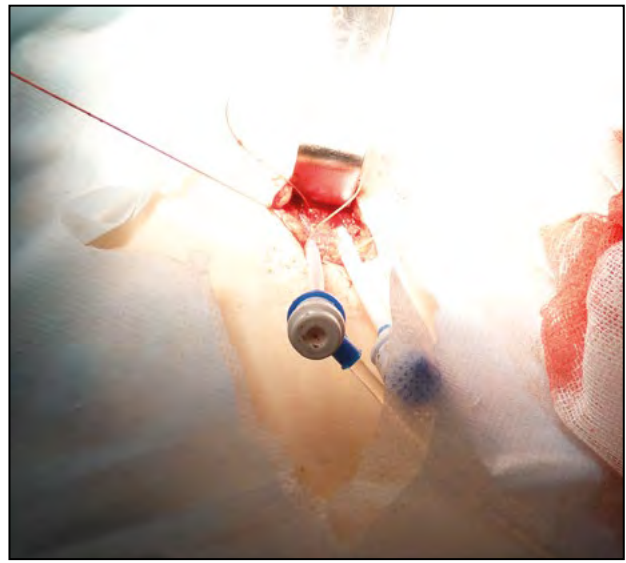


Fig. 4. Fascia suture technique during removal of the introducer, with one U-shaped suture applied to the fascia covering the femoral artery and definitive haemostasis once the introducer removed, not requiring manual compression

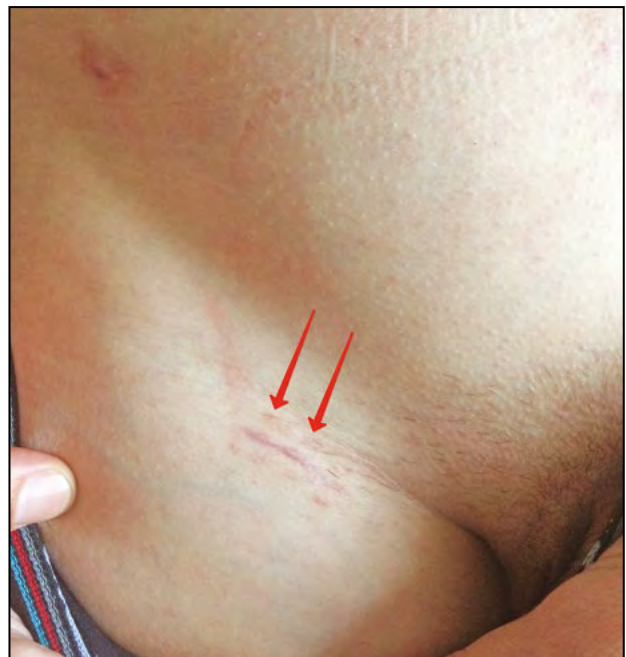

Fig. 5. External view of the intervention zone (after removal of the introducer using the fascial suture technique) at 2 months postoperatively, with the arrows showing a thin scar

at the moment of balloon deflation the patient has to be receiving adequate intensive therapy with transfusion of blood components, as a rule, in the scope of massive haemotransfusion (i. e., transfusion during 24 hours of not less than 10 doses of RBC suspension). In the first two successful cases, the wounded patients were given a large amount of blood components in a 2:1 ratio to the amount of the infusion media, whereas in the third victim this ratio was just the opposite, which undoubtedly told on the final outcome.

CONCLUSION

Combat casualty care currently requires using the full spectrum of minimally invasive technologies used in peacetime, with the REBOA procedure making it possible to rapidly, efficiently, and reliably achieve temporary haemostasis and stabilization of systemic haemodynamics for a period of time sufficient for performing a diagnostic search and the main stage of the operation, which finally stops bleeding. Elevation in systolic BP and temporary stabilization of haemodynamics on the background of aortic occlusion should obligatory be supported by adequately selected infusion-transfusion therapy with predominance of blood components, as a rule, in the variant of massive haemotransfusion. Rapidly performed operation and slow deflation of the balloon with complete removal of all devices make it possible to minimize the surgical systemic risks of the operation, associated with ischaemia of the kidneys and lower extremity involved, as well as to decrease the probability of local complications in the puncture site. Being an effective method of temporary haemostasis, REBOA may in the near future be regarded as an element of extended prehospital care, including that rendered by aeromobile evacuation teams and special operations surgical teams.

Conflict of interest: none declared.

Financial support: This work was funded by the grant of the President of the Russian Federation MK-5676.2018.7.

ЛИТЕРАТУРА/REFERENCES

1. **Blackbourne L.H., Baer D.G., Eastridge B.J., et al.** Military medical revolution: military trauma system. *J. Trauma Acute Care Surg.* 2012; 73(6 Suppl 5): 388–394. doi: 10.1097/TA.0b013e31827548df.
2. **Blackbourne L.H., Baer D.G., Eastridge B.J., et al.** Military medical revolution: prehospital combat casualty care. *J. Trauma Acute Care Surg.* 2012; 73(6 Suppl 5): 372–377. doi: 10.1097/TA.0b013e3182755662.
3. **Blackbourne L.H., Baer D.G., Eastridge B.J., et al.** Military medical revolution: deployed hospital and en route care. *J. Trauma Acute Care Surg.* 2012; 73(6 Suppl 5): 378–387. doi: 10.1097/TA.0b013e3182754900.
4. **Rasmussen T.E., Franklin C.J., Eliason J.L.** Resuscitative endovascular balloon occlusion of the aorta for hemorrhagic shock. *JAMA Surg.* 2017; 152: 11: 1072–1073. doi: 10.1001/jamasurg.2017.3428.
5. **Rasmussen T.E., Baer D.G., Doll B.A., Carvalho Jr.J.** In the “Golden Hour”. *Army AL&T Mag.* 2015; Jan-Mar: 80–85.
6. **Hughes C.W.** Use of an intra-aortic balloon catheter tamponade for controlling intra-abdominal hemorrhage in man. *Surgery.* 1954; 36: 1: 65–68.
7. **Manley J.D., Le A.T., Nam J.J.** A case report of simultaneous hypotensive patients managed with concurrent REBOA in a single-surgeon austere combat casualty environment. *J. Endovasc. Resusc. Trauma Manag.* 2018; 2: 2: 77–80. doi: 10.26676/jevtm.v2i2.47.
8. **Northern D.M., Manley J.D., Lyon R., et al.** Recent advances in austere combat surgery: use of aortic balloon occlusion as well as blood challenges by special operations medical forces in recent combat operations. *J. Trauma Acute Care Surg.* 2018; 85(1S Suppl. 2): 98–103. doi: 10.1097/TA.0000000000001966.
9. **Manley J.D., Mitchell B.J., DuBose J.J., Rasmussen T.E.** A modern case series of resuscitative endovascular balloon occlusion of the aorta (REBOA) in an out-of-hospital, combat casualty care setting. *J. Spec. Oper. Med.* 2017; 17: 1: 1–8.
10. **Stannard A., Eliason J.L., Rasmussen T.E.** Resuscitative endovascular balloon occlusion of the aorta (REBOA) as an adjunct for hemorrhagic shock. *J. Trauma.* 2011; 71: 6: 1869–1872. doi: 10.1097/TA.0b013e31823fe90c.
11. **Brenner M., Bulger E.M., Perina D.G., et al.** Joint statement from the American College of Surgeons Committee on Trauma (ACS COT) and the American College of Emergency Physicians (ACEP) regarding the clinical use of resuscitative endovascular balloon occlusion of the aorta (REBOA). *Trauma Surg. Acute Care Open.* 2018; 3: 1: 154. doi: 10.1136/tsaco-2017–000154.
12. **Reva V.A., Semenov E.A., Petrov A.N., Samokhvalov I.M.** Endovascular balloon occlusion of the aorta: use at in-hospital and prehospital stages of emergency medical care. *Emergency Medical Care.* 2016; 3: 30–38 (in Russian).
13. **Sadeghi M., Nilsson K.F., Larzon T., et al.** The use of aortic balloon occlusion in traumatic shock: first report from the ABO trauma registry. *Eur. J. Trauma Emerg. Surg.* 2018; 44: 4: 491–501. doi: 10.1007/s00068–017–0813–7.
14. **Morrison J.J., Reva V.A., Lönn L., et al.** Resuscitative endovascular balloon occlusion of the aorta (REBOA). In: *Top Stent: the art of endovascular hybrid trauma and bleeding management.* Örebro: Trio Tryck AB. 2017; 77–98.
15. **Rasmussen T.E., Tai N.R.M., Rich N.M., editors.** *Rich’s vascular trauma.* 3rd ed. Philadelphia, PA: Elsevier. 2016; 350.
16. **Biffi W.L., Fox C.J., Moore E.E.** The role of REBOA in the control of exsanguinating torso hemorrhage. *J. Trauma Acute Care Surg.* 2015; 78: 5: 1054–1058. doi: 10.1097/TA.0000000000000609.
17. **Moore L.J., Martin C.D., Harvin J.A., et al.** Resuscitative endovascular balloon occlusion of the aorta for control of noncompressible truncal hemorrhage in the abdomen and pelvis. *Am. J. Surg.* 2016; 212: 6: 1222–1230. doi: 10.1016/j.amjsurg.2016.09.027.
18. **Kotiv B.N., Samokhvalov I.M., Badalov V.I., et al.** Battlefield surgery in the beginning of the 21st century. *Military Medicine Journal.* 2016; 337: 5: 4–10 (in Russian).

19. **Butler F.K., Holcomb J.B., Shackelford S., et al.** Advanced resuscitative care in tactical combat casualty care: TCCC Guidelines Change 18–01:14. *J. Spec. Oper. Med.* 2018; 18: 4: 37–55.
20. **Sadek S., Lockey D.J., Lendrum R.A., et al.** Resuscitative endovascular balloon occlusion of the aorta (REBOA) in the pre-hospital setting: an additional resuscitation option for uncontrolled catastrophic haemorrhage. *Resuscitation.* 2016; 107: 135–138. doi: 10.1016/j.resuscitation.2016.06.029.
21. **Reva V.A., Hörer T.M., Makhnovskiy A.I., et al.** Field and en route resuscitative endovascular occlusion of the aorta: a feasible military reality? *J. Trauma Acute Care Surg.* 2017; 83 (1 Suppl 1): 170–176. doi: 10.1097/TA.0000000000001476.
22. **Ross E.M., Redman T.T.** Feasibility and proposed training pathway for austere application of resuscitative balloon occlusion of the aorta. *J. Spec. Oper. Med.* 2018; 18: 1: 37–43.
23. **Fisher A.D., Teeter W.A., Cordova C.B., et al.** The Role I resuscitation team and resuscitative endovascular balloon occlusion of the aorta. *J. Spec. Oper. Med.* 2017; 17: 2: 65–73.
24. **Larzon T., Geijer H., Gruber G., et al.** Fascia suturing of large access sites after endovascular treatment of aortic aneurysms and dissections. *J. Endovasc. Ther.* 2006; 13: 2: 152–157. doi: 10.1583/05–1719R.1.
25. **Harrison G.J., Thavarajan D., Brennan J.A., et al.** Fascial closure following percutaneous endovascular aneurysm repair. *Eur. J. Vasc. Endovasc. Surg.* 2011; 41: 3: 346–349. doi: 10.1016/j.ejvs.2010.11.020.
26. **Reva V.A., Hörer T.M., Samokhvalov I.M., Larzon T.** Femoral arterial closure after REBOA using the fascia suture technique: first experiences in a military setting. *J. Endovasc. Resusc. Trauma Manag.* 2018; 2: 2: 72–76.
27. **Chaudery M., Clark J., Morrison J.J., et al.** Can contrast-enhanced ultrasonography improve Zone III REBOA placement for prehospital care? *J. Trauma Acute Care Surg.* 2016; 80: 1: 89–94. doi: 10.1097/TA.0000000000000863.

Адрес для корреспонденции:
Рева В.А.
Тел.: +7 (921) 374-99-67
E-mail: vreva@mail.ru

Correspondence to:
Reva V.A.
Tel.: +7 (921) 374-99-67
E-mail: vreva@mail.ru