

Editor's Choice — Management of Descending Thoracic Aorta Diseases

Clinical Practice Guidelines of the European Society for Vascular Surgery (ESVS)

V. Rimbau^a, D. Böckler^a, J. Brunkwall^a, P. Cao^a, R. Chiesa^a, G. Coppi^a, M. Czerny^a, G. Fraedrich^a, S. Haulon^a, M.J. Jacobs^a, M.L. Lachat^a, F.L. Moll^a, C. Setacci^a, P.R. Taylor^a, M. Thompson^a, S. Trimarchi^a, H.J. Verhagen^a, E.L. Verhoeven^a, ESVS Guidelines Committee^b P. Kolh, G.J. de Borst, N. Chakfé, E.S. Debus, R.J. Hinchliffe, S. Kakkos, I. Koncar, J.S. Lindholt, M. Vega de Ceniga, F. Vermassen, F. Verzini, Document Reviewers^c P. Kolh, J.H. Black III, R. Busund, M. Björck, M. Dake, F. Dick, H. Eggebrecht, A. Evangelista, M. Grabenwöger, R. Milner, A.R. Naylor, J.-B. Ricco, H. Rousseau, J. Schmidli

Keywords: Clinical practice, Descending thoracic aorta, Descending thoracic aortic management, Guideline, Recommendations, Thoracic aorta abnormalities, Thoracic aorta diseases, Thoracic aorta disorders, Thoraco-abdominal aorta

TABLE OF CONTENTS

1.	Introduction	6
1.1.	Purpose	6
1.2.	Methodology	6
2.	General Aspects	7
2.1.	The normal descending thoracic aorta	7
2.2.	Epidemiology of descending thoracic aortic disease	8
2.3.	Diagnostic methods in descending thoracic aortic disease	9
2.3.1.	Medical history and physical examination	9
2.3.2.	Plain radiography	9
2.3.3.	Transthoracic echocardiography	9
2.3.4.	Transoesophageal echocardiography	9
2.3.5.	Computed tomographic angiography	9
2.3.6.	Magnetic resonance imaging	10
2.3.7.	Positron emission tomography	10
2.3.8.	Intra-vascular ultrasonography	10
2.4.	Neurological complications: prevention and management	10
2.4.1.	Spinal cord function monitoring	11
2.4.2.	Prevention of spinal cord ischaemia in open repair	11
2.4.3.	Prevention of spinal cord ischaemia in thoracic endovascular repair	12
2.4.4.	Prevention of stroke	13
3.	Specific Thoracic Aortic Disorders	13
3.1.	Acute thoracic aortic syndrome	13
3.1.1.	Acute type B aortic dissection	13
3.1.1.1.	Definition, risk factors, and clinical presentation	13
3.1.1.2.	Management	15
3.1.1.2.1.	Medical management	15
3.1.1.2.2.	Endovascular repair	15
3.1.1.2.3.	Open repair	16
3.1.2.	Intramural haematoma and penetrating aortic ulcer	17
3.1.2.1.	Definition and natural history	17
3.1.2.2.	Management	17

^a **Writing Committee:** Vincent Rimbau* (Chair) (Spain), Dittmar Böckler (Germany), Jan Brunkwall (Germany), Piergiorgio Cao (Italy), Roberto Chiesa (Italy), Gioachino Coppi (Italy), Martin Czerny (Germany), Gustav Fraedrich (Austria), Stephan Haulon (France), Michael J. Jacobs (Netherlands), Mario L. Lachat (Switzerland), Frans L. Moll (Netherlands), Carlo Setacci (Italy), Peter R. Taylor (United Kingdom), Matt Thompson (United Kingdom), Santi Trimarchi (Italy), Hence J. Verhagen (Netherlands) and Eric L. Verhoeven (Germany).

^b **ESVS Guidelines Committee:** Philippe Kolh (Chair) (Belgium), Gert Jan de Borst (Co-Chair) (Netherlands), Nabil Chakfé (France), Eike Sebastian Debus (Germany), Robert J. Hinchliffe (United Kingdom), Stavros Kakkos (Greece and United Kingdom), Igor Koncar (Serbia), Jes S. Lindholt (Denmark), Melina Vega de Ceniga (Spain), Frank Vermassen (Belgium), Fabio Verzini (Italy).

^c **Document Reviewers:** Philippe Kolh (Review Coordinator) (Belgium), James H. Black, III (United States), Rolf Busund (Norway), Martin Björck (Sweden), Michael Dake (United States), Florian Dick (Switzerland), Holger Eggebrecht (Germany), Arturo Evangelista (Spain), Martin Grabenwöger (Austria), Ross Milner (United States), A. Ross Naylor (United Kingdom), Jean-Baptiste Ricco (France), Hervé Rousseau (France), Jürg Schmidli (Switzerland).

* vriambau@clinic.cat

1078-5884/© 2016 European Society for Vascular Surgery. Published by Elsevier Ltd. All rights reserved.

<http://dx.doi.org/10.1016/j.ejvs.2016.06.005>

3.1.3.	Ruptured aneurysm of the descending thoracic aorta	18
3.1.3.1.	Definition	18
3.1.3.2.	Management	18
3.1.3.2.1.	Open repair	18
3.1.3.2.2.	Endovascular repair	18
3.1.4.	Blunt traumatic thoracic aortic injury	19
3.1.4.1.	Definition and diagnostic testing	19
3.1.4.2.	Management	20
3.1.4.2.1.	Open repair	21
3.1.4.2.2.	Endovascular repair	21
3.2.	Chronic type B aortic dissections	21
3.2.1.	Definition and natural history	21
3.2.2.	Management	22
3.2.2.1.	Indications for repair	22
3.2.2.2.	Open repair	23
3.2.2.3.	Endovascular repair	24
3.3.	Descending thoracic aortic aneurysms	25
3.3.1.	Definition and natural history	25
3.3.2.	Management	25
3.3.2.1.	Indications for repair	25
3.3.2.2.	Open repair	25
3.3.2.3.	Endovascular repair	26
3.4.	Thoraco-abdominal aortic aneurysms	28
3.4.1.	Definition	28
3.4.2.	Management	28
3.4.2.1.	Indications for repair	28
3.4.2.2.	Open repair	29
3.4.2.3.	Endovascular repair	29
3.5.	Inflammatory diseases of the descending thoracic aorta	30
3.5.1.	Takayasu arteritis	30
3.5.2.	Giant cell arteritis	31
3.5.3.	Behçet disease	32
3.5.4.	Other inflammatory aortitides	32
3.6.	Coarctation of the thoracic aorta in adults	33
3.6.1.	Definition and diagnosis	33
3.6.2.	Management	33
3.6.2.1.	Indications for repair	33
3.6.2.2.	Open repair	33
3.6.2.3.	Endovascular repair	33
3.7.	Miscellanea	34
3.7.1.	Genetic syndromes	34
3.7.1.1.	Marfan syndrome	34
3.7.1.2.	Loeys-Dietz syndrome	35
3.7.1.3.	Ehlers-Danlos syndrome	35
3.7.1.4.	Turner syndrome	36
3.7.1.5.	Familial thoracic aortic disease	36
3.7.2.	Aortic tumours	36
3.7.3.	Floating thrombus	38
4.	Surveillance	38
5.	Gaps in the Evidence	40
5.1.	General aspects	40
5.2.	Acute type B dissection	40
5.3.	Thoracic aortic rupture	42
5.4.	Blunt traumatic thoracic aortic injury	42
5.5.	Chronic type B dissection	42
5.6.	Descending thoracic aortic aneurysm	42
5.7.	Thoraco-abdominal aneurysm	42
5.8.	Inflammatory diseases	42
5.9.	Coarctation	42
5.10.	Miscellanea	43
5.11.	Surveillance	43
	Acknowledgements	43
	Appendix. Recommended additional references	43
	References	43

ABBREVIATIONS AND ACRONYMS

AAA	Abdominal Aortic Aneurysm	LDS	Loeys-Dietz Syndrome
AAS	Acute Aortic Syndromes	LHB	Left Heart Bypass
AAST	American Association for Surgery of Trauma	LSA	Left Subclavian Artery
AD	Aortic Dissection	MAP	Mean Arterial Pressure
ATBAD	Acute Type B Aortic Dissection	MEP	Motor Evoked Potentials
CA	Coeliac Artery	MFS	Marfan Syndrome
CAD	Coronary Artery Disease	MRA	Magnetic Resonance Angiography
CCA	Common Carotid Artery	MRI	Magnetic Resonance Imaging
COPD	Chronic Obstructive Pulmonary Disease	NSF	Nephrogenic Systemic Fibrosis
CSF	Cerebrospinal Fluid	OR	Open Repair
CT	Computed Tomography	PAU	Penetrating Aortic Ulcer
CTA	Computed Tomographic Angiography	PET	Positron Emission Tomography
CTBAD	Chronic Type B Aortic Dissection	PMR	Polymyalgia Rheumatica
DSA	Digital Subtraction Angiography	RCT	Randomized Clinical Trial
DTA	Descending Thoracic Aorta	SCI	Spinal Cord Ischaemia
DTAA	Descending Thoracic Aortic Aneurysm	SMA	Superior Mesenteric Artery
ECG	Electrocardiogram	SSEP	Somatosensory Evoked Potentials
EDS	Ehlers-Danlos Syndrome	TA	Takayasu Arteritis
EJVES	European Journal of Vascular and Endovascular Surgery	TAAA	Thoraco-Abdominal Aortic Aneurysm
ESR	Erythrocyte Sedimentation Rate	TAI	Thoracic Aortic Injury
ESVS	European Society for Vascular Surgery	TBAD	Type B Aortic Dissection
FL	False Lumen	TEVAR	Thoracic Endovascular Repair
GCA	Giant Cells Arteritis	TL	True Lumen
IMH	Intramural Haematoma	TOE	Transoesophageal Echocardiography
IRAD	International Registry of Aortic Dissection	TS	Turner Syndrome
IVUS	Intravascular Ultrasonography	TTE	Transthoracic Echocardiography
		WC	Writing Committee

1. INTRODUCTION

1.1. Purpose

The European Society for Vascular Surgery (ESVS) appointed the Descending Thoracic Aorta (DTA) Writing Committee (WC) to produce the current clinical practice guidelines document for surgeons and other physicians who are involved in the overall care of patients with DTA disorders. The goal of these guidelines is to summarize and evaluate all current available evidence to assist physicians in selecting the best management strategies for all DTA pathologies. However, each respective physician must make the ultimate decision regarding the particular care of an individual patient.

The present guidelines document aims to improve decision making and decrease variability in the vascular surgical care of patients presenting with pathology of the DTA. Unfortunately, robust evidence from prospective and randomized studies is not available for management of most DTA diseases. Consequently, the recommendations in these guidelines are entirely based on level B and C evidence. Nevertheless, when managing DTA pathology, it is clinically helpful to have access to the most recent and best available clinical and experimental knowledge to determine the current standard of care.

The DTA WC intentionally agreed to exclude pathology of the ascending aorta and aortic arch from the current

document to avoid potential inter-specialty conflict. The cost analysis of different treatments was also excluded because of differences in financial management and differing health systems across Europe. Primarily infectious or mycotic disease processes were also considered outside of the scope of this document because of their low incidence and poor outcomes.

All disorders originating in the DTA from the left subclavian artery (LSA) origin to the diaphragm were considered for these guidelines. Pathology involving the thoraco-abdominal segment of the aorta was also included.

1.2. Methodology

The DTA WC was formed by members of the ESVS from different European countries, various academic and private hospitals, and by both vascular surgeons and endovascular specialists, to maximize the applicability of the final guidelines document. The DTA Guidelines Committee met in November 2011 for the first time to discuss the purpose, contents, methods, and timeline of the following recommendations.

The DTA WC performed a systematic English literature search in the MEDLINE, EMBASE, and COCHRANE Library databases for each of the different topics that are discussed and reviewed. The latest literature search was performed in

Table 1. Levels of evidence.¹

Level of Evidence A	Data derived from multiple randomized clinical trials or meta-analyses
Level of Evidence B	Data derived from a single randomized clinical trial or large non-randomized studies
Level of Evidence C	Consensus of opinion of the experts and/or small studies, retrospective studies, or registries

December 2015. With regard to evidence gathered, the following eligibility criteria were applied:

- Only peer reviewed published literature was considered
- Published abstracts or congress proceedings were excluded
- Randomized clinical trials (RCT) as well as meta-analyses and systematic reviews were assessed with priority
- Non-randomized clinical trials and non-controlled studies were included
- Well conducted observational studies (cohort and case control studies) were included
- Previous guidelines, position papers, and published consensus documents were included as part of the review process when new evidence was absent
- We minimized the use of reports from a single medical device or from pharmaceutical companies in order to reduce the risk of bias across studies.

A grading system was adopted based on the European Society of Cardiology (ESC) guidelines methodology.¹ The level of evidence classification provides information about the study characteristics supporting the recommendation and expert consensus, according to the categories shown in [Table 1](#).

The recommendation grade indicates the strength of a recommendation. Definitions of the classes of recommendation are shown in [Table 2](#).

Table 2. Grades of strength of recommendations according to the ESC grading system.¹

Classes of recommendation	Definition
Class I	Evidence and/or general agreement that a given treatment or procedure is beneficial, useful, effective. <i>It should be performed</i>
Class II	Conflicting evidence and/or a divergence of opinion about the usefulness/efficacy of the given treatment or procedure
Class IIa	Weight of evidence/opinion is in favour of usefulness/efficacy. <i>It should be considered</i>
Class IIb	Usefulness/efficacy is less well established by evidence/opinion. <i>It may be considered</i>
Class III	Evidence or general agreement that the given treatment or procedure is not useful/effective, and in some cases may be harmful. <i>It is not recommended</i>

For each recommendation, two members of the WC assessed the strength of a recommendation and the quality of supporting evidence independently. A full master copy of the manuscript with all recommendations was electronically circulated and approved by all WC members. Recommendations that required consensus were discussed and voted on by email among all members of the WC.

This system permits strong recommendations, supported by low or very low quality evidence from downgraded RCTs or observational studies, only when a general consensus is achieved among the WC members and reviewers.

Two members of the WC prepared each part of the guidelines document. An internal review process was performed before the manuscript was sent to independent external reviewers. External reviewers made critical suggestions, comments, and corrections on all preliminary versions of this guideline. In addition, each member participated in the consensus process concerning conflicting recommendations. The final document was reviewed and approved by the ESVS Guidelines Committee and submitted to the *European Journal of Vascular and Endovascular Surgery (EJVES)*. Further updated guidelines documents on DTA management will be provided periodically by the ESVS when new evidence and/or new clinical practice arise in this field.

To optimize the implementation of the current document, the length of the guideline has been kept as short as possible to facilitate access to guideline information. Following this decision, the “References” list has been limited to the most relevant references related to these guidelines. Nevertheless, an [Appendix of recommended additional references](#), also reviewed by the WC, has been added for further information for readers. This clinical guidelines document was constructed as a guide, not a document of rules, allowing for flexibility with various patient presentations. The resulting clinical practice guidelines provide recommendations for the clinical care of patients with thoracic aortic diseases including pre-, peri-, and post-operative care.

Conflicts of interest of each WC member were collected prior to the writing process. These conflicts were assessed and accepted by each member of the WC and are reported on the ESVS website. In addition, the WC agreed that all intellectual work should be expressed without any interference beyond the honesty and professionalism of all members and assistants during the writing process.

2. GENERAL ASPECTS

2.1. The normal descending thoracic aorta

The DTA originates from the isthmus, the region of the thoracic aorta between the origin of the LSA and the ductus arteriosus. The descending thoracic aorta runs in a left para-spinal location until its distal segment, where it passes anteriorly through the diaphragmatic aortic hiatus and inferiorly into the abdomen. Important aortic side branches originating from the descending thoracic aorta

include the intercostal arteries, spinal arteries, and bronchial arteries. The normal diameter of the mid-descending aorta ranges from 24 to 29 mm in men and 24 to 26 mm in women, whereas the normal diameter at the level of the diaphragm is 24 to 27 mm in men and 23 to 24 mm in women. Aortic diameter is influenced by age and body mass index.^{2,3}

The aortic wall is composed of three layers: the intima, media, and adventitia. The intima, the innermost layer, consists of an endothelial monolayer and an internal elastic lamina. Because it is in direct contact with blood, the function of the intima is to prevent thrombosis and atherosclerosis. Its anti-thrombotic and anti-atherosclerotic function can be reduced by risk factors, such as smoking, hypertension, hyperlipidaemia, diabetes, and direct trauma, each making patients more prone to aortic disease.

The media consists of concentric layers of elastin, collagen, and smooth muscle cells. These components are responsible for aortic wall elasticity, which accommodates the changes in stroke volume during the cardiac cycle, converts pulsatile inflow into a smoother outflow (Windkessel function), and maintains the integrity of the aortic wall. Congenital or hereditary disorders (e.g. bicuspid aortic valve, Marfan syndrome [MFS], Ehlers-Danlos syndrome [EDS]), risk factors (hypertension, atherosclerosis, and trauma) all influence aortic wall function. These conditions can stiffen the aortic wall, decreasing its ability to accommodate the stroke volume, resulting in systemic hypertension, or weakening of the aortic wall, leading to dilatation or dissection.

The adventitia is the outermost layer of the aortic wall and is composed mainly of collagen fibres, external elastic lamina, and small vessels (the vasa vasorum), which provide the blood supply to the aortic wall and surrounding nerves.

2.2. Epidemiology of descending thoracic aortic disease

DTA diseases consist of a broad spectrum of degenerative, structural, acquired, genetic, and traumatic disorders. The true incidence of descending thoracic aortic pathology remains unclear. Epidemiological studies are sparse and it is likely that many DTA related deaths are attributed to other cardiovascular diseases, such as cardiac arrest, myocardial infarction, cerebrovascular accidents, or abdominal aneurysm rupture. Therefore, the overall incidence of DTA disease is likely to be underestimated.

The pathophysiology of thoracic aortic diseases is believed to be multifactorial, resulting both from genetic susceptibility and environmental exposure. Therefore, the incidence of the different thoracic aortic diseases can vary significantly among different population groups.

Acute aortic syndromes (AAS) consist of three interrelated diseases: aortic dissection, penetrating aortic ulcer (PAU), and intramural haematoma (IMH). Type B aortic dissection (TBAD) most commonly affects male patients and has an incidence between 2.9 and 4.0 per 100,000 person-years.⁴ The incidence of TBAD seems to be increasing. A

recent prospective analysis of 30,412 middle aged men and women from Malmö, Sweden with a 20 year follow up reported an incidence of acute aortic dissection of 15 per 100,000 patient years.⁵ This increase is probably caused by the increasing age of the population and improving diagnostic modalities. The exact incidence remains unknown, but PAU has been diagnosed with increasing frequency because of the widespread use of advanced cross sectional imaging techniques. In symptomatic patients suspected of AAS, the prevalence of PAU is 2.3–7.6% and the lesion is localised in the DTA in 90% of patients.⁶ IMH may be related to PAU, accounting for 5–20% of patients with AAS and more commonly involving the DTA (60%) than the ascending aorta.⁷

Trauma is the leading cause of death during the first four decades of life, accounting for more than 250,000 deaths every year in the European Union alone.⁸ Blunt aortic injury is the second leading cause of death in these patients, and although it occurs in less than 1% of all motor vehicle accidents, it accounts for 16% of all traumatic deaths.⁹

Concerning ruptured descending thoracic aortic aneurysm (DTAA), a Swedish population study reported an incidence of 5 per 100,000 person-years. The mean age of patients in this cohort was 70 years for men and 72 years for women.¹⁰

Aneurysmal dilatation of the DTA is a degenerative disease with an estimated incidence of 6–10.4 per 100,000 person-years. The incidence seems to be increasing with ageing of the general population and continually improving diagnostic modalities.¹¹

Aortitis is a relatively uncommon disorder with a broad spectrum of clinical features. The most common autoimmune disorders affecting the DTA are Takayasu's arteritis (TA), giant cell arteritis (GCA), and Behçet's disease. The best estimates of the incidence of TA suggest that two or three cases occur each year per million people.¹² There is a 9:1 female to male predominance. Although the disease has a worldwide distribution, it appears to occur more frequently in Asian women.

GCA is the most common type of vasculitis observed in patients older than 50 years. Predominantly observed in populations of Scandinavian descent, it has a reported prevalence that varies between 1 and 30 per 100,000 people.¹³ The male to female ratio is around 2.5 to 1 and is highly dependent on geographic and genetic parameters.¹⁴

Behçet's disease has been observed most commonly along the classic Silk Route, with a peak prevalence in Turkey of 80–370 per 100,000 people, compared with 1–3 per million people in the Western world. Presentation is typically in the third to fifth decade of life, and both genders are affected equally.¹⁵

Coarctation of the aorta is a congenital cardiovascular defect, most commonly occurring at the level of the isthmus and accounts for 5–8% of all congenital heart defects. The overall incidence ranges between 20 and 60 per 100,000 person-years, with a slight male predominance. Patients with Turner syndrome (TS) are more commonly affected.¹⁶

2.3. Diagnostic methods in descending thoracic aortic disease

2.3.1. Medical history and physical examination. A comprehensive medical and family history, assessment of symptoms, and careful physical examination including blood pressure measurement and electrocardiography (ECG), are required in all patients suspected of thoracic aortic disease. Patients should be examined for suspicious clinical signs such as aortic regurgitation, cardiac murmur, pericardial rub, signs of tamponade, and an expansile abdominal aorta. The diagnosis of thoracic aortic disease is based on imaging and the choice of imaging modality should be based on the patient's condition and the availability of different imaging modalities.¹⁷

2.3.2. Plain radiography. Postero-anterior and lateral chest radiographs can be used to diagnose calcification within atheromatous lesions, left pleural effusions, aortic enlargement, and anomalous aortic contours in asymptomatic or symptomatic patients. A left pleural effusion can indicate a frank rupture, an exudate from inflammation of the adventitia in AAS, or, less commonly, inflammatory aortic disease. The International Registry of Acute Aortic Dissection (IRAD) showed that 21% of patients with a type B aortic dissection presented with a normal chest X-ray, and a meta-analysis demonstrated a sensitivity for an abnormal chest X-ray of 90% for TBAD.¹⁸ Although chest X-rays might be used in very low risk patients to exclude thoracic aortic diseases, these potentially lethal diseases require a conclusive diagnosis with the use of multiplanar imaging techniques such as computed tomographic angiography (CTA).

in the diagnosis of DTA pathology remains limited. In cases of examination limitations or inconclusive diagnosis, the use of additional imaging modalities is recommended.¹⁹ There are currently no specific studies to validate the usefulness of TTE for diagnosis of DTA pathology.

2.3.4. Transoesophageal echocardiography. TOE can visualize the DTA from the LSA to the coeliac artery (CA). This diagnostic test is generally used as a second line imaging modality and is useful to differentiate between AD, IMH, and PAU. With a reported sensitivity of 98% and a specificity of 95%, TOE is an accurate diagnostic tool for aortic disease, providing functional information in both the pre- and intra-operative settings.¹⁹ The semi-invasive nature of TOE has rare procedure related risks, but it can cause patient discomfort, requires sedation, and is contraindicated in the presence of oesophageal pathologies. In the majority of cases, computed tomographic angiography (CTA) scanning is performed as the first imaging modality, providing all required information. TOE may be used in specific circumstances as a second line option.

2.3.5. Computed tomographic angiography. CTA offers a detailed visualisation of the entire aorta and its surrounding structures. It can distinguish different aortic pathologies and is quick and widely available. Over the last two decades, CTA has become more sophisticated and is more readily available, with an increase in the number of scanners, the use of retrospective and prospective ECG-gated techniques, and through advances in post-processing software. These advances have resulted in motion free images with better resolution, reduced scanning times, and better visualisation.²⁰

Recommendation 1	Class	Level of evidence	References
All patients with clinical suspicion of thoracic aortic disease and abnormal chest radiograph should undergo computed tomographic angiography for diagnosis confirmation.	I	C	17,18

2.3.3. Transthoracic echocardiography. The use of TTE to assess the DTA is limited by structures in the thorax that weaken or distort the ultrasound signal and compromise image quality. Via a suprasternal, subcostal, or parasternal view, small parts of the DTA can be visualized, while in the case of a pleural effusion, the back of the patient can be used for transthoracic imaging.¹⁹ The major advantage of TTE is that it is non-invasive and can be used to visualize the ascending aorta, aortic arch, and supra-aortic vessels. In addition, the abdominal aorta can be visualized to check for abdominal extension of aortic dissection (AD). During TTE, all planes should be used to assess the extent of aortic disease and to exclude additional aortic or cardiac involvement. Because of its non-invasive nature and wide availability, TTE is increasingly used in the emergency department of community hospitals to screen patients suspected of having one or other acute aortic syndrome, such as type A dissection. However, the value of TTE

Current CTA scanners have a sensitivity of up to 100% and a specificity of 98–99%, with slight variations between different DTA pathologies.²¹ Imaging should include a non-contrast study, followed by an early and late phase contrast study and should examine the part of the body between the thoracic inlet and the common femoral arteries. This range provides complete information with three dimensional reconstruction. In addition, dynamic images can further assist in surgical planning or endovascular interventions. Consequently, CTA has replaced digital subtraction aortography as the “gold standard” for aortic imaging. Important disadvantages of CTA include the use of nephrotoxic contrast agents and the exposure of patients to ionizing radiation. In patients at increased risk of contrast induced nephropathy, circulating volume expansion with either isotonic sodium chloride or sodium bicarbonate solutions is recommended.²²

Recommendation 2	Class	Level of evidence	References
Multidetector computed tomographic angiography from thoracic inlet to common femoral arteries should be considered as the first line diagnostic modality for descending thoracic aortic pathology	Ila	C	20,21
Recommendation 3			
For the diagnosis of descending thoracic aortic disease, transoesophageal echocardiography should be considered as a second line imaging modality when computed tomography is unavailable, contraindicated, or inconclusive	Ila	C	19
Recommendation 4			
For patients at increased risk of contrast induced nephropathy, volume expansion with either isotonic sodium chloride or sodium bicarbonate solutions should be considered before contrast administration	Ila	C	22

2.3.6. Magnetic resonance imaging. MRI has an excellent diagnostic capability that is comparable with CTA and TOE and can be used for both pre-operative planning and follow up.²³ A major advantage of MRI is that it offers multiplanar evaluation with good differentiation between different soft tissues. Moreover, MRI can provide additional dynamic imaging regarding entry tear flow or arterial vessel involvement.²³ Although contrast is not usually required, the use of gadolinium enhances the quality of MRI. MRI can be used to visualize the aortic wall in detail and is, therefore, more commonly used in patients with aortic wall pathologies such as IMH or aortitis. Furthermore, MRI does not require ionizing radiation and offers an alternative for patients with renal insufficiency in some circumstances.

Important disadvantages of MRI include its limited availability and longer scanning times, which makes it less suitable for critically ill or unstable patients. In addition, the ability of MRI to detect calcification is decreased (compared with CTA), and artefacts from respiration or metallic implants reduce image quality. Post-gadolinium nephrogenic systemic fibrosis (NSF) is a rare, but devastating, side-effect in patients with impaired renal function. Using alternative imaging modalities or using the lowest possible amount of gadolinium may prevent NSF.²⁴

2.3.7. Positron emission tomography. PET is a nuclear imaging modality that is based on the detection of increased metabolic activity in inflammatory cells, resulting in increased uptake of a gammagraphic tracer, most commonly fluorodeoxyglucose ([18F] FDG). PET can be used for the diagnosis of aortitis and in the assessment of the extent and activity of any inflammatory disease. The diagnostic value of FDG-PET differs among the various inflammatory aortic diseases with a reported sensitivity ranging between 83% and 100% and specificity between 77% and 100%.²⁵ Development of PET in combination with computed tomography (CT) scanners has made it possible to combine functional and anatomic imaging, thereby making it possible for PET findings to be correlated with adjacent anatomical features. Although the availability of PET and PET/CT is limited, this modality may be used for diagnosis and follow up of aortitis.²⁶ Increased patient

radiation exposure is a major disadvantage of PET/CT (when compared with PET or CT examinations alone), as the effective radiation dose is a combination of the dose from both scans.²⁷

2.3.8. Intra-vascular ultrasonography. IVUS permits 360° visualisation of the aortic wall. It can be very helpful in confirming intimal defects when CTA and digital subtraction angiography (DSA) are inconclusive in the diagnosis of aortic injuries. IVUS is an operator and experience-dependent invasive procedure, and a complete evaluation of the aorta using IVUS can be time consuming. In some centres, IVUS is routinely used as an adjuvant imaging technique during endovascular repair (see also Section 3.1.4.1). Table 3 compares different imaging diagnostic tests for DTA according to their features and performance.

2.4. Neurological complications: prevention and management

The most feared and devastating complications associated with management of DTA disease are spinal cord ischaemia (SCI), resulting in paraparesis or paraplegia, and cerebral embolism, resulting in stroke.²⁸ SCI can develop immediately after surgery or with a delayed presentation. Although SCI rates as high as 20% have been reported, the incidence probably ranges between 2% and 6%.²⁹ The incidence of paraplegia is related to the duration and degree of spinal ischaemia resulting from an abrupt cessation of blood flow to the spinal cord and from a reperfusion injury mediated by biochemical mediators.³⁰ The presence of stroke after DTA surgery seems to be similar to aortic arch repair and often has an embolic aetiology, with an incidence up to 8% in elective cases or higher in the emergency setting.³¹ Classic predictors for these complications are diverse and include increasing patient age, previous carotid artery disease, aortic cross-clamp time, the extent of the aortic resection, aortic rupture, concurrent aneurysm disease of ascending aorta and/or aortic arch, emergency surgery, the use and duration of hypothermic arrest, peri-operative hypotension, and pre-operative renal dysfunction.^{28,31}

Table 3. Comparison of different imaging modalities for DTA diagnosis.¹⁷

Characteristics	TTE	TOE	CTA	MRI	PET	IVUS
Non-invasiveness	+++	++	–	+	–	–
Ease of use	+++	++	+++	++	++	+
Availability	+++	++	+++	++	+	+
Portability/bedside use	+++	+++	–	–	–	+/–
Interventional guidance use	+	+++	–	–	–	+++
Safe for serial examinations	+++	++	++	+++	++	–
Wall contour assessment	+	+++	+++	++	++	++
Supra-aortic vessel status evaluation	++	+	+++	+++	++	++
Aortic valve status evaluation	+++	+++	–	–	–	–
Pericardial effusion detection	+++	+++	+++	+++	++	–
Inflammation/Infection detection	–	+	++	++	+++	+

Number of signs (+ or –) represents the estimated potential value.

TTE = transthoracic echocardiography; TOE = transoesophageal echocardiography; CTA = computed tomographic angiography; MRI = magnetic resonance imaging; PET = positron emission tomography; IVUS = intra-vascular ultrasonography.

Several methods for spinal cord and brain protection have been used to reduce the incidence of neurological complications. These methods are described in the following sections.

2.4.1. Spinal cord function monitoring. During thoracic aortic surgery, the function of the spinal cord can be directly monitored with use of somatosensory evoked potentials (SSEP) or motor evoked potentials (MEP).³⁰ SSEP monitoring records stimulation of the posterior tibial nerve by electrodes placed on the scalp, and this technique is sensitive for detecting spinal cord ischaemia. Clinical studies have shown that SSEP can be used both to identify dominant intercostal arteries and to determine if these vessels require re-implantation.³² However, SSEP does not record motor function because perfusion of the anterior corticospinal tract is not assessed. Therefore, SSEP can be associated with delayed detection of ischaemia, thereby reducing its specificity.³⁰ MEP, on the other hand, stimulates the corticospinal tract transcranially or via the spinal cord directly. This technique has demonstrated increased sensitivity in predicting SCI compared with SSEP.^{33,34} Major disadvantages of MEP are the influence of anaesthetic agents on the potential amplitude and the resistance of axonal conduction to ischaemia, which makes the response of MEP to ischaemia generally slow.³³ Institutional experience and availability of these techniques should determine their use.

important vessels is relevant for success.³⁵ Revascularisation of the artery of Adamkiewicz and the intercostal arteries of T11/T12 has been reported, although not widely implemented. Pre-operative angiography has been used to identify the most important vessels, but as angiography itself can induce SCI (resulting from embolisation), other modalities such as magnetic resonance angiography (MRA) and CTA have become more popular.³⁶

Cerebrospinal fluid (CSF) pressure increases with aortic cross-clamping, and will eventually exceed the venous pressure, compromising venous outflow, leading to spinal cord malperfusion and secondary SCI. Randomized controlled trials and meta-analyses have shown that CSF drainage has a role in the prevention of paraplegia and paraparesis, with a risk reduction up to 75% (OR 0.48, 95% CI 0.25–0.92), but additional studies are recommended.^{29,37}

During aortic cross-clamping, prophylactic CSF drainage aims to maintain CSF pressure at 10 mm Hg intra-operatively and for 48–72 hours after completion of the aneurysm repair. In fact, delayed and late onset of neurological deficit are also described and potentially worsened by haemodynamic instability.³⁵

Recent studies have shown that CSF drainage combined with intrathecal papaverine solution can be beneficial.³⁸ Potential complications related to CSF drainage occur in fewer than 5% of cases, and include meningitis, epidural haematoma, subdural haematoma, and CSF leakage syndrome.^{37–39}

Recommendation 5	Class	Level of evidence	References
During open thoracic or thoraco-abdominal aortic repair, peri-operative monitoring of motor and/or somatosensory evoked potentials may be considered to predict spinal cord ischaemia	IIb	C	30,33

2.4.2. Prevention of spinal cord ischaemia in open repair.

Surgical techniques have been developed over the years to prevent SCI. Techniques like the Crawford inlay, single clamp repair, sequential aortic clamping, and others have been introduced with varying results. As revascularisation of all of the intercostal arteries is not feasible, the identification of

The use of left heart bypass (LHB) prevents heart failure and maintains distal aortic perfusion and CSF pressures as close to baseline as possible, and thereby reduces the risk of post-operative paraplegia and paraparesis in patients undergoing repair of type I and type II thoraco-abdominal aortic aneurysm (TAAA)⁴⁰ (see also Section 3.4.). Extra-

corporeal circulation allows sequential aortic clamping, maintaining retrograde perfusion of all of the vital organs and the spinal cord. These techniques have been shown to be beneficial in patients with TAAA, reducing the incidence of SCI by perfusion of the distal aorta from 11.2% to 4.5%.⁴⁰ Another important advantage of circulatory bypass is that it permits the induction of systemic hypothermia for additional neurological protection. Distal perfusion is often combined with CSF drainage or hypothermia, and has proven beneficial in reducing the incidence of SCI.^{35,38,41}

prevention of ischaemia, which suggests that numerous agents may protect the spinal cord from transient ischaemia.⁴³

Other pharmacological agents such as glucocorticosteroids may be beneficial in the prevention of SCI, although high quality evidence is lacking.⁴⁴ Other options include intrathecal hypothermia, but this requires an open laminectomy or closed epidural infusion system. These techniques are not fully applicable in current clinical practice (see also Sections 3.1, 3.2, 3.3, and 3.4 for specific details).

Recommendation 6	Class	Level of evidence	References
Cerebrospinal fluid drainage has a role in the prevention of paraplegia and paraparesis and should be considered during extensive open repair of the descending thoracic aorta	IIa	B	29,37
Recommendation 7			
To prevent spinal cord ischaemia, left heart bypass, allowing distal perfusion, during open type I and II thoraco-abdominal aortic aneurysm repair should be considered	IIa	C	40
Recommendation 8			
During extensive open descending thoracic aorta repair, moderate hypothermia around 32 °C may be considered to prevent spinal cord ischaemia	IIb	C	41,42
Recommendation 9			
Systemic cooling to less than 32 °C in combination with cerebrospinal fluid drainage is not recommended during open descending thoracic aortic repair as it can increase the risk of subdural bleeding	III	B	39,42

Induced systemic hypothermia by cardiopulmonary bypass and intermittent cardiac arrest might be an effective method to reduce the risk of SCI.⁴¹ Moderate systemic hypothermia to temperatures of 32 °C improves outcome without significant risks for the patient.^{41,42} However, the systemic anticoagulation required in these patients increases the risk of bleeding, and, in such conditions, CSF drainage and intrathecal manoeuvres can be dangerous.^{39,41,42} During the post-operative period, the maintenance of mean arterial pressure (MAP) between 80 and 100 mm Hg has been suggested by high volume centers.³⁵

After a period of ischaemia caused by cross-clamping, reperfusion injury can occur. Biochemical mediators, especially iron-related free radicals, induce cellular damage. Free radical scavengers have been studied in the

2.4.3. Prevention of spinal cord ischaemia in thoracic endovascular repair. TEVAR has been associated with a reduced incidence of neurological complications compared with open DTAA repair, but the risk of paraplegia or paraparesis ranges from 2.5% up to 8% and remains a concern.^{44–46} Prior abdominal aorta aneurysm (AAA) repair, prolonged hypotension, severe atherosclerosis of the thoracic aorta, occlusion of the left subclavian artery and/or hypogastric arteries, and extensive coverage of the thoracic aorta by the endograft are all associated with an increased incidence of SCI.^{44–49} Therefore, spinal cord protection (including CSF drainage) should be considered in patients with previous AAA repair or in patients who require extensive aortic repairs, as the benefit of CSF drainage is greatest in patients at the highest risk for spinal cord injury.^{45–47}

Recommendation 10	Class	Level of evidence	References
Patients with planned extensive thoracic aorta coverage (>200 mm) or previous AAA repair have a high risk for spinal cord ischemia and prophylactic cerebrospinal fluid drainage should be considered in endovascular thoracic aorta repair.	IIa	C	45–47

2.4.4. Prevention of stroke. Intra-operative embolism is the main cause of stroke in patients undergoing surgical repair of the DTA, emphasizing the importance of precautions during the operative period.

Debris from aortic atheroma/thrombus can result in an embolic ischaemic stroke and the release of debris should be prevented during surgery. Reducing manipulation of the DTA to a strict minimum⁴⁰ and TOE mapping of the sites of cannulation are techniques that can minimize the risk of embolisation.¹⁹ When clamping is neither possible nor recommended, deep hypothermic circulatory arrest must be instituted.⁴² In patients with atrial fibrillation, the use of arteriovenous femoro-femoral bypass or deep hypothermic arrest and the avoidance of cannulation of the left atrium with possible manipulation of thrombus may be a useful alternative.^{40,42}

During endovascular repair, guidewires within the aortic arch have the potential to mobilize debris and guidewire manipulation should be reduced to the minimum. According to a recent retrospective, multicentre analysis of selective LSA revascularisation in the treatment of multiple DTA pathologies,⁴⁸ coverage of the LSA in patients treated with TEVAR was associated with a higher incidence of stroke and paraplegia. Therefore, LSA revascularisation should be considered in the elective setting.^{44–46,49,50} In the acute setting, revascularisation should be performed based on the patient's anatomy (left mammary to coronary bypass, or dominant cerebral blood supply from the left vertebral artery) during emergency repair of the DTA (see also Sections 3.1 and 3.3).

most common site for the proximal intimal tear in ATBAD is located just distal to the origin of the left subclavian artery. In 90% of cases, ATBAD has a secondary tear that allows blood to re-enter the TL at what is known as the re-entry site.^{51,52}

The Stanford and DeBakey classifications are most commonly used to describe ATBAD (Fig. 1). DeBakey classified AD, based on the origin of the intimal tear and the extent of the dissection. The Stanford classification is based on the involvement of the ascending aorta.⁵³ A type A dissection is defined by involvement of the ascending aorta and type B by the absence of ascending aortic involvement. There is no consensus about the classification of arch AD without involvement of the ascending aorta.⁵⁴ Type B dissections originate distal to the ostium of the left subclavian artery. This classification is comparable with a DeBakey type III (including type IIIb), in which the dissection extends into the abdominal aorta. ATBAD accounts for 30–40% of all dissections.^{52,54–56} AD is defined as “acute dissection” within 14 days of the onset of symptoms. Thereafter, it is defined as sub-acute between 2 weeks and 3 months and chronic after 3 months (see also Section 3.2).

Any condition that increases intimal shear stress or decreases arterial wall strength is considered to be a risk factor. Systemic hypertension is present in almost 80% of ATBAD patients.⁵¹ Increasing age and atherosclerosis are other important risk factors,⁵⁷ as are congenital bicuspid or uni-commissural aortic valves,⁵⁸ cocaine abuse,⁵⁹ pregnancy,⁶⁰ strenuous activities, and severe emotional stress.⁶¹

Recommendation 11	Class	Level of evidence	References
In elective thoracic endografting cases when it is planned to intentionally cover the left subclavian artery, in patients at risk of neurological complications, preventive left subclavian artery revascularisation should be considered	Ila	C	44

3. SPECIFIC THORACIC AORTIC DISORDERS

3.1. Acute thoracic aortic syndrome

AAS covers a heterogeneous group of patients with similar anatomic and clinical characteristics. This group includes AD, IMH, and PAU.⁵¹ Traumatic aortic transection and ruptured DTAA also may be included. The most common symptom is chest pain. Histopathologically, all of these entities involve disruption of the media of the aorta, with bleeding between the layers of the aorta or transmurally in the case of rupture. Each condition can progress to another one of the group and each pathology may coexist in the same patient.

3.1.1. Acute type B aortic dissection.

3.1.1.1. Definition, risk factors, and clinical presentation.

Acute type B aortic dissection (ATBAD) is the result of a tear in the intimal arterial layer, which allows blood to propagate within the medial layer. This creates a flap, which divides the aorta into a true lumen (TL), and a false lumen (FL). The

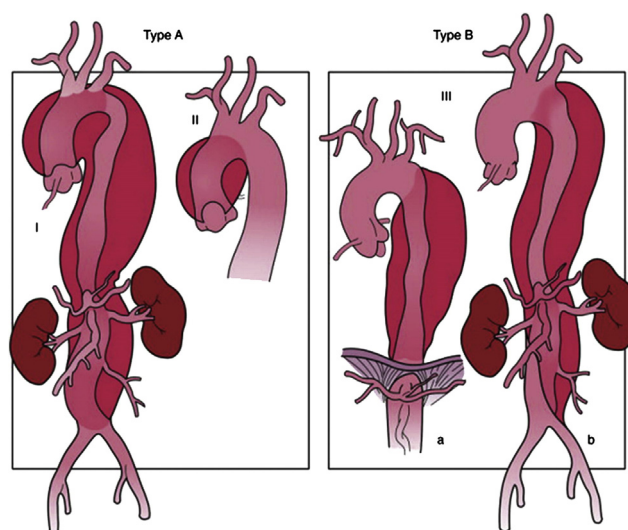


Figure 1. Schematic drawings of DeBakey (I, II, IIIa and IIIb) and Stanford (A and B) combined classifications for aortic dissection.

Table 4. Main clinical presentations of ATBAD.

Signs and symptoms	Incidence, %
Acute excruciating chest or interscapular pain	80
Chest pain	79
Back pain	64
Abdominal pain	43
Syncope	4
Pulse deficits	9
Hypotension/shock	4
Visceral ischaemia	7
Renal ischaemia	15
Limb ischaemia	9
Recurrent pain, refractory pain, or refractory hypertension	18
Spinal cord ischaemia	3

Another important risk factor is a positive family history of thoracic aortic diseases. ATBAD has a prevalence of 13–22% in patients who have a first degree relative with a history of DTAA or AD.⁶² The “familial thoracic aorta and dissection syndrome” is related to several identified gene mutations, including fibrillin-1 (FBN1), transforming growth factor- β 1 (TGFB1), transforming growth factor- β 2 (TGFB2), α -actin 2 (ACTA 2), and myosin heavy chain 11 (MYH11), increasing insight into the genetic pathology of the disease.^{63,64}

Structural weakness of the aortic wall is associated with multiple connective tissue disorders such as MFS, EDS, and Loey-Dietz syndrome (LDS) (see also Section 3.7). In patients younger than 40 years of age, who present with aortic dissection, about 50% will have MFS or a related genetic disorder. This group of patients, as well as those with a family history of thoracic aortic diseases, should receive genetic counselling.⁶² The aortic diameter is not closely related to ATBAD, although an increased risk of ATBAD has been observed in patients with a dilated DTA.⁶⁵ The mean diameter in ATBAD has been reported as 41 mm.⁶⁶ Indeed, many cases of ATBAD can occur in patients with normal diameter aortas.^{66,67}

The clinical presentation of patients presenting with ATBAD can be diverse and may mimic a wide range of other disorders. The classical presentation is acute onset excruciating chest or interscapular pain, which is present in about 80% of ATBAD patients.^{55,60} The main clinical signs and symptoms are reported in Table 4. The IRAD showed that hypotension (OR 23.8, 95% CI 10.31–54.94, $p < .0001$), absence of chest/back pain (OR 3.5, 95% CI 1.3–9.52, $p = 0.01$), and branch vessel involvement (OR 2.9, 95% CI 1.21–6.99, $p = 0.02$) are predictors of in hospital

mortality.⁶⁰ Although most patients present with these symptoms, some may have a non-specific presentation or even no symptoms, which can delay the diagnosis.^{68,69} For that reason, physicians must be familiar with an atypical presentation and a low threshold for diagnostic imaging should be maintained.

The most severe ATBAD complications include aortic rupture and occlusion of arterial branches, with consequent loss of arterial perfusion. Aortic rupture is associated with a high mortality, irrespective of the type of treatment,^{52,70–73} whereas patients with impending rupture who have no haemodynamic complications have better outcomes.^{56,70}

Renal and/or visceral ischaemia may be difficult to detect. Renal ischaemia can increase creatinine levels and potentially induce refractory hypertension. Treatment of renal ischaemia is important to prevent permanent renal insufficiency and refractory hypertension which is likely to result in a more rapid expansion of the affected aorta. Visceral ischaemia was the third most common cause of death (after aortic rupture and tamponade) in AD patients in the IRAD study,⁵⁵ and can result from malperfusion or systemic hypotension.^{55,56,60} Serum lactate levels are elevated when the ischaemic injury progresses or becomes irreversible; therefore early diagnosis is essential. ATBAD patients who present with or who develop recurrent abdominal pain should undergo repeat cross sectional imaging. In this situation, there should be a low threshold for undertaking laparoscopic inspection of the peritoneal cavity.⁷⁴ Gastrointestinal haemorrhage is a rare complication and every patient presenting with bleeding and abdominal pain should be suspected of having mesenteric ischaemia.⁷⁵

Acute limb ischaemia may present with paralysis of one or both lower limbs. Because of the dynamic nature of the dissection membrane, the presence of palpable peripheral pulses may be misleading.⁷⁶

Paraplegia/paraparesis represents a catastrophic, but rare, complication of ATBAD secondary to SCI. Other complications include refractory pain and refractory hypertension, which are both indirect signs of impending rupture and are associated with increased in hospital mortality.⁷⁷

Complicated ATBAD is defined as the presence of rapid aortic expansion, aortic rupture and/or hypotension/shock, visceral, renal, or limb ischaemia, paraplegia/paraparesis, peri-aortic haematoma, recurrent or refractory pain, and refractory hypertension despite adequate medical therapy.

In hospital survival in complicated ATBAD patients treated conservatively is about 50%.^{55,56,60,65,70–72,78} Hypotension/shock and visceral ischaemia are considered the most important predictors of in hospital death.^{56,60}

Recommendation 12	Class	Level of evidence	References
Patients with acute type B aortic dissection who develop new or recurrent abdominal pain and where there is any suspicion of visceral, renal and/or limb malperfusion should undergo repeat CT imaging	I	C	78

Complicated ATBAD patients with severe comorbidities (e.g. ischaemic heart disease, chronic pulmonary disease, or malignancy) may not benefit from invasive management and should be evaluated individually.^{65,70,78}

ATBAD may also present without complications in almost 50% of cases. This cohort is defined as uncomplicated ATBAD.^{55,78} Despite the absence of complications at the

Pain relief is also an important component of optimal medical therapy, as persisting pain may indicate progression of the dissection or impending rupture, requiring additional therapy.⁷⁷

During hospitalisation, all IV medications should be converted into oral agents, and long-term blood pressure regulation with adequate surveillance is mandatory.

Recommendation 13	Class	Level of evidence	References
Medical therapy should always be part of the treatment of patients with acute type B dissection	I	C	55,56,60,65,70,77–79
Recommendation 14			
In patients with acute type B aortic dissection, β -blockers should be considered as the first line of medical therapy	IIa	C	79,83,84
Recommendation 15			
In patients with acute type B aortic dissection who do not respond or are intolerant of β -blockers, calcium channel antagonists and/or renin-angiotensin inhibitors may be considered as alternatives or complementaries	IIb	C	79,83

time of presentation, these patients have an in hospital mortality of 3–10%.^{55,78} In the presence of complications (such as visceral, renal or limb ischaemia, and/or aortic rupture), mortality rises to 20% by day 2 and 25% by day 30. Like type A dissection, advanced age, rupture, shock, and malperfusion are important predictors of increased early mortality.^{60,79}

3.1.1.2. Management. The aims of treating ATBAD are to maintain or restore perfusion of the vital organs and to prevent both progression of the dissection and aortic rupture. Therefore, it is important to make a risk assessment at an early stage to determine the merits of medical, endovascular, or surgical intervention.

3.1.1.2.1. Medical management. Medical therapy with antihypertensive agents is widely accepted to be the first line treatment in uncomplicated ATBAD patients.^{52,54–56,60,65,70,77–79} Medical management is based on blood pressure reduction to limit aortic wall stress and to reduce the force of left ventricular ejection.⁷² The goal is to reduce systolic blood pressure between 100 and 120 mm Hg and, when attainable, the heart rate below 60 beats/min.⁵⁴ In ATBAD, initial medical therapy consists of β -blockers.^{55,79,80} In patients who do not respond to β -blockers or who do not tolerate the drug, calcium channel antagonists and/or renin-angiotensin inhibitors can be used as alternatives.^{80–83} β -blockers and calcium channel blockers have been associated with improved long-term survival in ATBAD patients.⁸³ Recent data have shown that angiotensin II type 1 receptor blockers have similar positive effects to atenolol in terms of growth reduction of the aortic root in children and young adults with MFS.^{81,82} Other alternative therapies include sodium nitroprusside, A1-adrenergic, and non-selective β blockers.⁸⁴

3.1.1.2.2. Endovascular repair. TEVAR has developed as the first line therapeutic option in patients with complicated ATBAD.^{85–95} The aim of endovascular repair for treating impending aortic rupture or malperfusion is to cover the primary entry tear and to reduce blood pressure within the FL.^{90,95} Reduction in FL perfusion can prevent extension of the dissection, which may lead to FL thrombosis, aortic remodelling, and aortic wall stabilisation.

Although there are no randomized controlled trials, there is increasing evidence that in complicated ATBAD, emergency and urgent interventions have been beneficial.^{55,60,77,86,87} In these settings, TEVAR has shown a substantial advantage over OR in terms of early mortality.^{87–89,92–94}

Currently, there are three meta-analyses available that report short- and mid-term results in complicated ATBAD patients treated with TEVAR. Technical success ranged from 95% to 99%, hospital mortality ranged from 2.6% to 9.8%, and neurological complications ranged from 0.6% to 3.1%.^{6,96,97}

A prospective, multicentre European clinical registry showed a 30 day mortality of 8%, a stroke rate of 8%, and a SCI rate of 2% in 50 ATBAD patients.⁹⁸ The initial results of a single arm multicentre study for endovascular repair of complicated AD, using a composite device design (PETTICOAT technique), which includes an uncovered infra-diaphragmatic aortic stent in addition to a standard TEVAR, showed a 1 year mortality of 10%. Stroke, transient ischaemic attack, or progression of dissection occurred in 7.5%, 2.5%, and 5% of patients, respectively.⁹⁹ Another study confirmed these findings with an in hospital mortality of 4%, 40%, and 33% in TEVAR, OR, and medically treated patients, respectively.⁸⁷ However, there is no evidence that extended coverage of the DTA is needed to restore distal perfusion.

Among complicated ATBAD patients, those presenting with visceral malperfusion experience the poorest

outcomes. Although visceral vessel patency following TEVAR is maintained in up to 97% of patients, the 30 day mortality is high (17–34%), as are aortic related complications during the chronic stage.^{67,89}

These patients seem to benefit from aortic balloon fenestration and branch stenting.^{100–102} A dynamic obstruction can be managed by increasing FL outflow with fenestration of the intimal flap, while a static obstruction or ostial disruption should be treated by stenting of the malperfused branch vessel.^{73,100–102}

TEVAR has also been advocated in the treatment of uncomplicated ATBAD, to prevent long-term aortic dilatation and rupture. IRAD reported reduced mortality at 5 years in ATBAD patients treated by TEVAR, compared with those managed medically.¹⁰³ ADSORB, the only randomized con-

use of proximal balloon dilatation, proximal bare metal stents, and with rigid non-compliant devices.¹⁰⁷ To facilitate the patient selection process, important anatomical and clinical features that characterize the aortic dissection pathology were recently summarized in a new categorisation scheme (DISSECT), which may be helpful in making the decision of whether or not to intervene.¹⁰⁸

Endovascular repair of ATBAD can be technically challenging and optimal results can be obtained in high volume centres with considerable endovascular experience and a multidisciplinary approach to the treatment of aortic diseases.^{6,100} Chronic post-TEVAR aortic dilatation may be observed in patients with persistent and patent FL.^{87,92,109} Therefore, life long clinical and imaging surveillance are advised in this situation⁶ (see also Section 4.).

Recommendation 16	Class	Level of evidence	References
In patients with complicated acute type B aortic dissection, endovascular repair with thoracic endografting should be the first line intervention	I	C	6,85–89,92–94,96–99, 103,109
Recommendation 17			
In complicated acute type B aortic dissection, endovascular fenestration should be considered to treat malperfusion	IIa	C	73,100–102
Recommendation 18			
To prevent aortic complications in uncomplicated acute type B aortic dissection, early thoracic endografting may be considered selectively	IIb	B	104

trol trial in patients with uncomplicated ATBAD, was not sufficiently powered for mortality at 1 year follow up. This trial did, however, show higher rates of FL thrombosis in patients randomized to TEVAR, and FL thrombosis is associated with fewer late complications and increased aortic remodelling following repair of ATBAD.¹⁰⁴

Although TEVAR results in this setting are favourable, endovascular related complications can be devastating and may require revision with OR.¹⁰⁵ Stroke is reported to occur in 3–10% of patients undergoing TEVAR because of manipulation of catheters in the arch and ascending aorta, and occurs more commonly in patients with severe arch atherosclerosis.⁴⁴ Although rare in ATBAD patients, SCI is related to the extent of aortic coverage, history of previous aortic surgery and the presence of hypotension at initial presentation.⁴⁷ Arm ischaemia, paraparesis, and paraplegia may occur from LSA or intercostal artery occlusion, which may require revascularisation.^{49,50} (see Section 2.4.4). Other complications (device or procedure related) can include aortic rupture during deployment, angulation, migration, or collapse of the stent graft, false aneurysm formation at the proximal or distal end of the stent graft, graft erosion, or stent frame fracture.¹⁰⁶ A retrograde type A dissection is associated with devastating outcomes. TEVAR for aortic dissection is particularly prone to retrograde type A aortic dissection. The risk of retrograde type A dissection seems to be increased with the

3.1.1.2.3. Open repair. The aim of OR in the treatment of ATBAD is to replace the DTA with a graft and excise the intimal tear, to restore peripheral perfusion and treat or prevent aortic rupture. Partial cardiopulmonary bypass has been widely used and hypothermic circulatory arrest has been adopted for cerebral protection in a subset of patients who were managed by OR approaches.^{110–112} There are no randomized controlled trials available to compare the different OR techniques and the level of evidence supporting various techniques is low. In patients presenting with complications such as imminent rupture, rapid expansion, or malperfusion syndromes, classic OR carries a significant risk of morbidity, including irreversible spinal injury and post-operative death.^{110–112} Surgical aortic fenestration or extra-anatomical bypass has been used for treating complicated ATBAD, but with the introduction of minimally invasive techniques, this procedure is only used as an alternative when endovascular repair fails or is contraindicated.¹¹³

Although the results of OR have improved over the last few decades,^{114–117} complications remain high, with in hospital mortality rates ranging from 25% to 50%.^{70,71,115,116} Pre-operative conditions heavily influence outcomes following surgical repair.⁷¹ Patients older than 70 years with hypotension or shock have less favourable outcomes, while those, normotensive at the time of surgery, have better outcomes.⁷¹

Complications affect 40–80% of patients undergoing open repair.¹¹⁵ Neurological complications such as paraplegia (2.3–6.6%), paraparesis (0–3.1%), and stroke (2.7–6.6%) are associated with the extent and duration of the operation.^{71,88,115,116} Benefits from extracorporeal circulation in the reduction of neurological complications and renal ischaemia remain controversial.^{88,114,115} Other complications include myocardial ischaemia or infarction, respiratory failure, visceral ischaemia, sepsis, multiorgan failure, and limb ischaemia.^{71,88,114–116}

thickening of the aortic wall, extending in a longitudinal, non-spiral fashion, is pathognomonic. The aortic lumen is preserved and the luminal wall is curvilinear and smooth, as opposed to a rough, irregular border seen with aortic atherosclerosis and PAU. IMH is generally a more localised process than classic AD, which typically propagates along the entire aorta to the iliac arteries.¹¹⁹

The natural history of type B IMH is similar to that of ATBAD.^{7,51} Conservative medical treatment is used for isolated uncomplicated type B IMH.¹²⁰ Treatment with β -

Recommendation 19	Class	Level of evidence	References
In acute complicated type B aortic dissection, open repair should be considered as an alternative to endovascular therapy following failure of endovascular management or where endovascular interventions are contraindicated	Ila	C	94,113

3.1.2. Intramural haematoma and penetrating aortic ulcer.

3.1.2.1. Definition and natural history. Intramural haematoma (IMH) is defined as the presence of blood within the aortic wall without intimal disruption or an identifiable entry point on imaging. IMH may be a precursor to both classic AD and penetrating aortic ulcer (PAU). It is distinguished from AD by the absence of an intimal flap and from PAU by the absence of any connection with the aortic lumen.¹¹⁷ Most cases of IMH (50–85%) are located in the DTA. At least 5–15% of patients admitted with IMH have an AD. The exact pathophysiology underlying IMH remains controversial. One theory suggests that IMH is a consequence of rupture of vasa vasorum in the medial layer of the aortic wall, which then causes a secondary tear into the aortic lumen. This process is typically associated with hypertension and is initiated by aortic wall infarction. Another theory suggests that IMH results following an intimal entry tear, allowing blood from the aortic lumen to enter the aortic wall. The blood then thromboses within the intimal layer so that no entry tears can be detected.^{117,118} Modern imaging suggests that IMH, PAU, and AD can develop from each other and, therefore, they are likely to be variants of the same pathological process. IMH evolves longitudinally between the medial layers and may progress, regress, or remain unchanged.¹¹⁷ IMH has identical clinical manifestations and treatment principles to those of AD. The classification of IMH follows that of the Stanford classification of AD. Type A IMH involves the ascending aorta. Type B IMH is localised in the aortic arch and in the DTA.¹¹⁸

Cross sectional imaging techniques (CTA, MRA) are used to differentiate between IMH, PAU, and AD. The characteristic finding of IMH on axial imaging is a thickening of the aortic wall greater than 5 mm in an eccentric or concentric pattern. Mural thrombus has an irregular luminal surface, narrows the lumen, and does not extend longitudinally as much as IMH. Discrimination between IMH and acute dissection with a thrombosed FL may be difficult. Unenhanced CT acquisition is crucial for the diagnosis of IMH. A high attenuation crescentic

blockers has a survival rate of 95%, compared with 67% for those treated without β -blockade.¹²⁰ IMH, if associated with PAU, has a significantly worse prognosis with a higher risk of expansion and rupture.⁵¹ Regression of acute IMH occurs in one third, progression in 20%, and up to 40% evolve into AD.⁷ Indications for treatment in type B IMH are refractory chest pain, evidence of increasing size of the expanding haematoma, aortic rupture, and a progressive pleural effusion.^{7,51,120}

Similarly, there is also considerable controversy regarding the aetiology of PAU.⁵¹ PAU may result from progressive erosion of atheromatous mural plaque with penetration of the elastic lamina. PAU may also develop in younger patients with intimal tears which remain localised and fail to progress to AD or IMH. PAU is more often present in the DTA and occurs more often in older patients with arterial hypertension, hyperlipoproteinaemia, and aortic sclerosis. Complicated PAU involves degeneration towards pseudoaneurysm formation, dissection, or rupture. Careful imaging is needed to evaluate both the diameter and depth of PAU.¹¹⁹ Although the specific growth rate is unknown, 20–30% of asymptomatic PAUs show evidence of progression over time.¹¹⁹

Symptomatic PAUs have an ominous natural history of progression and rupture. Urgent repair is commonly recommended in this setting.^{119,121} Currently, there is a lack of data concerning the natural history of patients with asymptomatic PAU. Progression with pseudoaneurysm formation may occur in 15–50% of cases. The association between aortic diameter and rupture risk remains unclear. However, patients with a PAU that initially measures >20 mm in diameter or >10 mm in depth have a high risk of disease progression and should be considered candidates for early endovascular repair.^{119,121}

3.1.2.2. Management. Patients presenting with uncomplicated type B IMH are primarily treated by medical therapy and intensive care monitoring, in line with the management of AD (see Section 3.1.1.2.1).¹²²

Endovascular repair is currently indicated in symptomatic or complicated patients or in those with evolution towards

AD because of a higher risk of peri-operative morbidity and the risk of rupture.¹²¹ Endovascular repair is associated with lower peri-operative morbidity and mortality than OR.^{123–125} Nevertheless, the role of endovascular repair in patients with type B IMH is debatable and identifying appropriate indications for treatment is critical. Although the literature provides no compelling guidelines for treatment, the WC recommends that treatment of IMH should follow similar guidelines as for the treatment of AD in the corresponding segment of the aorta, especially if it is associated with an evolving PAU, expansion of IMH, intimal tear disruption, or peri-aortic haematoma or progression to AD.¹¹⁹

Indications and the choice of treatment of PAU are similar to IMH. High mortality rates have been reported for OR¹¹⁹; therefore, endovascular repair is the preferred first line treatment.¹²³ According to the largest published series, specific aortic diameter, neck length and depth of PAU were not required for endovascular repair. Indications were pain and increase of the total aortic diameter at the level of the PAU.¹²¹ In the absence of RCT, the level of evidence for the treatment of PAU is low. There is currently no evidence based treatment recommendation available to support treatment of asymptomatic PAU beyond blood pressure control.

3.1.3.2. Management. Rupture of the DTAA is an acute condition resulting in a high mortality. Most patients die before receiving treatment or do not survive treatment. Survivors are at risk of multisystem organ failure and/or cerebral/spinal insult. Traditionally, DTAA rupture has been treated by OR but, in the last few decades, endovascular repair has emerged as an alternative option in selected patients. Symptomatic and ruptured DTAA should be treated urgently because of the risk of imminent exsanguination and death.

3.1.3.2.1. Open repair. Traditionally, ruptured DTAA has been managed by open repair. A recent meta-analysis of 224 patients with ruptured DTAA demonstrated a 30 day mortality of 33% for patients treated with OR.¹²⁶ Major complications of myocardial infarction, stroke, and paraplegia have been reported to occur in 11.1%, 10.2%, and 5.5%, respectively. Another recent multicenter, retrospective review of 69 patients with ruptured DTAA published by the same authors demonstrated a composite outcome of death, stroke, or permanent paraplegia in 36.2%.¹²⁷ These results were confirmed by a larger study, including data from the US Nationwide Inpatient Sample data on 559 patients with ruptured DTAA, with a reported mortality rate

Recommendation 20	Class	Level of evidence	References
Uncomplicated ^a type B intramural haematoma and penetrating aortic ulcer should be treated medically, and followed by serial imaging surveillance	I	C	121,122
Recommendation 21			
Endovascular repair should be considered for complicated ^a type B intramural haematoma	IIa	C	123–125
Recommendation 22			
Endovascular repair should be considered for complicated ^b type B penetrating aortic ulcer	IIa	C	119,121,123,124

^aUncomplicated/complicated IMH means absence or presence of recurrent pain, expansion of the IMH, peri-aortic haematoma, and intimal disruption.

^bComplicated PAU means presence of recurrent pain or PAU that initially measures >20 mm in diameter or >10 mm in depth or progression of total aortic diameter.

3.1.3. Ruptured aneurysm of the descending thoracic aorta.

3.1.3.1. Definition. Most thoracic aortic aneurysms are either located in the ascending aorta or the DTA, but either type can extend into the aortic arch. Rupture risk correlates with aneurysm diameter. Aortic rupture is defined as disruption of all the layers of the aortic wall (intima, media, and adventitia). In the acute phase, active extravasation of blood (as detected by contrast enhanced CTA, MRA, or echocardiography), is pathognomonic for rupture. Generally, DTAA rupture is contained by periaortic structures (pleura, pericardium) or intrathoracic organs (oesophagus, lungs, heart).

of 28.6%.¹²⁸ These data confirm that OR for ruptured DTAA is associated with high mortality and morbidity.

3.1.3.2.2. Endovascular repair. TEVAR has emerged as a less invasive therapeutic option for the management of ruptured DTAA. No prospective, randomized study has compared stent grafting versus OR in the treatment of ruptured DTAA. However, the results of meta-analyses and multicentre studies suggest lower mortality and complication rates following TEVAR.^{126–128}

In a recent meta-analysis comparing endovascular repair and OR for ruptured DTAA, the 30 day mortality was 19% and 33%, respectively.¹²⁶ Lower rates of myocardial infarction (3.5%), stroke (4.1%), and paraplegia (3.1%) were noted

for endovascular repair. The composite outcome of death, stroke, and myocardial infarction was 21.7% in the TEVAR group compared with 36.2% in the OR group (odds ratio 0.49, 95% CI 0.24–0.97, $p = .044$). By contrast, in the study using the US Nationwide Inpatient Sample data, TEVAR was not associated with a significantly lower mortality rate compared with OR (23.4% vs. 28.6%, respectively, $p > .1$).¹²⁸

The need for LSA revascularisation in challenging proximal aortic neck anatomy is controversial, especially in acute cases. LSA coverage, to achieve a satisfactory proximal seal during TEVAR for ruptured DTAA, is reported in up to 38% of cases. LSA revascularisation was not performed in most of these cases.^{127,128} Comprehensive data regarding the rationale for LSA coverage without revascularisation are unavailable. In one study, subclavian artery bypass was performed in half of the cases (10/19 covered) before TEVAR.¹²⁹ In cases in which the LSA is to be covered, prior revascularisation of the LSA in the emergency setting is recommended in patients with a left internal mammary artery to coronary artery bypass, or in those with a clearly dominant left vertebral artery. In all other emergency patients, LSA coverage without revascularisation can be performed^{49,129} (see also Section 2.4.4.).

In cases with challenging distal thoracic aortic anatomy, the CA can be selectively covered. Angiography of the superior mesenteric artery (SMA) after balloon occlusion of the CA can visualize adequate collateral circulation, however even with proven collateralisation, ischaemic complications can occur following CA coverage.¹³⁰ Endovascular parallel or “periscope” endograft techniques, can potentially be used to maintain perfusion through the coeliac artery.¹³¹ Physician modified fenestrated endografts have also been used to maintain perfusion to the CA. The development of off the shelf fenestrated grafts may provide new options to treat acute DTA pathology involving visceral branches (see also Section 3.3.2.3.).

The classic site of TAI is at the aortic isthmus in about 55–90% of patients admitted to hospital alive. Other regions of the thoracic aorta are less often affected.^{132,133} Trauma to the distal segment of the thoracic aorta can be associated with injury to the diaphragm and adjacent compression fractures of the thoracic spine.¹³²

After traumatic brain injury, TAI is the second most common cause of death in blunt trauma patients. The morbidity and mortality of this injury are high, causing sudden death in 80–90% of cases.¹³⁴ With improved rescue and rapid detection of TAI, patients who initially survive are more likely to undergo successful repair.

The damage incurred in TAI can be partial or circumferential. With more accurate diagnostic tools, the term “minimal aortic injury”, which implies the presence of a small intimal flap with minimal to no peri-aortic haematoma, has been introduced to describe a lesion that carries a low risk of rupture.¹³⁵ A classification scheme for TAI has been proposed: type I (intimal tear), type II (intramural haematoma), type III (pseudoaneurysm), and type IV (rupture).¹³⁶

About 2–8% of patients with an initially unrecognized TAI may develop a chronic post-traumatic pseudoaneurysm.¹³⁷ There are only a few reports on the natural history of this type of pseudoaneurysm. The largest series reporting 413 patients was published in 1982.¹³⁸ Up to 85% underwent surgical repair, and one third of the remaining patients died from their untreated lesions within 20 years of the initial trauma. Other authors report the development of late symptoms in about 50%, with aneurysmal expansion in about 20%, and death secondary to aortic rupture in 20% within 15 years of the injury.¹³⁹

Clinical presentation ranges from non-specific symptoms to thoracic or interscapular pain. Signs of chest wall injury, pseudo-coarctation syndrome, a systolic murmur, or paraplegia can be present. The risk assessment for TAI begins with a high index of suspicion based on the mechanism of injury. Abdominal injury, thoracic injury, hypotension, and

Recommendation 23	Class	Level of evidence	References
In patients with ruptured descending thoracic aortic aneurysm, endovascular repair should be the first treatment option when the anatomy is appropriate	I	B	127
Recommendation 24			
In emergency ruptured descending thoracic aortic aneurysm in patients with a patent left mammary to coronary bypass or with a dominant or single left vertebral artery, left subclavian artery revascularisation should be performed prior to left subclavian artery coverage	I	C	49

3.1.4. Blunt traumatic thoracic aortic injury.

3.1.4.1. Definition and diagnostic testing. Blunt traumatic thoracic aortic injury (TAI) most often occurs after sudden deceleration as a result of head on or side impact collisions, usually in high speed motor vehicle accidents or falls from great heights.

lack of restraint in motor vehicle accidents have been identified as clinical predictors of TAI. The greater the blunt trauma force the higher the index of suspicion for TAI should be.¹⁴⁰

Initial plain chest X-rays have a significant false negative rate in patients with TAI. Consequently, once aortic

transection is suspected, computed tomography evaluation is recommended.¹⁴¹ CTA has replaced angiography as the first line diagnostic test for TAI.¹⁴² CTA is quick and reproducible, with a near 100% sensitivity and specificity in identifying TAI. In addition, CTA is ideal for evaluating non-arterial trauma such as brain, spinal, pelvic, splenic, liver, and kidney damage in patients with multiple injuries. CTA findings, associated with TAI, include mediastinal haematoma, haemothorax, pseudoaneurysm formation, variation of aortic contour, and presence of intimal flap and thrombus. DSA now has a very limited role in TAI detection.¹⁴²

With the increasing use of TEVAR, IVUS has been advocated as having an important role in the evaluation of selected patients with suspected TAI.¹⁴³ Most of the patients who undergo TEVAR for TAI are young.^{144,145} These patients have a healthy and elastic aortic wall, with increased aortic pulsatile compliance. Aortic diameter varies in these patients by 10% (up to 18%) between systole and diastole.¹⁴⁵ In contrast to CTA, IVUS permits a dynamic real time evaluation of aortic diameters during the cardiac cycle. Furthermore, IVUS can easily detect the origin of side branches, allowing less use of contrast with DSA. Once the stent graft is deployed, IVUS can be used to evaluate adequate expansion of the stent, excluding infolding complications.

TOE has a limited role and low sensitivity in routine screening for TAI and should not be performed at the expense of prompt evaluation of other coexisting injuries. However, DSA and TOE might be used together when CTA is not available or is equivocal.¹⁴³ TOE can also be used intra-operatively to monitor myocardial function and fluid management. In addition, TOE has gained an important role in the delivery of stent grafts in TEVAR¹⁴³ (see also Section 2.3.4.).

3.1.4.2. Management. The appropriate timing of any operation in patients with TAI remains controversial. In 1997, the American Association for the Surgery of Trauma (AAST) published a multicentre study reporting that about 9% of patients reaching the hospital haemodynamically stable, progressed to free rupture. The majority of these ruptures occurred within 24 hours.¹⁴⁶ For this reason, immediate treatment of TAI was considered the standard of care for many years.

More recent studies^{147,148} have shown a reduction in paralysis and mortality with delayed treatment. In 2008, a prospective, observational, multicentre study by the AAST demonstrated similar complication rates, but a significantly higher mortality in patients who underwent early repair when compared with delayed repair. The study concluded that patients with TAI and associated major injuries are more likely to benefit from delayed intervention.¹⁴⁹

This conclusion is consistent with an extensive review of the literature¹⁵⁰ including 139 studies and 7,768 patients, which did not show a significant difference in mortality between early (within 24 hours) and delayed (after 24 hours) repair, suggesting that repair can be delayed if other extensive injuries require stabilisation. These conclusions are consistent with the guidelines of The Society of Vascular Surgery, which suggest urgent repair (within 24 hours) barring other serious concomitant non-aortic injuries, or repair immediately after other injuries have been treated but prior to hospital discharge.¹⁵¹

The type of aortic injury is also a determining factor in the timing of intervention. Patients with a 15 mm or larger arch haematoma were significantly more likely to die from TAI than those with a smaller haematoma. By contrast, minimal aortic injuries that present with an intimal tear and occur in 10% of patients with TAI may be managed expectantly with serial imaging for surveillance.^{135,151}

Recommendation 25	Class	Level of evidence	References
Computed tomographic angiography should be performed for the detection of traumatic aortic injury	I	C	142
Recommendation 26			
In traumatic thoracic aortic injury, transoesophageal echocardiography or intravascular ultrasonography should be considered for intra-operative sizing and for the deployment of stent grafts	Ila	C	142,143

Recommendation 27	Class	Level of evidence	References
Patients with free rupture of a blunt traumatic thoracic aortic injury or a large peri-aortic haematoma (≥15 mm) should undergo emergency repair	I	C	136,144,149
Recommendation 28			
In cases of blunt traumatic thoracic aortic injury without large haematoma, delayed intervention should be considered to prioritize treatment of associated life threatening injuries	Ila	C	144,149,150

3.1.4.2.1. Open repair. OR of a TAI at the classic isthmus location requires exposure of the aorta through a left fourth interspace thoracotomy with single right lung ventilation to improve surgical exposure. The aorta is clamped at the origin of the LSA and distal to the vessel injury. Until the mid-1980s, most of these procedures were completed with an expeditious clamp-and-sew technique. Although there are isolated reports of reasonable outcomes,¹⁵² meta-analyses of this technique have reported a mortality of 16–31% and a paraplegia rate of 5–19%.^{147,148,153}

Various methods of distal aortic perfusion have been used to protect the spinal cord. Early techniques used heparin-bonded intraluminal shunts (passive perfusion).¹⁵³ Meta-analyses and large-cohort studies of active versus passive perfusion showed a decrease in the rate of post-operative paraplegia from 19% to 3% and a mortality reduction from 30% to 12% in favour of active perfusion with partial cardiopulmonary bypass¹⁵⁴ (see also Section 2.4.2.).

Optimal peri-operative patient management with a skilled trauma team is mandatory to establish the correct timing and treatment priorities. Aggressive fluid administration that may exacerbate bleeding, coagulopathy, and rupture should be avoided. MAP should not exceed 80 mm Hg.¹³⁶ Hypotension (systolic blood pressure ≤ 90 mm Hg), and peri-aortic haematoma size (≥ 15 mm) were found to be independent risk factors for early mortality in patients with TAI.¹⁴⁴

In patients suffering severe brain injury with elevated intracranial pressure and haemorrhage or significant lung injury, delayed repair of TAI is preferable to avoid further brain or respiratory deterioration.¹³³

3.1.4.2.2. Endovascular repair. The first TEVAR procedure for a post-traumatic aortic pseudoaneurysm was performed in 1987 by Nicolai Volodos in Ukraine.¹⁵⁵ Since then, TEVAR has become the “first choice treatment” for TAI for many authors because of good early and late results.^{126,129,136,147,149,152,156–161} Data extracted from the Nationwide Inpatient Sample in 2006 showed a significant change from OR to TEVAR in the USA.¹⁶² A recent non-systematic review of the literature¹⁵⁹ identified 62 retrospective reviews or studies and six meta-analyses. A subgroup analysis of these papers showed that the TEVAR population was older, whereas patients in the OR group were more often unstable. Compared to OR, TEVAR showed a significantly reduced mortality (9.7% vs. 27.7%; $p < .001$) and a trend towards reduced paralysis (0.4% vs. 2.9%). OR of TAI was associated with a reduced stroke rate (0.4% vs. 2.3%). Combining these neurological complications (paralysis and

an associated mortality of 12.9%. Similar advantages were found in a systematic review in terms of survival and a decreased incidence of paraplegia with TEVAR, when compared with OR. This review reported an early endoleak rate of 4.2% and a stent collapse rate of 1.2%. The latter complication was fatal in 30% of cases.¹⁶⁰

Most TAI occur in young patients, who are more likely to have acute curvature of the aortic arch. This anatomical variant may limit the optimal apposition of the stent graft to the inner aortic curvature, leading to “bird beaking” and an increased risk of endoleak and stent collapse.¹⁶³ The average diameter of the thoracic aorta, proximal and distal to the rupture site, is 19 mm in patients with trauma. Excessive oversizing ($>20\%$) has been associated with an increased risk of device collapse.¹⁶³ With respect to pre-operative CTA measurements, stent grafts should be oversized by about 10%. More aggressive oversizing may be applied in gravely hypotensive patients, but not exceeding 20%. Hypotension may lead to inadvertent undersizing of the stent graft with a consequent increased risk of migration, endoleak, and/or graft collapse once resuscitation is fully achieved.¹⁶⁴ Where possible, delayed TEVAR may allow complete resuscitation. In these cases, serial CTA imaging can provide more reliable data regarding the actual aortic measurements for stent graft sizing.¹⁶⁴

The necessity of LSA coverage during TEVAR for TAI was reported in 30% of cases in recent reviews.^{150,160} As in other pathological situations, in the emergency setting LSA revascularisation is recommended in patients with left internal mammary artery to coronary artery bypass, and when the presence of a dominant left vertebral artery assures a better posterior cerebral perfusion compared with the right^{49,129} (see also Sections 2.4.2. and 3.1.3.2.2.).

A separate consideration should be applied to chronic post-traumatic pseudoaneurysms, which have different anatomical characteristics from degenerative aneurysms, in that they are typically localised, calcified sacular lesions located just distal to the LSA, making them attractive targets for endovascular repair.¹⁶⁵

The indications for late surgical intervention after aortic injury are not the same as those for other types of DTAA (see also Section 3.3.).

Follow up strategies after TEVAR for TAI deserve a special mention. A combination of multi-view chest X-rays and MRA, rather than CTA, may be considered¹⁶⁶ (see also Section 4.).

Recommendation 29	Class	Level of evidence	References
In patients with traumatic thoracic aorta injury and suitable anatomy, endovascular repair should be performed as the first option	I	C	157,159,160

stroke), the complication rate was comparable between the two groups. Overall, the endoleak incidence was 5.2% (type I proximal in almost all cases). There was a 1% migration rate in this cohort and stent collapse occurred in 2.5% of cases with

3.2. Chronic type B aortic dissections

3.2.1. Definition and natural history. Historically, TBAD is defined as “chronic” when 14 days have elapsed from the acute event. This temporal classification is based on the fact

that 70% of deaths from aortic dissection occur within 2 weeks of onset.¹⁶⁷ The risk of death following dissection remains high during the first 3 months and, in recent years, it has been suggested that a separate category of dissection, termed sub-acute (between 2 weeks and 3 months of the initial dissection), should be included. Additionally, the potential for endograft-stimulated aortic remodelling within this time period is higher.⁹⁸

In general, chronic type B aortic dissection (CTBAD) also includes patients with a residual TBAD after repair of a type A dissection (De Bakey type I dissection).¹⁶⁸ Aortic related complications may occur in 20–50% of patients with CTBAD.¹⁶⁹ Overall, it is estimated that approximately 20–40% of patients with CTBAD develop enlargement of the FL that warrants treatment and approximately 25% of DTAA or TAAA are associated with AD.¹⁷⁰ Aside from aneurysmal degeneration, aortic related complications include recurrent dissection, retrograde dissection, and rupture of the FL. The expansion rate of the chronically dissected aorta is not well known but ranges between 1 and 7 mm per year.¹⁷¹ Hypertension, an aortic diameter of 40 mm or more in the acute phase, chronic obstructive pulmonary disease, and patency of the FL have been recognized as risk factors for late aneurysmal degeneration.¹⁶⁹ In addition, the presence of an entry tear larger than 10 mm in diameter or located in the arch or proximal DTA has been recognized as a predictor of late mortality and the consequent need for aortic repair.¹⁶⁸ Moreover, in patients treated for type A dissection with a patent distal FL, a large area of the FL (>70% of the total aortic area) is considered to be a predictor of aneurysmal degeneration.²⁰²

Long-term survival after uncomplicated type B dissections remains relatively poor. An analysis of the IRAD database has shown that late mortality is high in patients discharged from the hospital after ATBAD, approaching 25% within 3 years.⁸⁵ Most deaths in patients with CTBAD are related to comorbid conditions.⁹²

3.2.2. Management. Aggressive medical therapy and close surveillance of the aorta remains the cornerstone of management to reduce the risk of late mortality and aortic complications. In a non-randomized, observational study, improved survival was shown in patients treated with β -blockers in the chronic phase of AD. This study reported an 80% freedom from aortic events at a mean of 4.2 years in patients on β -blockers, in comparison with 47% freedom from aortic events in patients treated with other antihypertensive agents. The efficacy of other antihypertensive drugs has not been specifically demonstrated in patients with CTBAD, although these drugs have a role in maintaining appropriate blood pressure (systolic below 130 mm Hg and diastolic below 85 mm Hg).⁸⁰

Several studies have suggested that 40–70% of late deaths in patients with CTBAD are caused by comorbid diseases, mainly heart disease and stroke,¹⁷⁷ emphasizing that cardiovascular risk factors should be thoroughly assessed and treated in this group. Interestingly, cigarette smoking does not seem to affect aortic expansion and rupture rates,¹⁷⁸ although its detrimental role on cardiovascular risk is well established.

Recommendation 30	Class	Level of evidence	References
In patients with chronic aortic dissection, effective antihypertensive therapy should be given to reduce the risk of aortic related death	I	C	80,83
Recommendation 31			
In patients with chronic dissection, measures to reduce cardiovascular risk (such as treatment of hyperlipidaemia, anti-platelet therapy, management of hypertension, and smoking cessation) should be implemented to reduce the incidence of late cardiovascular death	I	C	177,179
Recommendation 32			
Long-term medical treatment with β -blockers should be given to patients with chronic uncomplicated aortic dissection as they reduce the progression of aortic dilatation, the incidence of subsequent hospital admission, and the need for late dissection related aortic procedures	I	C	80

Conversely, FL thrombosis has been associated with a slower growth rate.^{172,173} Interestingly, partial distal FL thrombosis has been shown to be an independent predictor of mortality after hospital discharge in patients with a CTBAD.¹⁷⁴ The responsible mechanism may be increased FL pressure resulting from a large entry tear without outflow.¹⁷⁵ In addition, an increased risk of rupture in aneurysms resulting from AD has been observed when compared with degenerative aneurysms,¹⁷⁶ although there is insufficient evidence to support treatment at a lower diameter.

3.2.2.1. Indications for repair. The main goal of aortic repair in patients with CTBAD is to avoid aneurysmal degeneration and rupture of the aorta. The presence of malperfusion also mandates repair. Clinical and radiological factors may indicate the need for treatment.

New onset symptoms of AAS, such as lumbar back pain not caused by other conditions, hypotension, a new peripheral pulse deficit or blood pressure differential, new focal neurological deficit, or signs of end-organ malperfusion in patients with chronic dissection, mandate immediate evaluation to exclude rupture or progression of the dissection.¹⁷¹

In asymptomatic patients, the maximum aneurysm diameter remains the most important indicator for treatment. A large aortic diameter is associated with increased rupture risk, and several authors have shown that an aortic diameter between 50 and 60 mm is associated with rupture in almost 20% of cases.^{92,97,167,179} It should be acknowledged that there is a paucity of literature describing the

of the intimal flap. This can lead to longer operation times with increased risk of bleeding, SCI, and renal failure.¹⁸³

Aneurysms caused by chronic dissection are generally more extensive than degenerative aneurysms and also develop in younger patients. Several extracorporeal circulation methods and adjunctive measures for end organ and

Recommendation 33	Class	Level of evidence	References
In patients with chronic aortic dissection and acute aortic symptoms, emergency repair should be considered if malperfusion, rupture, or progression of dissection is confirmed on imaging	IIa	C	171
Recommendation 34a			
In patients with chronic aortic dissection, a descending thoracic aortic diameter between 56 and 59 mm may be considered as an indication for treatment in patients at reasonable surgical risk	IIb	C	167,176
Recommendation 34b			
In patients with chronic aortic dissection, a descending thoracic aortic diameter greater than 60 mm should be considered as an indication for treatment in patients at reasonable surgical risk	IIa	C	97,167,176
Recommendation 35			
In patients with chronic aortic dissection and thoraco-abdominal extension, an aortic diameter greater than 60 mm should be considered as an indication for treatment in patients at reasonable surgical risk	IIa	C	167,176

aortic rupture risk in relation to aortic diameters in patients with CTBAD.

3.2.2.2. Open repair. Despite the lack of data regarding comparison between open and endovascular repair, OR remains the standard treatment in low surgical risk patients with CTBAD because of an improvement in surgical results over the last 20 years.^{41,54,180} It should be noted that although several authors specifically report low surgical risk as a prerequisite for OR, the definition of surgical risk in thoracic aortic surgery is difficult. The most commonly used cardiac surgery risk models (European System for Cardiac Operative Risk Evaluation - EuroSCORE, Department of Veterans Affairs Continuous Improvement in Cardiac Surgery Program - CICS) report contradictory results when applied to thoracic aortic surgery. In particular, a Japanese study showed that the logistic EuroSCORE was able to reliably predict in hospital mortality in 327 consecutive thoracic aortic procedures.¹⁸¹ Conversely, an American study reported that both the EuroSCORE and the CICS greatly overestimated operative mortality rates in a series of 100 patients treated in a tertiary centre¹⁸² (see also Section 3.4.2.2.).

The mainstays of surgical repair of chronic dissection are similar to those of thoracic aortic aneurysms or TAAA. Patients with chronic dissections typically require a more complex operative repair because of the presence

spinal cord protection have been described. Differing opinions exist regarding the use of these adjunctive methods (see also Section 2.4.).

In early reports on OR treatment, chronic dissection was a risk factor for paraplegia with an incidence approaching 30–35%.¹⁸⁴ Indeed, these patients seem to have a different pre-operative risk profile compared with those with degenerative aneurysms, as they are more likely to present in an emergency/urgent fashion, have a connective tissue disorder, and be Crawford type I and II TAAA.¹⁸³ With the introduction of surgical adjuncts, the negative predictive value of chronic dissection on paraplegia has been reduced and, at present, is not considered a predictor of SCI in thoraco-abdominal aneurysm repair¹⁸⁵ (see also Sections 2.4. and 3.4.2.2.).

In numerous contemporary, single centre series of patients with complex aortic pathologies treated by OR, reported mortality rates range from 6% to 11%, with paraplegia/paraparesis being reported in 3.6–12%.^{41,180,183–185} In contrast to high volume centres, national registries and community based outcome analyses suggest that the mortality for the overall treatment of dissections by OR techniques is significantly higher and may exceed 20%.¹⁸⁶ These data reinforce the recommendation for centralisation of OR for chronic type B dissection, as well as for TAAA (see also Section 3.4.2.2.).

Recommendation 36	Class	Level of evidence	References
Open repair of aneurysmal or symptomatic chronic type B aortic dissection in patients with low surgical risk should be considered in dedicated centres with low complication rates	Ila	C	41,180
Recommendation 37			
In patients with chronic type B dissection undergoing operative repair, intra-procedural cerebrospinal fluid drainage, left heart bypass, and moderate hypothermia should be considered to reduce procedural mortality and spinal cord injury.	Ila	C	41,183

3.2.2.3. Endovascular repair. Since 1999, endovascular repair has been used increasingly in the treatment of CTBAD.⁹⁰ The goal of endovascular repair is to seal the proximal entry tear, facilitate aortic remodelling to achieve thrombosis of the FL, and thereby reduce the likelihood of aortic rupture in the mid- to long-term. The technique of endovascular repair involves placement of a stent graft over the primary entry tear in the DTA, usually via a trans-femoral route.

There are limited data comparing endovascular with OR for CTBAD. A published series of 24 patients undergoing repair of chronic dissection, showed mortality in the endovascular group of 0% compared with 33% in the open group.⁹⁰ National registry data support an improved long-term outcome in patients undergoing endovascular repair of AD in comparison with OR.¹⁸⁶ More recently, larger series have supported the concept that endovascular repair of CTBAD is associated with lower morbidity. A recent systematic review of TEVAR for chronic AD detailed 567 cases. In this review, the early (30 day or in hospital) mortality was 3.2%, the incidence of stroke 0.82%, and SCI occurred in 0.43%.¹⁸⁷

Endovascular repair of chronic dissection appears to be associated with lower mortality and morbidity rates than for AD, a difference attributable to the high incidence of emergency procedures in the acute setting. There is now a reasonably robust body of evidence to support the assertion that endovascular repair of chronic dissections may be achieved with mortality rates below 5% and a low incidence of neurological complications, even in complicated cases.^{88,188}

In the previously mentioned systematic review, the median length of follow up was 26 months. The all cause mortality rate was 9.2%. The mid-term aortic related mortality from those studies was 4.2%. The most common delayed complication was the development of aneurysms of the distal aorta or continuation of FL perfusion with aneurysmal dilatation (7.8%). Delayed aortic rupture was reported in 3.0%. No studies reported whether rupture occurred within or distal to the stented segment, or following persistent FL perfusion. Rates of complete FL thrombosis ranged from 38% to 100% (median 86%) in studies with a median follow up of 17 months. Studies reporting mid-term follow up of aortic morphology observed a reduction of the FL diameter in 79% of patients, FL expansion occurred in 15%, and TL expansion in 66%. Data from this review should be interpreted carefully because of the poor quality of the studies included.¹⁸⁷

The advent of thoracic endografting has opened up a potential therapeutic avenue for patients with uncomplicated sub-acute type B thoracic dissection. Without interventional therapy, a substantial proportion of these patients will go on to develop a large aneurysmal chronic dissection that may require therapy.¹⁶⁹ Treatment of chronic dissections is difficult and from an endovascular perspective, requires extensive thoracic coverage because of poor aortic plasticity. It has been hypothesized that a subset of patients with sub-acute dissection (between 2 and 12 weeks after the index process), could be identified on the basis of morphological and physiological characteristics that predispose to formation of aneurysmal chronic dissection. These patients might then be preferentially treated in the sub-acute phase.

Patients with sub-acute TBAD have a low endovascular repair mortality rate and a significantly greater aortic plasticity than patients with chronic dissections. Although attractive as a hypothesis, the morphological features that predict late expansion are not fully defined¹⁸⁹ and further research is needed in this field.

The INSTEAD trial randomized patients with sub-acute and chronic dissections to early endovascular repair or best medical management and surveillance. Although aortic remodelling was greater in the endovascular group, there were no statistically significant differences between the groups regarding 2 year mortality. Later follow up results have been published recently.¹⁹⁰ It has been demonstrated that TEVAR, in addition to optimal medical treatment, was associated with improved 5 year aorta specific survival and delayed disease progression. The authors concluded that in cases of stable CTBAD with suitable anatomy, preemptive TEVAR should be considered to improve late outcomes. A proportion of patients with sub-acute dissection may, therefore, benefit from early endovascular repair,¹⁹⁰ especially in those at risk of further aortic complications.^{168,169,172–174,189}

One issue that requires clarification is whether endovascular repair is effective in reducing aortic related death in the mid- to long-term. OR series demonstrate a high early aortic related mortality, but effective prevention of aortic related death in the long term.¹⁸⁰ Data regarding prevention of aortic related death are less robust for endovascular techniques. A series of 76 patients reported 12 late deaths. Only one was defined as aortic related (rupture of an untreated ascending dissection).¹⁹¹

The ability of the aorta to remodel after endovascular repair of acute and chronic dissections has been studied. Following coverage of the primary entry tear in ATBAD, there is rapid aortic remodelling with an increase in diameter of the TL and a reduction in FL diameter.^{91,192} By contrast, in chronic dissections, there is less aortic remodelling and the integrity of the endovascular repair is determined by the ability of the endovascular procedure to induce FL thrombosis. In treating chronic dissections, it has been shown that FL thrombosis occurs more often in patients with limited dissection and that FL thrombosis occurs more effectively in the stented part of the DTA.¹⁹¹

These findings suggest that the extent of coverage of the DTA is directly related to the extent of FL thrombosis. Although SCI rates after TEVAR for chronic dissection are lower than those after TEVAR for thoracic aneurysms, increased aortic coverage may increase the risk of SCI. To reduce SCI rates, spinal cord perfusion should be maintained whenever possible through collateral channels, especially from the LSA. Irrespective of the extent of aortic coverage, the dissected portion of the aorta below the diaphragm remains untreated, and there is evidence to suggest that this region may dilate over time.⁹¹ The role of bare stents in the treatment of chronic dissection, and the effect that these stents have on aortic remodeling, remain undefined at the present time.⁹⁹

The available literature regarding TEVAR for chronic dissection in patients with MFS is sparse.¹⁹³ Early technical feasibility has been demonstrated, but long-term outcomes remain uncertain. The fragility of the aorta in MFS and other associated conditions poses a problem for proximal aortic fixation and may lead to the development of complications (see also Section 3.7.1.1.).

Recently, new endovascular techniques have been tested to induce FL thrombosis in chronic CTBAD. Despite the feasibility and the early usefulness that have been demonstrated in selected patients in highly experienced centres, it is too early for widespread adoption and for a general recommendation statement.¹⁹⁴

segment of the aorta between the LSA origin and the diaphragm (see also Section 2.1. for normal values). Histopathologically, it is characterized by medial degeneration, with disruption and loss of elastic fibres and increased deposition of proteoglycans, with or without atherosclerosis.

At any given increased size of various aortic segments, the expansion rate is greatest in the DTA. There are many other factors that affect the expansion rate apart from diameter and anatomical location including smoking, intraluminal thrombus, chronic obstructive pulmonary disease (COPD), and vascular disease.¹⁹⁵ Once diagnosed, the prognosis of large degenerative aneurysms (more than 60 mm in diameter) is poor if not treated, with a 3 year survival of approximately 20%.¹⁹⁶

3.3.2. Management. The rate of expansion is important in deciding the frequency of surveillance in DTAA. Risk factors for rupture include maximum aneurysm diameter, age, gender, active smoking status, diastolic hypertension, and aneurysm related pain.^{9,176,196,197}

3.3.2.1. Indications for repair. An initial diameter of 60 mm carries an annual risk of rupture of 10%. For DTAA, there is a threshold of 70 mm at which the risk of rupture suddenly escalates.¹²⁷ Intervention in aneurysms below 55 mm may not afford a survival benefit, although a randomized controlled trial is necessary to evaluate the possible benefit of repair in the small aneurysm group.⁹ This threshold can be reduced to 50–55 mm for women or in the setting of connective tissue disorders (see also Section 3.7.1.).^{54,88}

3.3.2.2. Open repair. Indications for OR of a DTAA are limited to fit patients (see also Section 3.3.2.3.) unsuitable for TEVAR such as those with:

- 1) Absence of adequate arterial access¹⁹⁷ or a contraindication to aortic/iliac conduit graft placement (presence of hostile abdomen, severe aorto-iliac disease). The use of an aortic/iliac sidearm graft is required in approximately 15% of cases.⁵⁴
- 2) Absence of proximal or distal landing zones.

Recommendation 38	Class	Level of evidence	References
In patients with moderate to high surgical risk or with contraindications to open repair, endovascular repair of complicated chronic type B aortic dissections should be considered in dedicated centres	IIa	C	187
Recommendation 39			
In patients at risk of further aortic complications with suitable anatomy for endografting, endovascular repair of uncomplicated chronic type B aortic dissections should be considered in the sub-acute phase, in dedicated centres	IIa	B	190

3.3. Descending thoracic aortic aneurysms

3.3.1. Definition and natural history. Descending thoracic aortic aneurysms (DTAA) are defined as any aortic dilatation with at least a 50% increase in diameter located in any

- 3) DTA associated with a connective tissue disorder such as MFS, or DTA in young, healthy patients without major contraindications for OR.^{54,88}
- 4) Prohibitively high risk of neurological deficit post-TEVAR caused by full extent DTAA in patients with previous

abdominal aortic surgery, reducing pelvic circulation and occlusion of the lumbar arteries.^{45,198–200}

- 5) Symptoms related to compression by a large DTAA of adjacent structures such as the thoracic vertebral bodies (chronic pain syndrome), trachea or left mainstem bronchus (dyspnea), or oesophagus (dysphagia).²⁰¹

The extension and the location of the disease affect the surgical decision making process in terms of type of incision and use of peri-operative adjunctive measures. A classification has been proposed to define the risk of SCI during DTAA repair. Such a classification distinguishes three types of DTAA: type A, which involves the proximal DTA and ends at the level of T6; type B, which involves the distal portion of the DTA starting at the level of T6; and type C, which affects the entire DTA²⁰² (see Fig. 2).

Pre-operative planning should include a CTA or MRA evaluation of the spinal cord circulation including lower lumbar and pelvic arteries, which play a major role in spinal cord blood supply in 16% and 8% of cases, respectively.^{198,199}

The pre-operative assessments of cardiac, pulmonary, and renal function, as well as carotid and peripheral arterial occlusive disease are essential to minimize the risks of mortality and morbidity associated with DTAA repair. Additional studies such as echocardiography, cardiac catheterisation, and, in selected cases, Holter 24-hour electrocardiography monitoring, are usually requested for patients with a history of coronary or valvular heart disease. Symptomatic coronary artery disease (CAD) is always treated aggressively before aortic surgery. The management of asymptomatic patients with CAD remains controversial given recent evidence suggesting a more conservative approach²⁰³ compared with older data.²⁰⁴ In the evaluation of such cases, the extent of the planned procedure and the severity of the CAD determine the pre-operative strategy.

A history of smoking and the presence of COPD increase the risk of post-operative respiratory failure. Pulmonary function tests and arterial blood gas analyses should be performed in all patients.²⁰⁵

The risk of post-operative renal failure is higher in patients with impaired renal function. This scenario can be successfully managed by pre-operative hydration and adequate renal perfusion during the peri- and post-operative period.²⁰⁶

There is robust evidence showing that the risk of SCI, mesenteric and renal ischaemia is related to the duration of cross clamping, and that cross clamp time represents the most important predictor of post-operative neurological deficit.^{28,31,114,206} Methods of extracorporeal circulation include LHB and cardiocirculatory arrest. This more aggressive approach can prove useful in the presence of rupture or when proximal aortic clamping entails a high risk.²⁰⁷ However, in a retrospective analysis of 387 consecutive DTAA, no significant paraplegia risk reduction was found by applying LHB in DTAA OR¹¹⁴ (see also Section 2.4.2 for prevention of spinal cord ischaemia).

Outcomes following elective OR for DTAA have improved over the past 25 years in some high volume centres.^{114,208,209} However, these acceptable results were not corroborated in an American National Inpatient Sample administrative database, presumably reflecting results achieved outside centres of excellence. Mortality rates in elective and emergency cases were 10% and 45%, respectively. Furthermore, spinal cord ischaemia has also been reported in the range of 11–15%.²¹⁰

3.3.2.3. Endovascular repair. Evidence comparing OR and TEVAR in the treatment of DTAA relies on systematic reviews and meta-analysis of retrospective series and non-randomized controlled or population based studies.^{211–215} The available results decisively favour a less invasive approach in terms of mortality, morbidity, and length of hospital stay. These results were, however, tempered by several less impressive results, such as long-term survival.²¹³

In a meta-analysis of 17 studies with 517 elective patients treated by OR and 538 patients treated by TEVAR, the endovascular cohort demonstrated a lower 30 day mortality rate (5.57% vs. 16.5%). TEVAR was also associated

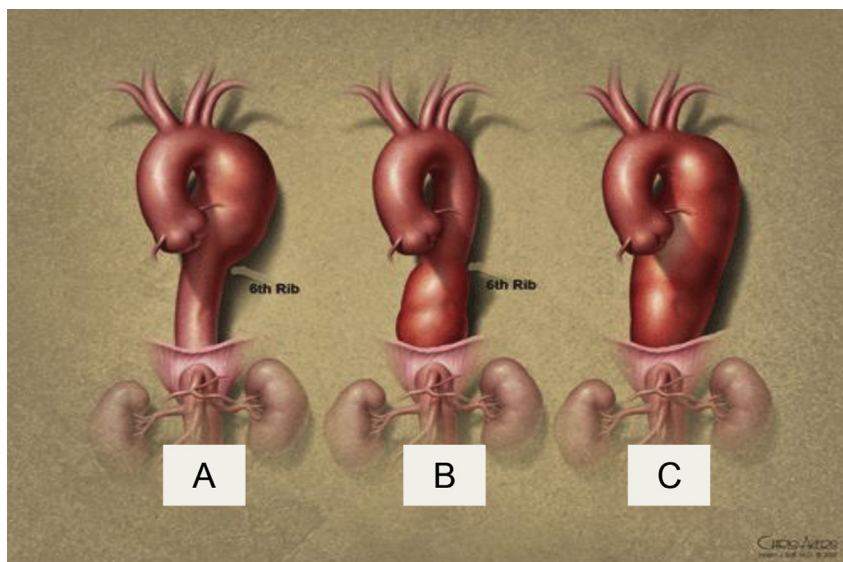


Figure 2. Classification of DTAA according to the extension.²⁰²

Recommendation 40	Class	Level of evidence	References
Computed tomographic angiography or magnetic resonance angiography should be performed for patients planned for descending thoracic aortic repair, to define the extent of the disease and to identify the potential risk of the procedure related to the main intercostal arteries	I	C	198,199
Recommendation 41			
In candidates for open surgical repair of descending thoracic aortic aneurysms with a past medical history of coronary artery disease, additional diagnostic investigations should be considered to define the severity of the underlying heart disease	IIa	C	204
Recommendation 42			
Revascularisation of symptomatic or severe asymptomatic coronary artery disease should be considered before open descending thoracic aorta surgery	IIa	C	203
Recommendation 43			
Stratification of peri-operative risk associated with pulmonary, renal, and cerebrovascular studies should be considered	IIa	C	31,205,206
Recommendation 44a			
Open repair may be considered for fit patients, with a descending thoracic aorta between 56 and 59 mm in diameter, who are unsuitable for endovascular repair	IIb	C	88,197
Recommendation 44b			
Open repair should be considered for fit patients, with a descending thoracic aorta exceeding 60 mm in diameter, who are unsuitable for endovascular repair	IIa	C	88,197
Recommendation 45			
To reduce the incidence of postoperative paraplegia, left heart bypass is not recommended for patients undergoing open repair for descending thoracic aneurysm	III	C	114

with a significant reduction in peri-operative mortality (pooled OR [odds ratio] 0.36, 95% CI 0.228–0.578; $p < .0001$). Major neurological complications occurred in 26 TEVAR patients (5.4%) and 67 OR patients (14%). Endovascular repair was associated with a reduced risk of paraplegia (pooled OR [odds ratio] 0.33, 95% CI 0.18–0.63, $p < .0007$). The risk of stroke was not affected by TEVAR (pooled OR [odds ratio] 0.77, 95% CI 0.38–1.59, $p = .48$). TEVAR had no impact on the major re-intervention rate at 48 months (pooled OR [odds ratio] 0.91, 95% CI 0.610–1.619), which was 8.4% versus 7% for OR and TEVAR, respectively.²¹²

SCI can occur after TEVAR. A recent observational study on 424 DTAA treated by TEVAR reported 12 cases of SCI (2.8%).²¹⁶ Several reports confirm that specific anatomical conditions may represent potential risk factors for post-operative SCI. These include planned coverage of the thoracic aorta over more than 200 mm or involving the level T8-T12, previous abdominal aortic surgery with ligation of lumbar arteries, an occluded hypogastric artery, and, in the emergency setting the need for LSA coverage not amenable to revascularisation. Chronic renal failure and a peri-operative MAP lower than 70 mm Hg may also play a role

in the development of SCI.^{216–218} In the presence of one or more such risk factors, CSF drainage should be performed to reduce the risk of SCI post TEVAR (see also Section 2.4.3.).

Intentional coverage of the LSA during TEVAR to provide adequate proximal sealing and fixation has been reported in 10–50% of cases. A robust body of evidence, based on observational studies, shows that this increases the risk of stroke, SCI, and upper limb ischaemia.^{44–50} An additional meta-analysis reported an almost doubled rate of cerebrovascular events (4.7% vs. 2.7%, OR [odds ratio] 2.28, 95% CI 1.24–4.09) and SCI (2.8% vs. 2.3%, OR [odds ratio] 2.39, 95% CI 1.30–4.39, $p = .005$), when the LSA was covered²¹⁹ (see also Sections 2.4.3. and 2.4.4.).

An inadequate distal landing zone of less than 15 mm length and a proximal neck diameter exceeding 40 mm are contraindications for TEVAR with currently available devices.^{215,220} These anatomical limitations occurred more commonly than the rate of 4.4% previously reported in a multicentre review of TEVAR.²²⁰ In spite of these data, safe coverage of the CA has been described to achieve acceptable distal sealing and fixation.²²¹ CTA is suitable to assess anatomical details of the distal DTA and the proximal abdominal aorta; however, selective

angiography of the CA and SMA remains the most reliable test to predict the role of potential collateral circulation following CA coverage during TEVAR.²²¹

Contraindications to CA coverage include the presence of a common coeliaco-mesenteric trunk, the absence of adequate angiographic evidence of collateral circulation, poor portal vein perfusion, and any previous conventional or endovascular procedure that may have compromised the collateral circulation.²²¹

An alternative solution to CA coverage in certain situations is a scallop-designed endograft or the use of a “snorkel or chimney technique”. The use of these techniques is promising, although supported by only few data.

entire abdominal aorta, with or without extension to the iliac arteries. A type V TAAA starts below the sixth intercostal space and tapers just above the renal arteries (Fig. 3).²²²

Using this classification, an international consensus has been achieved on describing the extent of aneurysmal disease. Both in open and endovascular repair, this classification provides an indication of the extent of the procedure, the likely technical challenges involved in any repair, and the potential post-operative risks. For example, a type IV TAAA can technically be performed by laparotomy only, whereas all the other types require a thoraco-abdominal incision, (partial) incision of the diaphragm, and temporary collapse of the left lung, reflecting the potential for

Recommendation 46a	Class	Level of evidence	References
In fit and unfit patients with favourable anatomy, endovascular repair may be considered for descending thoracic aorta aneurysms between 56 and 59 mm diameter	IIb	B	88,211–215
Recommendation 46b			
In fit and unfit patients with favourable anatomy, endovascular repair should be considered for descending thoracic aorta aneurysms >60 mm diameter	IIa	B	88,211–215

3.4. Thoraco-abdominal aortic aneurysms

3.4.1. Definition. Crawford first described the extent of thoraco-abdominal aortic aneurysms (TAAA) and his classification has found general acceptance. Type I TAAAs start at the level of the LSA, or at least proximal to the level of the sixth vertebra (T6) and affect the entire DTA, involve the visceral arteries and end at the renal arteries. The aneurysm can involve the origin of the LSA or even involve the distal aortic arch. Type II TAAAs start at the same level as a type I, but involve the DTA and the entire abdominal aorta. In many patients, especially those suffering from connective tissue diseases and post-dissection aneurysms, the iliac arteries are aneurysmal as well. Type III TAAAs start more distal than type II aneurysms, usually at the level of T6, and extend distally as in a type II. Type IV TAAAs start at the level of the diaphragm and involve the

substantial differences in surgically induced trauma between these two exposures. Furthermore, the five types are each associated with different end organ complications such as paraplegia, renal failure, and visceral ischaemia.

3.4.2. Management.

3.4.2.1. Indications for repair. It is extremely important to assess the risk of any intervention against the risk of rupture. Extensive pre-operative risk analysis is required as an essential part of the decision making process, especially in patients with comorbidities. General consensus exists regarding surgical repair of TAAA for low to moderate surgical risk patients with TAAA larger than 60 mm (less for patients with connective tissue disorders), rapid growth (>10 mm/year), or with symptoms.^{112,223}

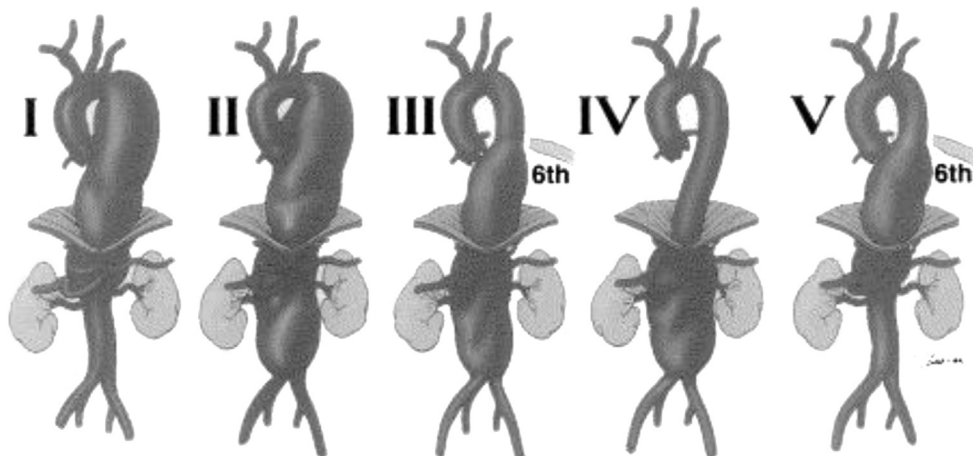


Figure 3. Crawford TAAA classification modified by Safi.²²²

Recommendation 47	Class	Level	References
Open or endovascular repair should be considered for patients at low to moderate surgical risk, with an atherosclerotic or degenerative thoraco-abdominal aortic aneurysm of 60 mm or larger diameter, rapid aneurysm enlargement (>10 mm/year), or aneurysm related symptoms	IIa	C	223

3.4.2.2. Open repair. Open TAAA repair is a major aortic intervention and is associated with post-operative complications including myocardial infarction, respiratory failure, renal insufficiency, stroke, paraplegia, and death. To estimate the risks of OR, pre-operative cardiopulmonary and renal assessment is required. Patients with degenerative TAAA are usually older than patients with post-dissection or connective tissue disease aneurysms. A substantial number (34–40%) will suffer from CAD, and compromised cardiac function is a strong predictor of post-operative mortality.²²⁴ In patients with COPD and in smokers, pulmonary function is significantly reduced in 23–36%, leading to oxygenation problems during peri-operative single-lung ventilation, prolonged post-operative ventilatory support, and pneumonia.²²⁵ Pre-operative spirometry and blood gas analysis can detect pulmonary compromise, and appropriate respiratory training programmes and medical treatment can be initiated to improve lung function. Pre-existing renal insufficiency is also a predictor of post-operative renal failure and mortality and should be taken into account when considering OR.²²⁶

In OR, proximal aortic cross-clamping causes increased pre- and after-load on the heart. In addition, all organs and tissues distal to the clamp will be excluded from the circulation, including the spinal cord, visceral organs, kidneys, and legs. The application of extracorporeal circulation with distal aortic perfusion has reduced ischaemic complications. Several techniques for extracorporeal circulation can be used, including LHB by means of a left atriofemoral bypass circuit or femoral veno-arterial bypass^{40,227} (see also Sections 2.4.2. and 3.3.2.2.).

During TAAA repair, the CA and the SMA should be perfused with blood and both renal arteries should be perfused with either cold crystalloid or blood to reduce end-organ ischaemia.²²⁸ Despite protective measures such as antegrade mesenteric perfusion, or retrograde perfusion with sequential clamping, mucosal damage can still occur and inflammatory reactions are induced.²²⁹

Risk factors for the development of SCI include prolonged aortic cross clamp time, extensive aneurysmal disease, aortic dissection, emergency surgery, internal iliac artery exclusion, and previous abdominal aortic procedures. Several strategies to limit neurological complications include distal aortic perfusion, intercostal artery reimplantation,³⁷ CSF drainage,^{29,37,230} spinal cord cooling,²³¹ and assessment of spinal cord function peri-operatively³⁰ (see also Section 2.4.2.).

In two recent reviews, all available strategies to prevent SCI were summarized.^{37,230} Despite lacking definitive proof

of efficacy, compelling data exist to support the use of CSF drainage along with methods of aortic perfusion distal to the cross-clamp.²³⁰ A multimodal approach including CSF drainage, maintenance of adequate MAP, LHB, and revascularisation of intercostal arteries seems to be effective in reducing the risk of SCI.²³²

The majority of publications on the results of open TAAA repair originate from individual series, coming from highly specialized centers.^{30,225,227} The results of these experienced centres report mortality rates varying between 5% and 15%. Major complications include respiratory failure (up to 60%), neurological deficits (3–18%), and renal failure (3–15%). Outside highly specialized centres, mortality and morbidity rates are almost doubled. A United States state-wide database showed 30 day and 1 year mortality rates after elective TAAA repair of 19% and 31%, respectively.²³³ These results indicate that these complex procedures should be performed only in specialized centres. Indeed, adequate staff support and hospital and surgeon volume significantly influence post-operative survival. Another study²³⁴ clearly demonstrated that less experience correlated with increased post-operative mortality: in 1,542 operated patients, a significant difference ($p < .001$) in mortality was determined between low volume hospitals (27.4%) and high volume hospitals (15%). Also, low volume surgeons had significantly ($p < .001$) higher mortality rates (25.6%) compared with high volume surgeons (11.0%). These volume outcome relationships were summarized in a systematic review.²³⁵

3.4.2.3. Endovascular repair. Despite improvements in peri-operative care and various surgical adjuncts, cardiopulmonary, renal, and neurological complications such as SCI are still common problems after open TAAA repair. Thus, alternative managements have been sought, with two approaches currently under evaluation.

In the first, defined as the “hybrid approach”, visceral perfusion was safeguarded by means of an OR extra-anatomic bypass, followed by endovascular exclusion of the entire aneurysm. This approach has the advantage of limiting exposure to a laparotomy while avoiding a thoracotomy, although, this remains a considerable undertaking in unfit patients. The issue of a single stage versus two stage strategy has been debated, with higher mortality and renal failure rates associated with one stage procedures and an increased risk of death resulting from rupture while awaiting the second stage.²³⁶ Early results, in terms of mortality, SCI, and morbidity rates, generated considerable enthusiasm.²³⁷ Recent data on 5 year patency rates were also encouraging.²³⁸ Currently, the hybrid technique is usually restricted to patients with no

Recommendation 48	Class	Level of evidence	References
In patients planned for open or endovascular thoraco-abdominal aortic aneurysm repair, pre-operative cardiac, pulmonary, and renal function should be assessed to estimate surgical risks and initiate therapy to improve the pre-operative status	I	C	224–226
Recommendation 49			
In open type I, II, and III thoraco-abdominal aortic aneurysm surgery, extra-corporeal techniques allowing distal aortic and organ perfusion should be considered to reduce ischaemic complications, especially in extensive aneurysms requiring prolonged cross clamping time	IIa	C	227,228
Recommendation 50			
In patients with extensive thoraco-abdominal aortic aneurysm (type I, II, III) undergoing open repair, cerebrospinal fluid drainage should be considered as a measure to decrease the risk of neurological deficit	IIa	B	29,37,230
Recommendation 51			
An integrated approach with optimisation of mean and distal aortic arterial pressure, moderate hypothermia, neuromonitoring, and reimplantation of intercostal arteries should be considered to protect the spinal cord during thoraco-abdominal aortic aneurysm surgery	IIa	C	232
Recommendation 52			
Centralisation of open repair of thoraco-abdominal aortic aneurysm in dedicated high volume centres may be considered	IIb	C	234,235

other reasonable options, such as emergency cases or high risk patients with anatomy unfavourable for a branched endograft.

The second technique (currently in evolution) is a total endovascular repair using specifically constructed branched modular aortic grafts. The rationale for this approach grew out of the promising initial experience with fenestrated grafts, which were developed to treat juxta-renal aneurysms by endovascular means.²³⁹ Preservation of visceral flow is achieved by means of either fenestrations or branches or a combination of both on the component deployed in the region of the visceral arteries. The aortic anatomy is still a limiting factor, but the progress in imaging and device conception has begun to overcome this challenge. Initial reports of the technique have all been from single centre studies and are non-randomized.^{240–242} Many patients are deemed unfit for OR of TAAA, particularly older patients, and this cohort represents the group that have endovascular TAAA repair.

The published 30 day mortality rates range from 5.2% to 9.7% in the larger series (2.3%–2.6% for type IV TAAA).^{240–243} Rates of SCI and cardiopulmonary and renal morbidities appear to be largely in concordance with rates observed following OR.^{240–243} The largest series of endovascular repair of TAAA (406 patients) reported similar paraplegia risks between endovascular and OR (4.3% endovascular repair vs. 7.5% OR, respectively, $p = .08$).²⁴¹ The SCI risk was associated with COPD, procedure duration, extent of the aortic disease, and prior aortic surgery. Clinical improvement after SCI has been reported.²⁴⁰

As in open procedures, patients with type I, II, or III TAAAs have a higher risk of post-operative SCI and death, when compared with type IV. In the short- to mid-term,

endovascular repair appears to be durable with acceptable secondary re-intervention rates. One year survival rates between 76% and 87% were reported and were largely dependent on patient selection.^{239–243}

The pre-operative clinical characteristics of the patients investigated in these series may mean there is a negative bias towards treating patients with greater comorbidities. Therefore, the outcome of TAAA patients managed with a minimally invasive approach, although associated with positive results, still has a consistent rate of morbidity and mortality. Patients undergoing these procedures, most of whom have been rejected for OR, remain vulnerable in the post-operative period. The relatively significant risk of in hospital death with advancing age and chronic renal failure underscores the importance of excluding patients with poor physiological status and limited life expectancy. By contrast, the encouraging mid-term results suggest that this technique has a role in relatively unfit patients, especially when performed in high volume centres.^{239–243}

3.5. Inflammatory diseases of the descending thoracic aorta

3.5.1. Takayasu arteritis. Takayasu arteritis (TA), also known as pulseless disease, is a rare form of large vessel granulomatous vasculitis with massive intimal fibrosis and vascular narrowing, or destruction of the elastic fibres and aneurysm formation.²⁴⁴

The pathogenesis of TA is poorly understood. Some evidence suggests that a viral/bacterial infection of some kind, in a person with other predisposing factors (such as genetic disorders), may lead to this disease.²⁴⁵

Recommendation 53	Class	Level of evidence	References
For thoraco-abdominal aneurysm repair, in patients unfit for open repair, an endovascular procedure should be considered	Ila	C	239–243
Recommendation 54			
For thoraco-abdominal aneurysm repair in patients unfit for open repair with aortic anatomy unfavourable for a branched/fenestrated endograft, a hybrid approach should be considered	Ila	C	237,238
Recommendation 55			
Centralisation of endovascular repair of thoraco-abdominal aortic aneurysm in dedicated high volume centres may be considered	IIb	C	242

The American College of Rheumatology proposed the following criteria for diagnosing TA:

- 1) Age of onset younger than 40 years.
- 2) Intermittent claudication.
- 3) Diminished brachial artery pulse.
- 4) Subclavian artery or aortic bruit.
- 5) Systolic blood pressure variation greater than 10 mm Hg between arms, and
- 6) Angiographic (CT, MR) evidence of aortic or aortic branch vessel stenosis.

The presence of three or more of these six criteria demonstrated a high sensitivity and specificity for the disease.²⁴⁵

The clinical manifestation of TA is typically described in two phases: 1) a systemic “acute” phase, and 2) a “chronic” phase. These two phases are not always distinct and patients may have features of both phases at the same time. In the systemic phase, patients have symptoms and signs of an active inflammatory disease. These may include “constitutional symptoms” (fever, fatigue, weight loss), arthritis, and non-specific aches and pains. This phase is succeeded by the chronic phase, typical for symptoms presenting in affected organs. Patients may experience claudication of upper and/or lower limbs, symptoms associated with cerebrovascular insufficiency (dizziness on standing up, headaches, visual problems, transient ischaemic attack, or stroke), hypertension secondary to renal artery involvement, or aortic regurgitation caused by aortitis.

The thoracic aorta itself may be involved in the inflammatory process and develop either aneurysms or stenoses. The diagnosis is confirmed by CTA or MRA, which show stenosis and dilation of the aorta, its branches, or both. Thickening of the aortic wall detected by MRI or ultrasonography can precede the angiographic changes.

Treatment of TA is based principally on corticosteroids. The great majority of patients respond to prednisone, which is effective for the systemic symptoms and can impede further progression of the vasculitis. The usual starting dose is approximately 1 mg/kg of body weight per day. Because of the significant side effects of long-term high dose prednisone use, the high starting dose is

tapered over several weeks to a dose that is more tolerable for the patient, with respect to the decrease of C-reactive protein and erythrocyte sedimentation rate (ESR). For life-long treatment, methotrexate, azathioprine, and even cyclophosphamide are sometimes used in addition to prednisone.

There are few data in the literature to identify TA patients who require operation. Evidence for surgical or endovascular repair of thoracic aortic disease in patients with TA is extremely limited. It seems acceptable to maintain the same indications as in non-inflammatory disorders, based on the risk of rupture related to aneurysm dimension, and the presence of secondary organ vascular insufficiency.

In an 8 year study including 11 patients with TA ($n = 3$), GCA ($n = 2$), and MFS ($n = 6$), endovascular repair of complicated aortic aneurysms proved safe and feasible.²⁴⁶ However long-term durability in this younger group of patients who have an ongoing risk of arterial degeneration remains to be determined.

3.5.2. Giant cell arteritis. Giant cell arteritis (GCA), also known as temporal arteritis or cranial arteritis,²⁴⁷ is a systemic, inflammatory, vascular syndrome that affects the aorta and its secondary and tertiary branches.

Although arteritis is a basis for aneurysms, dissections, and stenotic lesions of the aorta and its major branches, patients with GCA experienced similar mortality rates to the general population of similar age and gender.²⁴⁸

The aetiology of GCA is unknown, but the pathogenesis is similar to TA and involves a chronic inflammatory process, which releases several cytokines, including T-lymphocyte products interferon-gamma (IFN-gamma) and interleukin (IL)-2. The T-cell clonal expansion suggests a specific antigenic response, which is still unclear (viral, bacterial, or other). Concentric intimal hyperplasia is an important underlying pathologic lesion in GCA.²⁴⁹

Clinical presentation varies from fever of unknown origin to constitutional symptoms. Arterial lesions may be widespread and the variable expression of GCA can be analyzed according to the anatomical pattern of the arteries affected. Polymyalgia rheumatica (PMR) and GCA may represent two parts of a single disease spectrum, with GCA at the more severe end. The two processes share certain constitutional symptoms, including fatigue, weight loss, and fever.

The following are criteria for GCA defined by the American College of Rheumatology in 1990²⁴⁷: 1) age 50 years or older; 2) new onset localised headache; 3) temporal artery tenderness or decreased temporal artery pulse; 4) ESR of at least 50 mm/h; and 5) abnormal arterial biopsy specimen characterized by mononuclear infiltration or granulomatous inflammation. The presence of at least three criteria yields a diagnostic sensitivity of 93.5% and specificity of 91.2% when compared with patients who were clinically classified as having the disease. In the case of localisation of disease to the temporal artery, biopsy is diagnostic in the majority of cases, although its sensitivity declines with the initiation of steroid therapy.²⁵⁰

A population based study over 50 years in patients with GCA revealed a 31% cumulative frequency of large artery complications, including aortic aneurysm or aortic dissection in 18%, and/or large artery stenosis in 11%.²⁵¹ Presence of thoracic aortic dissection was associated with markedly increased mortality (median survival of only 1.6 years after diagnosis of GCA).²⁵²

A comparative study suggested that a steroid regimen, starting with 30–40 mg/day and tapering to 10 mg/day within 6 months and to 5–7.5 mg/day within 1 year, is effective and better tolerated in the patient population, than the two higher dose regimens (40–60 or >60 mg/day).²⁵³

In refractory cases, the use of immunosuppressants, such as methotrexate (15–25 mg/week) or azathioprine (2 mg/kg/day), as potentially steroid-sparing disease controlling drugs, has been considered and has shown conflicting results.²⁵⁴ The newer tumour necrosis factor antagonists are being evaluated in clinical trials, but initial studies of infliximab did not show promising results.²⁵⁴ Encouraging results have been reported from the use of low dose aspirin for prevention of visual loss and stroke in patients with GCA.²⁵⁵

Indications for surgical or endovascular repair in patients with GCA are similar to non-inflammatory disorders, and the decision in each patient is based on the risk of rupture related

to aneurysm dimension, and the presence of secondary organ vascular insufficiency related to fibrotic stenosis.

3.5.3. Behçet disease. This syndrome carries the name of the Turkish dermatologist Hulusi Behçet, who, in 1937, described a syndrome of recurrent aphthous ulcers, genital ulcers, and uveitis.²⁵⁶ Vascular manifestations may vary and depend on the type and location of the vessel involved. Any large or small artery, vein, or organ may be involved in an unpredictable combination. The most common vascular complaints are secondary to venous thrombosis, often of the superficial veins.

Surgical and endovascular repair of aneurysm in Behçet disease has been described as feasible. After surgical repair, a high recurrence rate of anastomotic false aneurysm has also been described, caused by the friability of the diseased arteries. Moreover, any surgery may exacerbate Behçet disease, so patients must be prescribed immunosuppressive therapy before and after the surgical intervention.²⁵⁷ Because pseudoaneurysms may develop at arterial puncture sites and veins may be quickly thrombosed after injection of contrast material, angiography and venography should be avoided whenever possible.²⁵⁸

3.5.4. Other inflammatory aortitides. Other chronic diseases with potential inflammatory involvement of the thoracic aorta include rheumatoid arthritis, sarcoidosis, Cogan syndrome, Kawasaki disease, ankylosing spondylitis, systemic lupus erythematosus, and Wegener's granulomatosis.²⁵⁹ Some types of aortitides remain idiopathic.

Cardiovascular involvement in these patients is variable, consisting of aortic valve regurgitation, aneurysm formation, dissection or stenosis of the aorta or its initial branches. Localisation of the inflammatory disease at the level of the aortic root with consequent aortic valve regurgitation is the most common cardiovascular complication in these patients. The involvement of the DTA is extremely rare but potentially more prone to rapid growth

Recommendation 56	Class	Level of evidence	References
Corticosteroids should be the first line of treatment in patients with inflammatory diseases associated with thoracic aortic disease	I	C	253,254
Recommendation 57			
For a patient with an inflammatory disease of the descending thoracic aorta, tapering the starting corticosteroid dose over several weeks to a dose that is acceptable for the patient, with respect to the decrease of inflammatory markers, should be considered to avoid significant side effects of long-term high dose corticosteroid use	IIa	C	253
Recommendation 58			
Selective repair should be considered for patients with thoracic inflammatory disease based on the risk of rupture related to aneurysm size, and the presence of secondary end organ ischaemia	IIa	C	246,257
Recommendation 59			
In patients with an inflammatory disease of the descending thoracic aorta undergoing surgical intervention, application of a higher dose of corticosteroids and/or immunosuppressive agents before and after the intervention should be considered	IIa	C	257

and rupture.²⁶⁰ In particular, systemic lupus erythematosus has been suggested as possibly associated with thoracic AD, especially in patients with persisting inflammation while on chronic steroid therapy.²⁶⁰

3.6. Coarctation of the thoracic aorta in adults

3.6.1. Definition and diagnosis. Aortic coarctation is a congenital defect characterized by stricture of the aortic lumen typically located at the region of the ligamentum arteriosum. This narrowing is usually localised, but may involve other segments of the aorta such as the arch and, less often, the abdominal aorta. There is significant variation in the degree of stenosis, extent of disease, and clinical manifestations. Generally, an extensive collateral circulation is present in adults.

Men are more often affected (2:1).²⁶¹ Clinical manifestations include upper limb hypertension, weak and delayed femoral pulses, and lower limb claudication. A thoracic bruit may be present. In advanced cases, heart failure or intracranial haemorrhage commonly develop. When the aortic gradient is less pronounced or collaterals are well developed, symptoms may be absent or mild. Other cardiovascular abnormalities include ventricular septal defects, bicuspid aortic valve, sub-aortic stenosis, aortic medial disease, aortic arch hypoplasia, patent ductus arteriosus, and intracranial aneurysms.²⁶² Adult patients most commonly present with discrete forms of the disease, which may remain occult during childhood and have no association with congenital cardiac abnormalities, or present with recurrence after intervention. There are currently no data on the exact incidence of coarctation manifesting in adulthood.

Both CTA and MRI provide anatomical evidence of coarctation and are the investigations of choice for definitive diagnosis. The aortic gradient may be directly measured by catheterisation, or indirectly estimated using Doppler echocardiography or cardiovascular MR.²⁶³

While TTE is usually diagnostic in children, it is often inconclusive in adults. However, TOE is the method of choice to evaluate cardiac sequelae such as ventricular hypertrophy and left ventricular dysfunction, and association with congenital cardiac abnormalities. CTA is a good alternative to MRA, despite absence of functional information. Diagnostic DSA and invasive gradient measurements can be reserved for cases where non-invasive methods fail to provide the necessary information for decision making.

CAD, or complications associated with valvular or cerebral disease.²⁶⁴

After intervention, hypertension resolves in two thirds of patients and the majority of them will benefit from improved ventricular function, reduced ventricular mass and improved ascending aortic distensibility.²⁶⁵ Intervention should be balanced between the anticipated benefits and the patient's life expectancy, surgical risk and comorbidities. In adults the pathological changes resulting from aortic coarctation may no longer be reversible.^{265,266}

3.6.2.1. Indications for repair. Treatment is indicated for symptomatic patients and should be considered for asymptomatic patients with a trans-coarctation gradient >20 mm Hg or persistent upper limb hypertension (systolic pressure >140 mm Hg or diastolic pressure >90 mm Hg). These thresholds are based on expert opinion only, but are supported by clinical evidence suggesting that intervention before large gradients are present may confer a higher chance of reversing left ventricular dysfunction and preventing irreversible loss of aortic wall compliance.^{265,266} There are two potential invasive treatment strategies, open and endovascular surgery; however, given the rarity of patients requiring invasive treatment, there are no randomized trials comparing these two options. Case series and non-randomized studies suggest marginally increased peri-operative morbidity rates with OR, and greater recurrence rates after endovascular repair.^{265–267} Regardless of treatment strategy, centralisation of treatment into expert centres should be considered.

3.6.2.2. Open repair. OR is the classical method of treatment for aortic coarctation. The most common techniques include resection and end to end anastomosis, or an aortic interposition graft. Alternative techniques have been proposed, such as patch or subclavian flap aortoplasty, or ascending to descending aortic bypass with or without valve replacement, but are generally only performed in expert centres.²⁶⁷ Operative mortality after OR is generally very low (<1%). Complications of OR include rebound hypertension, phrenic and recurrent laryngeal nerve injury, recurrence of coarctation, and aneurysm or pseudo-aneurysm formation at the patch site. Rarely, paraplegia and arm claudication (only if a subclavian flap is used) may occur.²⁶⁷

3.6.2.3. Endovascular repair. Anatomical suitability, with a combination of good access vessels, and a short and crossable lesion, is a necessary requirement for endovas-

Recommendation 60	Class	Level of evidence	References
In adult patients with aortic coarctation, magnetic resonance angiography should be considered the imaging technique of choice for anatomical characterisation, investigation for associated cardiovascular abnormalities, and to estimate aortic flow gradients	Ila	C	263

3.6.2. Management. Without treatment, mortality is 25% at age 20, 50% at 32, and 75% at 46.²⁶⁴ Most patients die as a result of heart failure, acute aortic syndromes, premature

cular repair. Operative mortality following endovascular repair is very low (<1%). Rarely, aortic rupture (1–2% after simple balloon dilatation), retrograde or antegrade

Recommendation 61	Class	Level of evidence	References
Open or endovascular repair should be performed in patients with coarctation of the thoracic aorta and clinical manifestations resulting from left ventricular dysfunction, severe hypertension or lower limb ischaemia	I	C	265
Recommendation 62			
Patients with coarctation of the thoracic aorta without clinical symptoms, but with a significant aortic gradient at rest (>20 mm Hg) and/or proximal systemic hypertension (>140/90 mm Hg), should be considered for open or endovascular repair	Ila	C	265

dissection (<1%), stroke, or access problems may occur. Such data make endovascular repair a valid alternative to OR in native coarctations. Late complications of endovascular repair include re-coarctation, which occurs more often compared to OR and aneurysm formation (0–12% after simple balloon dilatation).^{266–268} In adults, stent placement appears to reduce late complications (particularly aneurysm formation) and recurrence.²⁶⁷ Although there is no current evidence to justify preferential use of covered, straight, or tapered stents, these should be readily available to expeditiously treat aortic rupture following angioplasty.²⁶⁸ Provided anatomical suitability, an endovascular-first approach may be beneficial for the treatment of re-coarctation.²⁶⁹

gene encoding transforming growth factor beta receptor 2 (TGF β R2), which has already been reported in LDS.²⁷²

A diagnosis of MFS can be established by clinical evaluation alone in the majority of cases. In 1998, the Ghent criteria specified the characteristics of the phenotype and genotype that can be assessed through history, physical examination, imaging, and molecular genetic testing.²⁷⁰ More recently, an international expert panel has established a revised nosology, which puts more weight on aortic root aneurysm (or dissection) and ectopia lentis. Then, in the absence of a family history, the diagnosis of MFS can be made in the case of aortic root enlargement and the presence of ectopia lentis; in the case of aortic root enlargement and the presence of 7 or more points of

Recommendation 63	Class	Level of evidence	References
For adult patients with aortic coarctation, centralisation of treatment to expert centres may be considered	Ilb	C	266–268
Recommendation 64			
In anatomically suitable patients with native thoracic aortic coarctation, endovascular repair should be considered as an alternative to open repair	Ila	C	266,267

3.7. Miscellaneous

Genetic, congenital, and neoplastic pathologies can involve the DTA.

3.7.1. Genetic syndromes.

3.7.1.1. Marfan syndrome. Marfan syndrome (MFS) is a heritable connective tissue disorder. A mutation of the fibrillin-1 (FBN-1) gene on chromosome 15 has been found in patients with MFS.

Estimates indicate that approximately 1 in 3,000–5,000 individuals have MFS.²⁷⁰ The mutation is inherited as a dominant trait, so each parent with the condition has a 50% risk of passing the genetic defect on to any child. Around one in four patients has no family history, and the syndrome is the result of a spontaneous mutation.

Recently a second type of the disorder (MFS type 2, MFS2) has been identified.²⁷¹ These mutations are in the

a systemic score; and in the case of aortic root enlargement and a probably causal FBN1 mutation. Finally, the occurrence of ectopia lentis together with an FBN1 mutation known to be associated with aortic dilatation is also sufficient to make the diagnosis. Together with a family history, ectopia lentis or aortic root enlargement or a systemic score ≥ 7 are sufficient to make the diagnosis in adults.²⁷⁰

The sensitivity of molecular genetic testing is substantial yet imperfect for unidentified reasons. It may be justified by atypical location or character of *FBN1* pathogenic variants in some individuals or to locus heterogeneity.²⁷³

MFS has a range of expressions, from mild to severe. The most serious complications are defects of the heart valves and aorta. The most severe cardiovascular complication is acute type A aortic dissection, but type B dissection is also common. AAA is rare.

TTE measurement of the aortic root is very important for the diagnosis and follow up of aortic complications in patients with MFS.²⁷⁴ Generalized aortic root dilatation is a potent marker of an increased risk of subsequent aortic complications in MFS, while dilatation limited to the sinuses of Valsalva without including the aortic arch has a less malignant prognosis. After diagnosis of aortic root/ascending aortic dilatation is made, regular two dimensional TTE is recommended at 6 months and then annually if no further progression of the disease is demonstrated.

Some studies have shown that prophylactic beta-adrenergic blockade is effective in slowing the rate of aortic dilatation and reducing the development of aortic complications in some patients with MFS.²⁷⁰ Some randomized studies revealed that treatment with an angiotensin II receptor blocker may decrease aortic diameters in adult patients with MFS.²⁷⁵ However, more recent data did not show any advantages for angiotensin II receptor blockers in comparison with atenolol among children and young adults with MFS and large aortic root dilatation. A significant decrease in the degree of aortic root dilatation, relative to body surface area, was observed with both treatments.^{81,82}

It is now essential to await results of ongoing large, collaborative, randomized controlled trials²⁷⁶ with clinical end points to assess the novel medical treatments in MFS.

Determination of the size threshold in MFS for surgical repair of thoracic aneurysm is not easy. Surgery is generally recommended for a dilatation ≥ 50 mm, which is a lower threshold in comparison with other patients with thoracic aortic dilatation.^{54,274} Other factors that may significantly influence timing of aortic surgery include: 1) rate of growth >2 mm per year; 2) presence of significant aortic regurgitation; and 3) family history of dissection, especially if dissection occurred at aortic diameter ≤ 50 mm. In cases with borderline indication (diameter ≥ 45 mm), a well defined increase in aortic diameter >3 mm/year (on repeated measurements using the same imaging technique, measured at the same aortic level with side by side comparison and confirmed by another technique) may be an indication for surgical treatment.

Surgery to the aortic root and thoracic and thoraco-abdominal aorta has resulted in significantly prolonged life expectancy in many patients. The evidence for thoracic endovascular repair in MFS is much more limited, with only small series and registry or case reports including a heterogeneous group of patients with only short-term follow up.¹⁹³ More recently, particularly in patients with an increased surgical risk because of redo sternotomy or thoracotomy, a gradual move to endovascular repair has been observed, but this approach cannot be recommended for routine use in patients with MFS.

Women with MFS are at high risk of aortic dissection in pregnancy even in the absence of pre-conception aortic root/ascending aorta dilatation. Although women with aortic root dilatation of <40 mm usually tolerate

pregnancy well, with good maternal and foetal outcomes, they should be advised regarding the risk of pregnancy to both mother and foetus. Patients who have aortic root dilatation >40 mm are recommended to avoid pregnancy.²⁷⁷

3.7.1.2. Loeys-Dietz syndrome. Loeys-Dietz syndrome (LDS) is an autosomal dominant genetic syndrome caused by mutations in the genes encoding transforming growth factor beta receptor 1 (TGF β R1) or 2 (TGF β R2).²⁷⁸ Given that this syndrome was only recently described, its incidence is currently unknown. Four main characteristics are commonly seen in individuals with LDS: 1) arterial tortuosity (twisting or spiralled arteries), most often occurring in the vessels of the neck; 2) hypertelorism (widely spaced eyes); 3) bifid (split) or broad uvula; and 4) aneurysms (although most often observed in the aortic root leading to AD, can also be found in other arteries throughout the body).

Cardiovascular involvement in LDS has been reported as very aggressive with aneurysm formation and dissection/rupture at a young age. Aortic root aneurysms are common and often lead to AD. Aneurysms of the ascending or DTA are less often seen and are seldom isolated. In the initial clinical series,²⁷⁹ mean age at first dissection was 26 years, dissection occurred at aortic diameters as small as 39 mm and the median age of death was 37 years.

Currently suggested criteria for elective intervention for asymptomatic aneurysms in adults with LDS include an aortic diameter >40 mm for the aortic root and abdominal aorta,²⁸⁰ >50 mm for the DTA, and/or rapid expansion (>5 mm/year) regardless of location. Considering that dissection has been reported in aneurysms <40 mm in diameter, even these criteria might not eliminate the risk of dissection or death, and earlier interventions might be indicated, depending on family history or an evaluation of the risks and benefits of surgery. A strategy of early and aggressive surgical intervention seems to be justified, especially given the typically young age of these patients, the generalized tolerance of surgery, and the rarity of complications related to tissue fragility.²⁸¹ A definite threshold diameter for intervention in cases of TAA has not been established and the matter requires further investigation with larger series.

3.7.1.3. Ehlers-Danlos syndrome. Ehlers-Danlos syndrome (EDS) is a group of disorders that share common features including easy bruising, joint hypermobility, skin hyperelasticity or laxity, and weakness of tissues, including arteries.

In the vascular type of EDS (formerly called type IV), spontaneous rupture of arteries and bowel are serious manifestations that can lead to death. It is primarily inherited as an autosomal dominant genetic disorder. Arterial rupture may be preceded by aneurysm formation, arteriovenous fistulae, or dissection but may also occur spontaneously. The anatomic locations of arterial rupture are the thorax and abdomen (50%), head and neck (25%), and extremities (25%). Such complications are dramatic and often unexpected, presenting as sudden death, stroke and

its neurological sequelae, acute abdomen, retroperitoneal bleeding, and/or shock. The average age for the first major arterial or gastrointestinal complication is 23 years, and the life expectancy is only 48 years.²⁸²

Surveillance may include periodic arterial screening by MRI or computed tomographic imaging with or without contrast. A conservative approach is usually recommended for vascular type of EDS; however, urgent surgery may be required to treat potentially fatal complications.

From a pharmacological point of view, a recent multicentre, randomized and blinded study suggested that celiprolol, a $\beta(1)$ -adrenoceptor antagonist with a $\beta(2)$ -adrenoceptor agonist action, prevents dissections and arterial ruptures in patients with vascular EDS.²⁸³

A number of patients develop post-operative anastomotic pseudoaneurysms despite utilisation of a number of precautions including delicate and atraumatic handling of tissues, and sewing of anastomoses with pledgeted sutures.²⁸⁴

At present, knowledge of the use of stents to treat vascular complications of EDS is insufficient. Novel approaches using endovascular repair with coil embolisation have also been attempted, with good results in selected cases of ruptured pseudoaneurysms, visceral aneurysms, and carotid-cavernous fistulas. However, because of the risk of arterial rupture following arterial puncture, indications for endovascular aortic repair remain to be determined.²⁸⁵

Maternal mortality during pregnancy in the vascular type of EDS is around 12%, because of uterine or vascular rupture, particularly during the last trimester. To minimise the risks related to contractions and achieve haemostasis, a Caesarean section should be carried out before the onset of labour.²⁸⁶

3.7.1.4. Turner syndrome. Turner syndrome (TS) is a genetic disorder of female development with cardinal features of short stature and congenital cardiovascular defects. It is a chromosomal condition in which all or part of one of the sex chromosomes is absent. Analysis of cytogenetic screening studies indicates that TS occurs in $\sim 1/200$ conceptions but only $1/2000$ live female births, with congenital cardiovascular defects leading to a high rate of foetal death.²⁸⁷

An epidemiological study of Danish and Swedish records found the median age of onset of AD or rupture in TS to be 35 years, with a projected annual incidence of approximately 15 cases/100,000 for individuals <20 years of age, 73–78 cases/100,000 for women 20–40 years old, and $\sim 50/100,000$ for older women with TS. Of note, the incidence of AD in the general Danish population was 6/100,000 in the same study.²⁸⁷

Patients who develop AD have aortic valve disease and/or coarctation in 10–25% of cases. While apparently all TS patients younger than 20 years have some structural congenital heart disease, about 10% of adults with TS that have died from aortic dissection have no evidence of major structural defects on autopsy.²⁸⁸

Evidence for regular screening for aortic disease in women with TS is not available. A baseline cardiovascular evaluation should be obtained at the time of diagnosis and includes MRI in addition to echocardiography. These studies

should be repeated every 5–10 years, or earlier if clinically indicated by pregnancy or by known risk factors for AD such as hypertension, bicuspid aortic valve, or coarctation.²⁸⁸

A recent study investigating the effect of supra-physiological doses of growth hormone to increase adult height in patients with TS, which may have direct effects on the cardiovascular system, revealed that this regimen neither seems to affect ascending or DTA diameter beyond the increase related to the larger body size nor does it disproportionately affect cardiac dimensions.²⁸⁹

3.7.1.5. Familial thoracic aortic disease. A family pattern of transmission of familial thoracic aortic aneurysm and dissection has been described recently.⁶² Studies have confirmed the genetic nature of DTAA in a large population of affected patients and families, with an inherited pattern for DTAA present in up to 21.5% of non-Marfan patients. Patterns of inheritance and phenotypic features among family clusters have also been identified.⁶² These statistics underestimate the true prevalence of familial aneurysm disease because many family members may harbour unknown aneurysms. For this reason it is quite likely that the true rate of inheritance of DTAA is even higher than 20%.

Although certain chromosomal loci have been identified, complete identification of the genes leading to this familial non-syndromic form of DTAA is still in the early phase of investigation.²⁹⁰ Some families have not mapped to either of these loci suggesting that additional loci may contribute to the constellation of genes responsible for aneurysmal predisposition. The predominant mode of inheritance is autosomal dominant, with reduced gene penetrance in women. Variable expressivity and multiple anatomic locations of familial arterial aneurysms have been observed.

Patients with familial DTAA are significantly younger at the time of presentation than patients with sporadic TAAA, but not as young as patients with MFS. The aortic growth rate has been reported to be 2.1 mm/year, which is faster when compared with sporadic DTAA patient growth (1.6 mm/year), and MFS (1 mm/year).

The aggressive clinical course of this disease underscores the importance of appropriate screening in extended relatives of patients with familial non-syndromic DTAA. Secondary prevention strategies employed for patients with MFS including angiotensin converting enzyme inhibitor administration, should also be evaluated for patients with early onset familial DTAA.

All first degree relatives of patients considered to be part of a familial aneurysm disorder may be considered for screening imaging to evaluate for DTA and AAA at the age of 50, with repeat surveillance at regular intervals (e.g. 2–3 years).

3.7.2. Aortic tumours. Primary tumours of the aorta are rare and are usually malignant. The diagnosis may be complicated as aortic tumours can clinically mimic heterogeneous conditions such as aneurysm, dissection, aortic coarctation, floating thrombus, intrathoracic, abdominal or retroperitoneal malignancies, and atherosclerotic

Recommendation 65	Class	Level of evidence	References
In patients with Marfan syndrome, trans-thoracic echocardiographic measurement of the aortic root should be considered for the diagnosis and follow up of aortic involvement	IIa	C	274
Recommendation 66			
In Marfan syndrome, use of prophylactic beta-adrenergic blockade and of angiotensin II receptor blockers should be considered	IIa	C	82,270
Recommendation 67			
In patients with Ehlers-Danlos syndrome, treatment with celiprolol should be considered to prevent dissections and arterial ruptures	IIa	B	283
Recommendation 68			
Patients with Loeys-Dietz and Ehlers-Danlos syndromes should be considered for treatment in collaboration with highly specialized referral centres	IIa	C	284
Recommendation 69			
All first degree relatives of patients considered to be part of a familial aneurysm disorder may be considered for screening with imaging for descending thoracic aortic and abdominal aortic aneurysms at the age of 50, repeated thereafter at regular intervals	IIb	C	62
Recommendation 70			
Reproductive health counselling by genetic specialists should be offered to patients diagnosed with any genetic connective tissue disorder	I	C	271,272,278,279
Recommendation 71			
Women with a confirmed genetic connective tissue disorder should be advised regarding the relative risks of pregnancy to both mother and foetus	I	C	277,286,287
Recommendation 72			
In patients with genetic syndromes associated with thoracic aortic aneurysm dilatation ≥ 50 mm, surgery should be considered	IIa	C	
Recommendation 73			
In patients with a genetic syndrome and enlarged aortic diameter < 50 mm, surgery may be considered according to body surface area in patients of small stature or for rapid progression or more aggressive diseases or with a family history of dissection	IIb	C	281
Recommendation 74			
In patients with connective tissue disorder, endovascular repair may be considered in redo operations or in emergencies as bridging procedures	IIb	C	193,285

peripheral vascular disease. The diagnosis is most often made after surgery or at autopsy. Most of the cases described in the literature are sarcomas and malignant fibrous histiocytomas.²⁹¹ Aortic angiosarcomas occur more often in the DTA.

A clinico-pathological classification of aortic tumours categorizes the lesions as intimal or mural (obstructive and non-obstructive).²⁹² Intraluminal tumours often give rise to thromboembolism, whereas those arising from the media and adventitia form aggressive mass lesions, which may have intra- and extra-luminal extension. Clinical presentation and imaging findings are often non-specific. Symptoms are typically the result of tumour embolisation, local mass effect, or luminal obstruction causing claudication or secondary hypertension in the case of renal stenosis.²⁹²

Making a diagnosis is challenging. Aortic sarcomas can easily be confused with aneurysmal disease or atherosclerotic aorto-iliac occlusive disease. The diagnosis may be based on a high index of suspicion and is generally confirmed by fluorodeoxyglucose/positron emission tomography/CT (FDG PET/CT), which shows increased uptake at the location of the tumour,²⁹³ and biopsy.

Evidence regarding the therapeutic management of aortic tumours shows poor outcomes. Survival in patients with malignant tumours has been very poor, whether or not they tolerate surgical resection. Five year survival is reported at 12% after surgical intervention, and only 8% after conservative treatment.²⁹⁴

Endovascular repair is not recommended. Stent grafts do not preclude the growth and metastatic potential of

neoplastic lesions despite angiographic exclusion.²⁹⁵ Endovascular exclusion can be offered only for compassionate use when repetitive tumour embolic events occur.

3.7.3. Floating thrombus. Floating thrombus is defined as the presence of mobile thrombus in the DTA that may be a potential source of life threatening peripheral arterial emboli to visceral organs or the lower limbs. This condition may be related to a previously injured aortic wall (dissection, atherosclerosis, or trauma).

A floating thrombus in a healthy thoracic aorta is a rare event, and is commonly associated with an underlying thrombophilia. In many cases the pathophysiology/aetiology remains unknown.

Prompt diagnosis and treatment are necessary to avoid severe complications. The diagnosis of floating thoracic aortic thrombus is usually made after debilitating embolic events. TOE represents the non-invasive study of choice to first exclude a cardioembolic source, while also providing a good view of the distal arch and DTA. CTA and MRA can provide additional and more detailed information.^{296,297}

The treatment strategy for this disease remains controversial and is determined by the location and extension of the thrombus, presence of complications, the patient's comorbidities, and the physician's preferences. Options include anticoagulant therapy, aspiration thrombectomy, surgical thrombectomy, or endovascular repair by covered stent deployment.²⁹⁶

If anticoagulation is selected, a size reduction of thrombus should be observed in a short time and heparin treatment must be maintained or switched to oral anticoagulation until the thrombus is completely dissolved. When no reduction in thrombus size is observed, or if the thrombus appears mobile within the aortic lumen, a more aggressive treatment strategy should be recommended. The benefits of an OR approach with thoracic aortic thrombectomy are debatable, as the operative risk is disproportionately high relative to the potential benefit. Moreover, the risk of a medical treatment failure leading to repeated embolism is undetermined, with a few reports demonstrating complete thrombus dissolution with anticoagulation alone.²⁹⁷ On the other hand, early intervention with thoracic aortic thrombectomy has been shown to prevent fatal recurrent embolic events.²⁹⁶

Less invasive surgical approaches have been proposed, including TOE guided trans-aortic and trans-femoral balloon thrombectomy, percutaneous catheter thrombo-aspiration, and TOE guided thrombus exclusion using endovascular covered stents.²⁹⁸ Endovascular exclusion of the thrombus from the systemic circulation by stent graft deployment is certainly an attractive approach in high risk surgical patients with favourable anatomy, although the possibility of thrombus fragmentation and dislodgement by catheter manipulation should also be considered.

Follow up must include long-term anticoagulant therapy and routine surveillance using TOE or CTA or MRI until all

thrombus has disappeared, as the long-term outcome remains uncertain.

4. SURVEILLANCE

To prevent complications and ascertain therapeutic efficacy, it is suggested that all patients diagnosed with or treated for DTA disease should undergo a strict programme of systematic surveillance. Successful management and outcomes are dependent not only on the initial treatment, but also on adequate follow up and early diagnosis of complications. Although the therapeutic options differ among the various DTA diseases, patient surveillance follows a similar protocol (Fig. 3A and 3B, Table 3). These surveillance intervals are based on several reported experiences, as no definitive evidence exists.^{44,65,85,88,107,108,129,168,173,299}

All patients with DTA disease require aggressive management of hypertension, secondary prevention of cardiovascular diseases, and close follow up to monitor the evolution of the diseased aorta. In particular, conservatively treated patients are prone to develop progression of disease¹⁹⁵ and OR patients can develop anastomotic pseudoaneurysm, new para-anastomotic aneurysms, graft infection or graft occlusion.²⁹⁹ TEVAR may result in stent graft related complications such as endoleak, stent graft migration, or stent graft collapse.^{106,107} The primary importance of the surveillance protocols is to prevent these complications.

CTA is the modality most often used for follow up in DTA disease. ECG-gated CTAs have greatly improved imaging quality by eliminating pulsation artefacts. This imaging modality may identify subtle aortic characteristics such as the primary intimal tear in TBAD and ulcerative plaques in PAU (see also Section 2.3.5.). An excellent assessment of the vessel wall and aortic lumen, including the surrounding anatomy is derived from multiplanar imaging, three dimensional reconstruction and centre lumen line reconstruction.^{20,21}

However, cumulative lifetime radiation exposure caused by multiple CTA examinations must be taken into account during planning of follow up. In addition, iodinated intravenous contrast agents are associated with nephrotoxic effects. MRI can be used to avoid radiation and iodinated contrast media.³⁰⁰ MRI compatible stent grafts are a prerequisite, as the presence of stainless steel implants causes artefacts. In patients treated with thoracic aortic endografts, conventional chest X-rays can show stent graft migration, collapse, or fracture. This is especially true regarding follow up after TAI repair. Given the generally young age of this subgroup of patients, concerns arise with regard to the cumulative radiation and iodinated contrast exposure required for long-term follow up. For these reasons, MRA may also be used for surveillance when magnetic resonance compatible stent grafts are employed.¹⁶⁶ Therefore, it seems reasonable to adopt a combination of a multi-view chest X-rays and MRA instead of CTA for long-term imaging of these patients.¹⁵¹

In patients with inflammatory disease, infectious/inflammatory activity can be visualized and followed using

nuclear imaging with 18-fluorodeoxyglucose (FDG) positron emission tomography (PET), or gallium 67 (67GA).³⁰¹ In suspected aortic graft infection, the diagnostic performance of FDG-PET is superior to that of CTA and is recommended in certain situations.³⁰¹ Because these modalities do not provide any morphological characteristics of the aorta, they need to be combined with CTA or MRI. Additional oesophagoscopy and bronchoscopy may be required in evaluation of aorto-bronchial and/or aorto-oesophageal fistulae.

In patients with ATBAD managed medically, progressive aneurysmal dilatation can develop over time.¹⁸⁹ This dilatation may eventually lead to rupture and sudden death during the chronic phase.¹⁷³ In ATBAD, some predictors of aortic growth, like the entry tear size and partial FL thrombosis, are now identified.^{168,174} Patients with chronic TBAD may develop progression of the initial dissection or a secondary aortic dissection event like intramural haematoma. In addition, in ATBAD patients treated with TEVAR, distal perfusion of the FL is often observed, and its role remains poorly understood.¹⁹¹

Therefore, routine surveillance should consist of physical examination, blood pressure control, and echocardiography, and mainly be done with MRA or CTA, based on patient characteristics (see also Table 3).

The natural history of both PAU and IMH is unclear and patients with these conditions should have a close surveillance protocol. Morphological changes can develop over time,^{7,12,121} and patients with IMH and PAU

should have the same surveillance programme as those with AD.

In patients with DTAA or TAAAs, surveillance after initial detection is similar to that for other DTA diseases (Table 3). In this setting, the level of evidence remains low, despite the higher incidence of aneurysms and experience reported in the literature. In conservatively managed patients, the mean aortic growth is about 1 mm/year, and is more prominent in the DTA in which growth has been reported to be 1.9 mm/year.⁶⁵ Other factors influencing aortic growth are initial diameter and the presence of connective tissue disorders. Surveillance of patients diagnosed with aneurysms will consist of imaging studies after 6 and 12 months, and yearly thereafter. For small and stable aneurysms, the surveillance interval can be reduced to every 2–3 years (Table 5).

The surveillance of patients with thoracic aortic coarctation should include an annual clinical evaluation (blood pressure in upper and lower limbs) by the cardiologist combined with echocardiography and additional aortic imaging when indicated. Although uncommon, pregnant patients with coarctation should be monitored carefully to prevent complications. After coarctation repair, by surgery, TEVAR, or balloon angioplasty, regular follow up examination is mandatory. Long-term complications may occur, especially when the intervention has been performed in neonates. It is imperative to minimise radiation, as the patient population can be relatively young. MRI, which is the most cost effective imaging modality, should be

Table 5. Suggested disease specific follow up protocol for conservative management.

	Modalities	Interval	Indications for closer follow up or potential intervention
ATBAD	CT or MRI	3 m, 6 m, yearly In stable condition after 3 years follow up, the interval can be extended to 2–3 years	Aortic growth >5 mm/year Aortic diameter >50 mm
IMH	CT or MRI	3 m, 6 m, yearly In stable condition after 3 years follow up, the interval can be extended to 2–3 years	Extension of IMH Presence of concomitant PAU Aortic growth >5 mm/year Aortic diameter >50 mm
PAU	CT or MRI	3 m, 6 m, yearly In stable condition after 3 years follow up, the interval can be extended to 2–3 years	
Thoracic aortic aneurysm	CT or MRI	6 m, 12 m, yearly In stable condition after 3 years follow up, the interval can be extended to 2–3 years	Aortic growth >5 mm/year Aortic diameter >50 mm
Thoraco-abdominal aneurysm	CT or MRI	6 m, 12 m, yearly In stable condition after 3 years follow up, the interval can be extended to 2–3 years	Aortic growth >5 mm/year Aortic diameter >55 mm
Inflammatory disease	CT or MRI, combined with PET Blood tests: white cell count, CRP	3 m, 6 m, yearly	
Thoracic coarctation	CT or MRI	On clinical indication	
Aortic disease with connective tissue disorders	CT or MRI	3 m, 6 m, yearly	Aortic diameter >45 mm Aortic growth >5 mm/year

adopted routinely as the follow up screening test of choice.³⁰² More recently, a non-invasive method based on computational fluid dynamics and MR imaging, has been proposed to estimate the pre- and post-operative haemodynamics for both native and recurrent coarctation patients.³⁰³

In all patients with DTA diseases managed by OR, follow up is similar (see Fig. 4). After a 6 month post-operative CT scan, patients should have yearly CTA or MRI examinations. The interval between scans may be lengthened after 3 years of complication-free follow up.

TEVAR requires more intensive surveillance compared with open treatment, because of potential stent graft related complications such as endoleak, migration, and collapse. Detection of type I and III endoleaks requires prompt intervention, as does stent graft migration or collapse. Type II and IV endoleaks may be followed by serial CTA/MRI^{187,304} (see Fig. 5).

Randomized studies often yield conflicting results because of technical evolution and growth in the participants' experience. These overall guidelines include this section to identify the most relevant gaps in the evidence.

5.1. General aspects

- 5.1.1. The value of glucocorticosteroids, mannitol, and intrathecal techniques to prevent spinal cord ischaemia needs clinical data to be definitively adopted or rejected for clinical practice during OR of DTA.
- 5.1.2. The value of MEP and SSEP in patients treated with TEVAR is not clearly supported by clinical data.
- 5.1.3. The optimal brain protection strategy in patients requiring open or endovascular repair for thoracic aortic disease needs to be defined.

Recommendation 75	Class	Level of evidence	References
Computed tomographic aortography should be considered the first option for imaging surveillance in the acute setting of patients with thoracic aortic diseases	IIa	C	20
Recommendation 76			
Magnetic resonance imaging should be considered as an imaging modality to follow up patients with aortic endografts	IIa	C	300
Recommendation 77			
In patients diagnosed with type B aortic dissection, penetrating aortic ulcer, or intramural haematoma, routine surveillance should be considered including physical examination, echocardiography and imaging with magnetic resonance angiography or computed tomographic aortography	IIa	C	19,121,173,189
Recommendation 78			
For patients treated with endografts life-long imaging follow up with magnetic resonance angiography or computed tomographic aortography should be considered	IIa	C	187
Recommendation 79			
Any early or late type I or III endoleak after an endovascular repair of the descending thoracic aorta should undergo prompt intervention	I	C	187,304
Recommendation 80			
In patients with DTA pathology managed by open repair, follow up imaging after 6 months with computed tomography should be performed	I	C	129, 299

5. GAPS IN THE EVIDENCE

Robust evidence is still needed in many aspects of the management of DTA pathologies. In numerous clinical scenarios, adequate trials are lacking. In addition, because of continuous technical innovation in endovascular repair, clinical practice tends to follow technical developments without robust evidence from randomized trials.

5.2. Acute type B dissection

- 5.2.1. TEVAR indications for uncomplicated ATBAD need to be elucidated by prospective and randomized studies.
- 5.2.2. It would be useful to define early unfavourable clinical and imaging signs and biomarkers as

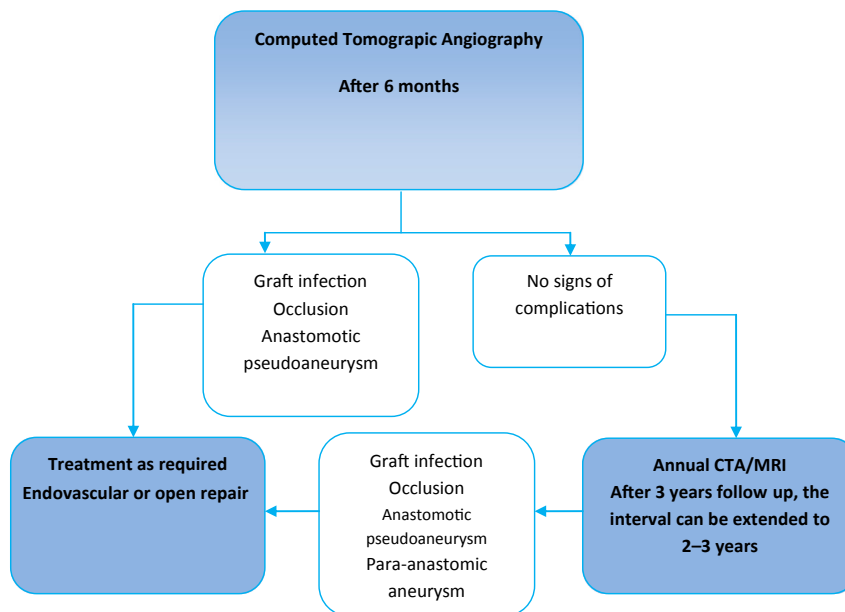


Figure 4. Suggested surveillance algorithm after open repair.

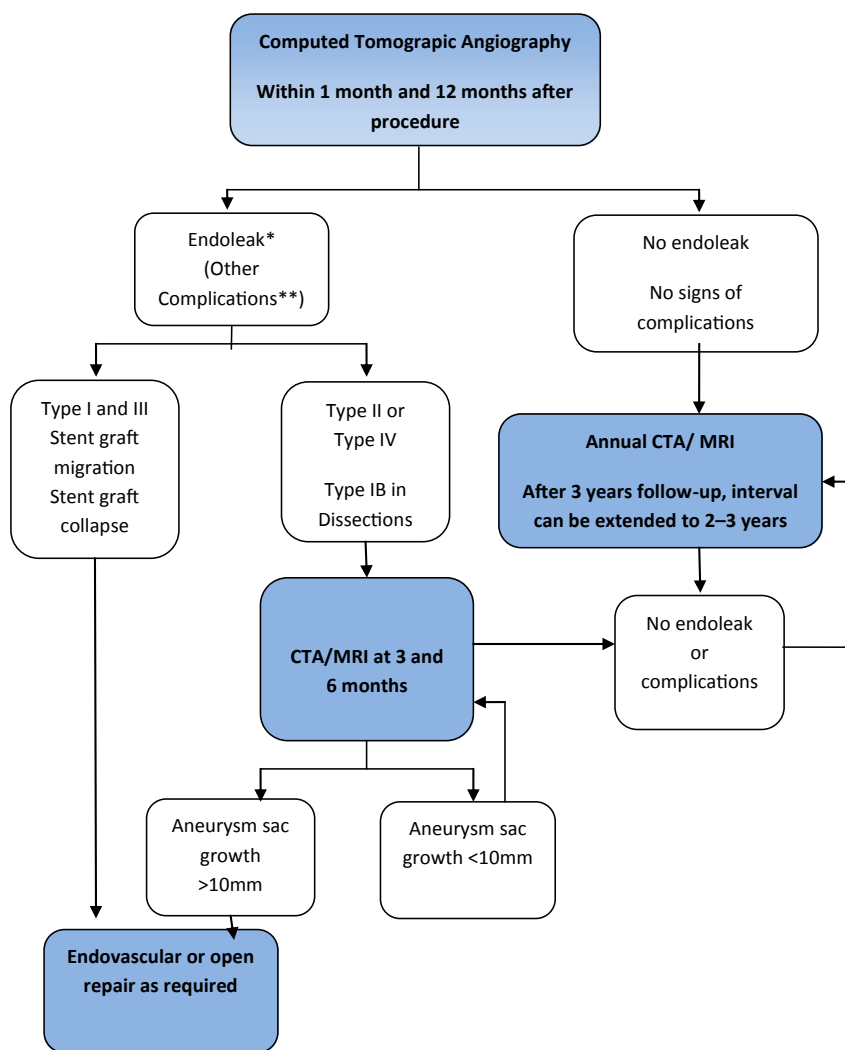


Figure 5. Suggested surveillance algorithm after TEVAR. *Endoleak types: type I, direct flow between endograft and aortic wall in the proximal (type Ia) or distal sealing zone (type Ib); type II, blood flow in the aneurysm sac, originating from side branches; type III, direct flow coming from overlapped segments or through a defect of the stent graft fabric; type IV, blood flow into the aneurysm sac because of the porosity of the graft fabric. ** Other complications should be managed accordingly.

predictive factors to identify patients who can benefit the most from thoracic endografting.

5.3. Thoracic aortic rupture

5.3.1. There is no level A or B evidence for the best method of repair of ruptured thoracic aortic aneurysms. A few non-consecutive studies report endovascular techniques and compare these with earlier reports using OR (level C). Intuitively, sealing an anatomically suitable ruptured thoracic aneurysm via a femoral approach with a stent graft without opening the chest must put the patient at lower risk, and there will therefore never be a randomized trial to compare the two modalities. In addition, the number of affected patients is too small to support a randomized trial and patients are very difficult to recruit.

5.4. Blunt traumatic thoracic aortic injury

5.4.1. A randomized clinical trial is not justified to elucidate the benefit of TEVAR over OR in the acute setting.

5.4.2. No evidence supports the choice between open and endovascular repair for chronic post-traumatic pseudoaneurysms.

5.4.3. More information about the natural history of chronic post-traumatic pseudoaneurysms is needed. No clear criteria for repair have been described. The protective role of severe calcification remains uncertain.

5.4.4. A follow up programme for patients who have been treated by TEVAR for TAI needs to be established.

5.5. Chronic type B dissection

5.5.1. The advent of endovascular repair suggests that TBAD may require an additional classification with respect to chronicity. A sub-category of sub-acute dissection may reflect the ability of the aorta to remodel between 2 and 12 weeks after the initial dissection. Further evidence of aortic remodelling after TEVAR and the natural history of sub-acute dissection is required.

5.5.2. There is a lack of natural history data relating to CTBAD in the era of modern medical therapy. Data are required to define the incidence of aortic related events, aortic growth rates, and FL thrombosis rates. These data may inform the threshold and indications for interventional therapy. At present there are no conclusive data to establish diameter thresholds for repair of TBAD.

5.5.3. The natural history of CTBAD may be related to morphological features that could be defined with newer imaging techniques such as 4D MRA. Research is awaited.

5.5.4. There is a lack of distinct evidence regarding early outcomes following repair of CTBAD — either open or endovascular. At present most data relate to a mixture of thoracic pathologies and more homogenous data series are required. There are only a few series detailing the ability of OR to prevent aortic related death in the mid- and long-term. There are very few series detailing the ability of TEVAR to prevent aortic related death in the mid- and long-term.

5.6. Descending thoracic aortic aneurysm

5.6.1. Intervention in DTAA <55 mm may not afford a survival benefit. Outcomes of intervention need to be exceptional to justify repair in the small aneurysm group. The advent of TEVAR justifies a randomized prospective trial for small DTAA to compare early TEVAR and surveillance only.

5.6.2. Long-term durability of thoracic endografting, especially for DTAA repair, is not well determined. More data are needed from case series and case control studies to elucidate the late complications and re-intervention rate beyond 5 years follow up.

5.7. Thoraco-abdominal aneurysm

5.7.1. There is no level A or B evidence on the best method of repair for elective TAAA.

5.8. Inflammatory diseases

5.8.1. A very low level of evidence is available for determining indications for treating inflammatory disease of the thoracic aorta. The same indications are recommended as for elective repair of any thoracic aortic disease, based on the risk of rupture related to aneurysm dimension and the presence of secondary end organ ischaemia. This is level C evidence.

5.8.2. There is very poor evidence to support any specific follow up regimen after surgical or endovascular repair of cardiovascular disorders in patients with systemic inflammatory diseases receiving steroid therapy.

5.9. Coarctation

5.9.1. There is no high quality evidence regarding the ideal treatment strategy for native or recurrent coarctation

in adults. No randomized trials have compared open with endovascular strategies and such a comparison is impractical because of the rareness of the disease and constant developments in endovascular technology. Further comparative evidence from case control studies and case series is required. Long-term data regarding durability and late complications following endovascular repair are essential.

- 5.9.2.** Concerning endovascular repair, no high quality evidence supports the routine use of bare or covered stents. A prospective randomized trial could clarify the optimal strategy in patients with native or recurrent coarctation, with attention to the following endpoints: re-stenosis/aneurysm formation at the treatment site, residual hypertension, and progressive left ventricular dysfunction.
- 5.9.3.** Evidence suggests that persistent hypertension after successful repair is a risk factor for premature coronary and carotid obstructive disease, persistent left ventricular function deterioration and increased risk of aortic and cerebral aneurysm rupture. Persistent hypertension may be multifactorial, with abnormal aortic wall compliance and baroreceptor dysfunction as possible causes. Further research on this topic is necessary to clarify the risk benefit of intervention.

5.10. Miscellaneous

- 5.10.1.** No robust evidence is available to support a threshold diameter for treating patients with genetic syndromes associated with thoracic aneurysm (a threshold of ≥ 50 mm is suggested, with a threshold < 50 mm in cases where the rate of growth is > 5 mm per year, or when significant aortic regurgitation or a family history of dissection is present). Unfortunately, the level of evidence for this suggestion cannot be higher than Level C. More and larger series are needed.

5.11. Surveillance

- 5.11.1.** Surveillance intervals are based on several reported experiences, as no evidence is available. This is particularly evident in patients treated for DTAA, in which the level of evidence remains low despite the higher incidence of aneurysms and increasing experience reported in the literature (see also Section 5.8.2.).

ACKNOWLEDGEMENTS

The Writing Committee would like to thank F. Bastos Gonçalves (Netherlands), C. Brinster (Spain), E. Civilini (Italy), G. Coppi (Italy), G. de Donato (Italy), G. Maritati (Italy), G. Mestres (Spain), K. Paraskevas (Greece), F. Pecoraro (Switzerland), and J.L. Tolenaar (Netherlands) for their contribution on preparing and writing this manuscript.

APPENDIX. RECOMMENDED ADDITIONAL REFERENCES

The recommended additional references related to this article can be found online at <http://dx.doi.org/10.1016/j.ejvs.2016.06.005>.

REFERENCES

- 1 European Society of Cardiology. *Recommendations for guidelines production*. www.escardio.org/static_file/Escardio/Guidelines/about/ESC_Guidelines_for_Guidelines_Update_2012_for_web.pdf.
- 2 Johnston KW, Rutherford RB, Tilson MD, Shah DM, Hollier L, Stanley JC. Suggested standards for reporting on arterial aneurysms. Subcommittee on Reporting Standards for Arterial Aneurysms, Ad Hoc Committee on Reporting Standards, Society for Vascular Surgery and North American Chapter, International Society for Cardiovascular Surgery. *J Vasc Surg* 1991;**13**:452–8.
- 3 Kälsch H, Lehmann N, Möhlenkamp S, Becker A, Moebus S, Schmermund A, et al. Body-surface adjusted aortic reference diameters for improved identification of patients with thoracic aortic aneurysms: results from the population-based Heinz Nixdorf Recall study. *Int J Cardiol* 2013;**163**:72–8.
- 4 Clouse WD, Hallet Jr JW, Shaff HV, Spittell PC, Rowland CM, Ilstrup CM, et al. Acute aortic dissection: population-based incidence compared with degenerative aortic aneurysm rupture. *Mayo Clin Proc* 2004;**79**:176–80.
- 5 Landenhed M, Engstrom G, Gottsater A, Caulfield MP, Hedblad B, Newton-Cheh C, et al. Risk profiles for aortic dissection and ruptured or surgically treated aneurysms: a prospective cohort study. *J Am Heart Assoc* 2015;**4**(1):e001513.
- 6 Eggebrecht H, Nienaber CA, Neuhauser M, Baumgart D, Kische S, Schmermund A, et al. Endovascular stent graft placement in aortic dissection: a meta-analysis. *Eur Heart J* 2006;**27**:489–98.
- 7 Evangelista A, Mukherjee D, Mehta RH, O’Gara PT, Fattori R, Cooper JV, et al. Acute intramural hematoma of the aorta: a mystery in evolution. *Circulation* 2005;**111**:1063–70.
- 8 http://ec.europa.eu/eurostat/statistics-explained/index.php/Transport_accident_statistics#Main_statistical_findings.
- 9 European Commission. *Mobility and transport. Road safety*. http://ec.europa.eu/transport/road_safety/specialist/statistics/.
- 10 Johansson G, Markström U, Swedenborg J. Ruptured thoracic aortic aneurysms: a study of incidence and mortality rates. *J Vasc Surg* 1995;**21**:985–8.
- 11 Fowkes FG, Macintyre CC, Ruckley CV. Increasing incidence of aortic aneurysms in England and Wales. *BMJ* 1989;**298**:33–5.
- 12 Karageorgaki ZT, Bertias GK, Mavragani CP, Kritikos HD, Spyropoulou-Vlachou M, Drosos AA, et al. Takayasu arteritis: epidemiological, clinical, and immunogenetic features in Greece. *Clin Exp Rheumatol* 2009;**27**(Suppl. 52):S33–9.

- 13 Nordborg E, Nordborg C. Giant cell arteritis: epidemiological clues to its pathogenesis and an update on its treatment. *Rheumatology* 2003;**42**:413–21.
- 14 Lee JL, Naguwa SM, Cheema GS, Gershwin ME. The geo-epidemiology of temporal (giant cell) arteritis. *Clin Rev Allergy Immunol* 2008;**35**:88–95.
- 15 Idil A, Gurler A, Boyvat A, Caliskan D, Ozdemir O, Isik A, et al. The prevalence of Behcet's disease above the age of 10 years. The results of a pilot study conducted at the Park Primary Health Care Center in Ankara, Turkey. *Ophthalmic Epidemiol* 2002;**9**:325–31.
- 16 Teo LL, Cannell T, Babu-Narayan SV, Hughes M, Mohiaddin RH. Prevalence of associated cardiovascular abnormalities in 500 patients with aortic coarctation referred for cardiovascular magnetic resonance imaging to a tertiary center. *Pediatr Cardiol* 2011;**32**:1120–7.
- 17 Goldstein SA, Evangelista A, Abbara S, Arai A, Asch FM, Badano LP, et al. Multimodality imaging of diseases of the thoracic aorta in adults: from the American Society of Echocardiography and the European Association of Cardiovascular Imaging. *J Am Soc Echocardiogr* 2015;**28**:119–82.
- 18 Klompas M. Does this patient have an acute thoracic aortic dissection? *J Am Med Assoc* 2002;**287**:2262–72.
- 19 Evangelista A, Flachskampf FA, Erbel R, Antonini-Canterin F, Vlachopoulos C, Rocchi G, et al. Echocardiography in aortic diseases: EAE recommendations for clinical practice. *Eur J Echocardiogr* 2010;**11**:645–58.
- 20 Parodi J, Berguer R, Carrascosa P, Khanafer K, Capunay C, Wizauer E. Sources of error in the measurement of aortic diameter in computed tomography scans. *J Vasc Surg* 2014;**59**(1):74–9.
- 21 Wicky S, Wintermark M, Schnyder P, Capasso P, Denys A. Imaging of blunt chest trauma. *Eur Radiol* 2000;**10**:1524–38.
- 22 Ad-hoc Working Group of ERBP, Fliser D, Laville M, Covic A, Fouque D, Vanholder R, Juillard L, et al. A European Renal Best Practice (ERBP) position statement on the Kidney Disease Improving Global Outcomes (KDIGO) clinical practice guidelines on acute kidney injury: part 1: definitions, conservative management and contrast-induced nephropathy. *Nephrol Dial Transplant* 2012;**27**:4263–72.
- 23 François CJ, Markl M, Schiebler ML, Niespodzany E, Landgraf BR, Schlensak C. Four-dimensional, flow-sensitive magnetic resonance imaging of blood flow patterns in thoracic aortic dissections. *J Thorac Cardiovasc Surg* 2013;**145**:1359–66.
- 24 Wang Y, Alkasab TK, Narin O, Nazarian RM, Kaewlai R, Kay J, et al. Incidence of nephrogenic systemic fibrosis after adoption of restrictive gadolinium-based contrast agent guidelines. *Radiology* 2011;**260**:105–11.
- 25 Walter MA, Melzer RA, Schindler C, Muller-Brand J, Tyndall A, Nitzsche EU. The value of [18F]FDG-PET in the diagnosis of large-vessel vasculitis and the assessment of activity and extent of disease. *Eur J Nucl Med Mol Imaging* 2005;**32**:674–81.
- 26 Litmanovich DE, Yöldöröm A, Bankier AA. Insights into imaging of aortitis. *Insights Imaging* 2012;**3**:545–60.
- 27 Huang B, Law MW, Khong PL. Whole-body PET/CT scanning: estimation of radiation dose and cancer risk. *Radiology* 2009;**251**:166–74.
- 28 Svensson LG, Crawford ES, Hess KR, Coselli JS, Safi HJ. Experience with 1509 patients undergoing thoracoabdominal aortic operations. *J Vasc Surg* 1993;**17**:357–68.
- 29 Coselli JS, LeMaire SA, Koksoy C, Schmittling ZC, Curling PE. Cerebrospinal fluid drainage reduces paraplegia after thoracoabdominal aortic aneurysm repair: results of a randomized clinical trial. *J Vasc Surg* 2002;**35**:631–9.
- 30 Jacobs MJ, Mess W, Mochtar B, Nijenhuis RJ, Stadius van Eps RG, Schurink GW. The value of motor evoked potentials in reducing paraplegia during thoracoabdominal aneurysm repair. *J Vasc Surg* 2006;**43**:239–46.
- 31 Goldstein LJ, Davies RR, Rizzo JA, Davila JJ, Cooperberg MR, Shaw RK. Stroke in surgery of the thoracic aorta: incidence, impact, etiology, and prevention. *J Thorac Cardiovasc Surg* 2001;**122**:935–45.
- 32 Galla JD, Ergin MA, Lansman SL, McCullough JN, Nguyen KH, Spielvogel D. Use of somatosensory evoked potentials for thoracic and thoracoabdominal aortic resections. *Ann Thorac Surg* 1999;**67**:1947–52.
- 33 Guerit JM, Witdoeck C, Verhelst R, Matta AJ, Jacquet LM, Dion RA. Sensitivity, specificity, and surgical impact of somatosensory evoked potentials in descending aorta surgery. *Ann Thorac Surg* 1999;**67**:1943–6.
- 34 de Haan P, Kalkman CJ. Spinal cord monitoring: somatosensory- and motor-evoked potentials. *Anesthesiol Clin North America* 2001;**19**:923–45.
- 35 Estrera AL, Miller 3rd CC, Huynh TT, Porat E, Safi HJ. Neurologic outcome after thoracic and thoracoabdominal aortic aneurysm repair. *Ann Thorac Surg* 2001;**72**:1225–30.
- 36 Nijenhuis RJ, Jacobs MJ, Schurink GW, Kessels AGH, Van Engelshoven JMA, Backes WH. Comparison of magnetic resonance with computed tomography angiography for preoperative localization of the Adamkiewicz artery in thoracoabdominal aortic aneurysm patients. *J Vasc Surg* 2007;**45**:677–85.
- 37 Khan SN, Stansby G. Cerebrospinal fluid drainage for thoracic and thoracoabdominal aortic aneurysm surgery. *Cochrane Database Syst Rev* 2012;(10). Art. No.: CD003635. <http://dx.doi.org/10.1002/14651858.CD003635.pub3>.
- 38 Lima B, Nowicki ER, Blackstone EH, Williams SJ, Roselli EE, Sabik JF, et al. Spinal cord protective strategies during descending and thoracoabdominal aortic aneurysm repair in the modern era: the role of intrathecal papaverine. *J Thorac Cardiovasc Surg* 2012;**143**:945–52.
- 39 Wynn MM, Mell MW, Tefera G, Hoch JR, Acher CW. Complications of spinal fluid drainage in thoracoabdominal aortic aneurysm repair: a report of 486 patients treated from 1987 to 2008. *J Vasc Surg* 2009;**49**:29–34.
- 40 Coselli JS. The use of left heart bypass in the repair of thoracoabdominal aortic aneurysms: current techniques and results. *Semin Thorac Cardiovasc Surg* 2003;**15**:326–32.
- 41 Kulik A, Castner CF, Kouchoukos NT. Outcomes after thoracoabdominal aortic aneurysm repair with hypothermic circulatory arrest. *J Thorac Cardiovasc Surg* 2011;**141**:953–60.
- 42 Svensson LG, Khitin L, Nadolny EM, Kimmel WA. Systemic temperature and paralysis after thoracoabdominal and descending aortic operations. *Arch Surg* 2003;**138**:175–9.
- 43 de Haan P, Kalkman CJ, Jacobs MJ. Pharmacologic neuroprotection in experimental spinal cord ischaemia: a systematic review. *J Neurosurg Anesthesiol* 2001;**13**:3–12.
- 44 Buth J, Harris PL, Hobo R, van Eps R, Cuyppers P, Duijlm L, et al. Neurologic complications associated with endovascular repair of thoracic aortic pathology: incidence and risk factors. a study from the European Collaborators on Stent/Graft Techniques for Aortic Aneurysm Repair (EUROSTAR) registry. *J Vasc Surg* 2007;**46**:1103–10.
- 45 Khoynezhad A, Donayre CE, Bui H, Kopchok GE, Walot I, White RA. Risk factors of neurologic deficit after thoracic aortic endografting. *Ann Thorac Surg* 2007;**83**:S882–9.

- 46 Amabile P, Grisoli D, Giorgi R, Bartoli JM, Piquet P. Incidence and determinants of spinal cord ischaemia in stent graft repair of the thoracic aorta. *Eur J Vasc Endovasc Surg* 2008;**35**:455–61.
- 47 Schlösser FJ, Verhagen HJ, Lin PH, Verhoeven EL, van Herwaarden JA, Moll FL, et al. TEVAR following prior abdominal aortic aneurysm surgery: increased risk of neurological deficit. *J Vasc Surg* 2009;**49**:308–14.
- 48 Maldonado TS, Dexter D, Rockman CB, Veith FJ, Garg K, Arko F, et al. Left subclavian artery coverage during thoracic endovascular aortic aneurysm repair does not mandate revascularisation. *J Vasc Surg* 2013;**57**:116–24.
- 49 Matsumura JS, Lee WA, Mitchell RS, Farber MA, Murad MH, Lumsden AB, et al. The Society for Vascular Surgery Practice Guidelines: management of the left subclavian artery with thoracic endovascular aortic repair. *J Vasc Surg* 2009;**50**:1155–8.
- 50 Rizvi AZ, Murad MH, Fairman RM, Erwin PJ, Montori VM. The effect of left subclavian artery coverage on morbidity and mortality in patients undergoing endovascular thoracic aortic interventions: a systematic review and meta-analysis. *J Vasc Surg* 2009;**50**:1159–69.
- 51 Vilacosta I, Aragoncillo P, Cañadas V, San Román JA, Ferreirós J, Rodríguez E. Acute aortic syndrome: a new look at an old conundrum. *Heart* 2009;**95**:1130–9.
- 52 Mackenzie KS, LeGuillan MP, Steinmetz OK, Montreuil B. Management trends and early mortality rates for acute type B aortic dissection: a 10 year single-institution experience. *Ann Vasc Surg* 2004;**18**:158–66.
- 53 Daily PO, Trueblood HW, Stinson EB, Wuerflein RD, Shumway NE. Management of acute aortic dissections. *Ann Thorac Surg* 1970;**10**:237–47.
- 54 Hiratzka LF, Bakris GL, Beckman JA, Bersin RM, Carr VF, Casey Jr DE, et al. American College of Cardiology Foundation/American Heart Association Task Force on Practice Guidelines; American Association for Thoracic Surgery; American College of Radiology; American Stroke Association; Society of Cardiovascular Anesthesiologists; Society for Cardiovascular Angiography and Interventions; Society of Interventional Radiology; Society of Thoracic Surgeons; Society for Vascular Medicine. 2010 ACCF/AHA/AATS/ACR/ASA/SCA/SCAI/SIR/STS/SVM guidelines for the diagnosis and management of patients with Thoracic Aortic Disease: a report of the American College of Cardiology Foundation/American Heart Association Task Force on Practice Guidelines, American Association for Thoracic Surgery, American College of Radiology, American Stroke Association, Society of Cardiovascular Anesthesiologists, Society for Cardiovascular Angiography and Interventions, Society of Interventional Radiology, Society of Thoracic Surgeons, and Society for Vascular Medicine. *Circulation* 2010;**121**:e266–369.
- 55 Hagan PG, Nienaber CA, Isselbacher EM, Bruckman D, Karavite DJ, Russman PL, et al. The International Registry of Acute Aortic Dissection (IRAD): new insights into an old disease. *J Am Med Assoc* 2000;**283**:897–903.
- 56 Tsai TT, Trimarchi S, Nienaber CA. Acute aortic dissection: perspectives from the International Registry of Acute Aortic Dissection (IRAD). *Eur J Vasc Endovasc Surg* 2009;**37**:149–59.
- 57 Collins JS, Evangelista A, Nienaber CA, Bossone E, Fang J, Cooper JV, et al. Differences in clinical presentation, management, and outcomes of acute type a aortic dissection in patients with and without previous cardiac surgery. *Circulation* 2004;**110**(Suppl. 1):II237–42.
- 58 Bonderman D, Gharehbaghi-Schnell E, Wollenek G, Maurer G, Baumgartner H. Mechanisms underlying aortic dilatation in congenital aortic valve malformation. *Circulation* 1999;**99**:2138–43.
- 59 Eagle KA, Isselbacher EM, DeSanctis RW. Cocaine-related aortic dissection in perspective. *Circulation* 2002;**105**:1529–30.
- 60 Suzuki T, Mehta RH, Ince H, Nagai R, Sakomura Y, Weber F, et al. Clinical profiles and outcomes of acute type B aortic dissection in the current era: lessons from the International Registry of Aortic Dissection (IRAD). *Circulation* 2003;**108**(Suppl. 1):II312–7.
- 61 Hatzaras IS, Bible JE, Koullias GJ, Tranquilli M, Singh M, Elefteriades JA, et al. Role of exertion or emotion as inciting events for acute aortic dissection. *Am J Cardiol* 2007;**100**:1470–2.
- 62 Albornoz G, Coady MA, Roberts M, Davies RR, Tranquilli M, Rizzo JA, et al. Familial thoracic aortic aneurysms and dissections – incidence, modes of inheritance, and phenotypic patterns. *Ann Thorac Surg* 2006;**82**:1400–5.
- 63 Hasham SN, Willing MC, Guo DC, Muilenburg A, He R, Tran VT, et al. Mapping a locus for familial thoracic aneurysms and dissections (TAAD2) to 3p24–25. *Circulation* 2003;**107**:3184–90.
- 64 Renard M, Callewaert B, Baetens M, Campens L, Macdermot K, Fryns JP, et al. Novel MYH11 and ACTA2 mutations reveal a role for enhanced TGF β signaling in FTAAD. *Int J Cardiol* 2013;**165**:314–21.
- 65 Elefteriades JA. Natural history of thoracic aortic aneurysms: indications for surgery, and surgical versus nonsurgical risks. *Ann Thorac Surg* 2002;**74**:S1877–80.
- 66 Trimarchi S, Jonker FH, Froehlich JB, Upchurch GR, Moll FL, Muhs BE, et al. Descending aortic diameter of 5.5 cm or greater is not an accurate predictor of acute type B aortic dissection. *J Thorac Cardiovasc Surg* 2011;**142**:e101–7.
- 67 Trimarchi S, Jonker FH, Froehlich JB, Upchurch GR, Moll FL, Muhs BE, et al. International Registry of Acute Aortic Dissection (IRAD) Investigators. Acute type B aortic dissection in the absence of aortic dilatation. *J Vasc Surg* 2012;**56**:311–6.
- 68 Nallamothu BK, Mehta RH, Saint S, Llovet A, Bossone E, Cooper JV, et al. Syncope in acute aortic dissection: diagnostic, prognostic, and clinical implications. *Am J Med* 2002;**113**:468–71.
- 69 Park SW, Hutchison S, Mehta RH, Isselbacher EM, Cooper JV, Fang J, et al. Association of painless acute aortic dissection with increased mortality. *Mayo Clin Proc* 2004;**79**:1252–7.
- 70 Estrera AL, Miller CC, Goodrick J, Porat EE, Achouh PE, Dhareshwar J, et al. Update on outcomes of acute type B aortic dissection. *Ann Thorac Surg* 2007;**83**:S842–5.
- 71 Trimarchi S, Nienaber CA, Rampoldi V, Myrmet T, Suzuki T, Bossone E, et al. Role and results of surgery in acute type B aortic dissection: insights from the International Registry of Acute Aortic Dissection (IRAD). *Circulation* 2006;**114**(Suppl. 1):I357–64.
- 72 Sakakura K, Kubo N, Ako J, Ikeda N, Funayama H, Hirahara T, et al. Determinants of in hospital death and rupture in patients with a Stanford B aortic dissection. *Circ* 2007;**71**:1521–4.
- 73 Williams DM, Lee DY, Hamilton BH, Marx MV, Narasimham DL, Kazanjian SN, et al. The dissected aorta: part III. Anatomy and radiologic diagnosis of branch-vessel compromise. *Radiology* 1997;**203**:37–44.
- 74 Tshomba Y, Coppi G, Marone EM, Bertoglio L, Kahlberg A, Carlucci M, et al. Diagnostic laparoscopy for early detection of acute mesenteric ischaemia in patients with aortic dissection. *Eur J Vasc Endovasc Surg* 2012;**43**:690–7.

- 75 Born C, Forster A, Rock C, Pfeifer KJ, Rieger J, Reiser MA, et al. A case of an upper gastrointestinal bleeding due to a ruptured dissection of a right aortic arch. *Cardiovasc Intervent Radiol* 2003;**26**:506–9.
- 76 Vedantham S, Picus D, Sanchez LA, Braverman A, Moon MR, Sundt III T, et al. Percutaneous management of ischaemic complications in patients with type-B aortic dissection. *J Vasc Interv Radiol* 2003;**14**:181–94.
- 77 Trimarchi S, Eagle KA, Nienaber CA, Pyeritz RE, Jonker FH, Suzuki T, et al. Importance of refractory pain and hypertension in acute type B aortic dissection: insights from the International Registry of Acute Aortic Dissection (IRAD). *Circulation* 2010;**122**:1283–9.
- 78 Trimarchi S, Tolenaar JL, Tsai TT, Froehlich J, Pegorer M, Upchurch GR, et al. Influence of clinical presentation on the outcome of acute B aortic dissection: evidences from IRAD. *J Cardiovasc Surg (Torino)* 2012;**53**:161–8.
- 79 Suzuki T, Isselbacher EM, Nienaber CA, Pyeritz RE, Eagle KA, Tsai TT, et al. Type-selective benefits of medications in treatment of acute aortic dissection (from the International Registry of Acute Aortic Dissection [IRAD]). *Am J Cardiol* 2012;**109**:122–7.
- 80 Genoni M, Paul M, Jenni R, Graves K, Seifert B, Turina M. Chronic beta blocker therapy improves outcome and reduces treatment costs in chronic type B aortic dissection. *Eur J Cardiothorac Surg* 2001;**19**:606–10.
- 81 Lacro RV, Dietz HC, Sleeper LA, Yetman AT, Bradley TJ, Colan SD, et al. Pediatric Heart Network Investigators. *N Engl J Med* 2014;**371**:2061–71.
- 82 Forteza A, Evangelista A, Sánchez V, Teixidó-Turà G, Sanz P, Gutiérrez L, et al. Efficacy of losartan vs. atenolol for the prevention of aortic dilation in Marfan syndrome: a randomized clinical trial. *Eur Heart J* 2016;**37**:978–85.
- 83 Neal B, MacMahon S, Chapman N. Effects of ACE inhibitors, calcium antagonists, and other blood-pressure-lowering drugs: results of prospectively designed overviews of randomised trials. Blood Pressure Lowering Treatment Trialists' Collaboration. *Lancet* 2000;**356**:1955–64.
- 84 Eggebrecht H, Schermund A, von Birgelen C, Naber CK, Bartel T, Wenzel RR. Resistant hypertension in patients with chronic aortic dissection. *J Hum Hypertens* 2005;**19**:227–31.
- 85 Tsai TT, Fattori R, Trimarchi S, Isselbacher E, Myrmet T, Evangelista A, et al. Long-term survival in patients presenting with type B acute aortic dissection: insights from the International Registry of Acute Aortic Dissection. *Circulation* 2006;**114**:2226–31.
- 86 Cambria RP, Clouse WD, Davison JK, Dunn PF, Corey M, Dorer D, et al. A multicenter clinical trial of endovascular stent graft repair of acute catastrophes of the descending thoracic aorta. *J Vasc Surg* 2009;**50**:1255–64.
- 87 Zeeshan A, Woo EY, Bavaria JE, Fairman RM, Desai ND, Pochettino A, et al. Thoracic endovascular aortic repair for acute complicated type B aortic dissection: superiority relative to conventional OS and medical therapy. *J Thorac Cardiovasc Surg* 2010;**140**(Suppl.):S109–15.
- 88 Svensson LG, Kouchoukos NT, Miller DC, Bavaria JE, Coselli JS, Curi MA, et al. Expert consensus document on the treatment of descending thoracic aortic disease using endovascular stent grafts. *Ann Thorac Surg* 2008;**85**:S1–41.
- 89 Umana JP, Lai DT, Mitchell RS, Moore KA, Rodriguez F, Robbins RC, et al. What is the best treatment for patients with acute type B aortic dissections – medical, surgical, or endovascular stent grafting? *Ann Thorac Surg* 2002;**74**:S1840–3.
- 90 Nienaber CA, Fattori R, Lund G, Dieckmann C, Wolf W, von Kodolitsch Y, et al. Nonsurgical reconstruction of thoracic aortic dissection by stent graft placement. *N Engl J Med* 1999;**340**:1539–45.
- 91 Sayer D, Bratby M, Brooks M, Loftus I, Morgan R, Thompson M. Aortic morphology following endovascular repair of acute and chronic type B aortic dissection: implications for management. *Eur J Vasc Endovasc Surg* 2008;**36**:522–9.
- 92 Verhoye JP, Miller DC, Sze D, Dake MD, Mitchell RS. Complicated acute type B aortic dissection: midterm results of emergency endovascular stent grafting. *J Thorac Cardiovasc Surg* 2008;**136**:424–30.
- 93 Steuer J, Eriksson MO, Nyman R, Bjorck M, Wanhainen A. Early and long-term outcome after thoracic endovascular aortic repair (TEVAR) for acute complicated type B aortic dissection. *Eur J Vasc Endovasc Surg* 2011;**41**:318–23.
- 94 Fattori R, Tsai TT, Myrmet T, Evangelista A, Cooper JV, Trimarchi S, et al. Complicated acute type B dissection: is surgery still the best option?: a report from the International Registry of Acute Aortic Dissection. *JACC Cardiovasc Interv* 2008;**1**:395–402.
- 95 Dake MD, Kato N, Mitchell RS, Semba CP, Razavi MK, Shimono T. Endovascular stent graft placement for the treatment of acute aortic dissection. *N Engl J Med* 1999;**340**:1546–52.
- 96 Parker JD, Golledge J. Outcome of endovascular treatment of acute type B aortic dissection. *Ann Thorac Surg* 2008;**86**:1707–12.
- 97 Xiong J, Jiang B, Guo W, Wang SM, Tong XY. Endovascular stent graft placement in patients with type B aortic dissection: a meta-analysis in China. *J Thorac Cardiovasc Surg* 2009;**138**:865–72.
- 98 Heijmen R, Fattori R, Thompson M, Eggebrecht H, Degriecke I, Nienaber C, et al. Virtue Registry Investigators. The VIRTUE Registry of type B thoracic dissections – study design and early results. *Eur J Vasc Endovasc Surg* 2011;**41**:159–66.
- 99 Lombardi JV, Cambria RP, Nienaber CA, Chiesa R, Toebken O, Lee A, et al. Prospective multicenter clinical trial (STABLE) on the endovascular treatment of complicated type B aortic dissection using a composite device design. *J Vasc Surg* 2012;**55**:629–40.
- 100 Barnes DM, Williams DM, Dasika NL, Patel HJ, Weder AB, Stanley JC, et al. A single center experience treating renal malperfusion after aortic dissection with central aortic fenestration and renal artery stenting. *J Vasc Surg* 2008;**47**:903–10.
- 101 Deeb GM, Patel HJ, Williams DM. Treatment for malperfusion syndrome in acute type A and B aortic dissection: a long-term analysis. *J Thorac Cardiovasc Surg* 2010;**140**(Suppl. 6):S98–100 [discussion S142–S146].
- 102 Midulla M, Renaud A, Martinelli T, Koussa M, Mounier-Vehier C, Prat A, et al. Endovascular fenestration in aortic dissection with acute malperfusion syndrome: immediate and late follow up. *J Thorac Cardiovasc Surg* 2011;**142**(1):66–72.
- 103 Fattori R, Montgomery D, Lovato L, Kische S, Di Eusanio M, Ince H, et al. Survival after endovascular therapy in patients with type B aortic dissection: a report from the International Registry of Acute Aortic Dissection (IRAD). *JACC Cardiovasc Interv* 2013;**6**(8):876–82.

- 104 Brunkwall J, Kasprzak P, Verhoeven E, Heijmen R, Taylor P. the ADSORB Trialists. Endovascular repair of acute uncomplicated aortic type B dissection promotes aortic remodelling: 1 year results of the ADSORB trial. *Eur J Vasc Endovasc Surg* 2014;**48**: 285–91.
- 105 Bockler D, Schumacher H, Ganten M, von Tengg-Kobligk H, Schwarzbach M, Fink C, et al. Complications after endovascular repair of acute symptomatic and chronic expanding Stanford type B aortic dissections. *J Thorac Cardiovasc Surg* 2006;**132**:361–8.
- 106 Kasirajan K, Dake MD, Lumsden A, Bavaria J, Makaroun MS. Incidence and outcomes after infolding or collapse of thoracic stent grafts. *J Vasc Surg* 2012;**55**:652–8.
- 107 Eggebrecht H, Thompson M, Rousseau H, Czerny M, Lonn L, Mehta RH, et al. Retrograde ascending aortic dissection during or after thoracic aortic stent graft placement: insight from the European registry on endovascular aortic repair complications. *Circulation* 2009;**120**(Suppl.):S276–81.
- 108 Dake MD, Thompson M, van Sambeek M, Vermassen F, Morales JP. DEFINE Investigators. DISSECT: a new mnemonic-based approach to the categorisation of aortic dissection. *Eur J Vasc Endovasc Surg* 2013;**46**:175–90.
- 109 Khoynezhad A, Donayre CE, Omari BO, Kopchok GE, Walot I, White RA. Midterm results of endovascular treatment of complicated acute type B aortic dissection. *J Thorac Cardiovasc Surg* 2009;**138**:625–31.
- 110 Coselli JS, LeMaire SA, de Figueiredo LP, Kirby RP. Paraplegia after thoracoabdominal aortic aneurysm repair: is dissection a risk factor? *Ann Thorac Surg* 1997;**63**:28–35.
- 111 Miller DC. Surgical management of acute aortic dissection: new data. *Semin Thorac Cardiovasc Surg* 1991;**3**:225–37.
- 112 Svensson LG, Crawford ES, Hess KR, Coselli JS, Safi HJ. Dissection of the aorta and dissecting aortic aneurysms. Improving early and long-term surgical results. *Circulation* 1990;**82**(Suppl.):IV24–38.
- 113 Trimarchi S, Jonker FH, Muhs BE, Grassi V, Righini P, Upchurch GR, et al. Long-term outcomes of surgical aortic fenestration for complicated acute type B aortic dissections. *J Vasc Surg* 2010;**52**:261–6.
- 114 Coselli JS, LeMaire SA, Conklin LD, Adams GJ. Left heart bypass during descending thoracic aortic aneurysm repair does not reduce the incidence of paraplegia. *Ann Thorac Surg* 2004;**77**:1298–303.
- 115 Bozinovski J, Coselli JS. Outcomes and survival in surgical treatment of descending thoracic aorta with acute dissection. *Ann Thorac Surg* 2008;**85**:965–70.
- 116 Lansman SL, Hagl C, Fink D, Galla JD, Spielvogel D, Ergin MA, et al. Acute type B aortic dissection: surgical therapy. *Ann Thorac Surg* 2002;**74**:S1833–5.
- 117 Nienaber CA, Eagle KA. Aortic dissection: new frontiers in diagnosis and management: part I: from etiology to diagnostic strategies. *Circulation* 2003;**108**:628–35.
- 118 Nienaber CA, Sievers HH. Intramural hematoma in acute aortic syndrome; more than one variant of dissection? *Circulation* 2002;**106**:284–5.
- 119 Evangelista A, Czerny M, Nienaber C, Schepens M, Rousseau H, Cao P, et al. Interdisciplinary expert consensus on management of type B intramural haematoma and penetrating aortic ulcer. *Eur J Cardiothorac Surg* 2015;**47**: 1037–43.
- 120 Ince H, Nienaber CA. Diagnosis and management of patients with aortic dissection. *Heart* 2007;**93**:266–70.
- 121 Nathan DP, Boonn W, Lai E, Wang GJ, Desai N, Woo EY, et al. Presentation, complications, and natural history of penetrating atherosclerotic ulcer disease. *J Vasc Surg* 2012;**55**:10–5.
- 122 von Kodolitsch Y, Csösz SK, Koschyk DH, Schalwat I, Loose R, Karck M, et al. Intramural hematoma of the aorta: predictors of progression to dissection and rupture. *Circulation* 2003;**107**:1158–63.
- 123 Geisbüsch P, Kotelis D, Weber TF, Hyhlik-Dürr A, Kauczor HU, Böckler D. Early and midterm results after endovascular stent graft repair of penetrating aortic ulcers. *J Vasc Surg* 2008;**48**: 1361–8.
- 124 Eggebrecht H, Plicht B, Kahlert P, Erbel R. Intramural hematoma and penetrating ulcers: indications to endovascular treatment. *Eur J Vasc Endovasc Surg* 2009;**38**:659–65.
- 125 Clough RE, Mani K, Lyons OT, Bell RE, Zayed HA, Waltham M, et al. Endovascular treatment of acute aortic syndrome. *J Vasc Surg* 2011;**54**:1580–7.
- 126 Jonker FH, Trimarchi S, Verhagen HJ, Moll FL, Sumpio BE, Muhs BE. Meta-analysis of open versus endovascular repair for ruptured descending thoracic aortic aneurysm. *J Vasc Surg* 2010;**51**:1026–30.
- 127 Jonker FH, Verhagen HJ, Lin PH, Heijmen RH, Trimarchi S, Lee WA, et al. OR versus endovascular repair of ruptured thoracic aortic aneurysms. *J Vasc Surg* 2011;**53**:1210–6.
- 128 Gopaldas RR, Dao TK, LeMaire SA, Huh J, Coselli JS. Endovascular versus open repair of ruptured descending thoracic aortic aneurysms: a nationwide risk-adjusted study of 923 patients. *J Thorac Cardiovasc Surg* 2011;**142**:1010–8.
- 129 Patel HJ, Williams DM, Upchurch Jr GR, Dasika NL, Deeb GM. A 15 year comparative analysis of open and endovascular repair for the ruptured descending thoracic aorta. *J Vasc Surg* 2009;**50**:1265–70.
- 130 Vaghetti M, Palmieri C, Al-Jabri A, Ravani M, Rizza A, Trianni G, et al. Endovascular treatment of acute thoracic aortic syndromes with a proximal zone extension strategy: procedural and follow up results. *J Invasive Cardiol* 2011;**23**:187–92.
- 131 Pecoraro F, Pfammatter T, Mayer D, Frauenfelder T, Papadimitriou D, Hechelh, et al. Multiple periscope and chimney grafts to treat ruptured thoracoabdominal and pararenal aortic aneurysms. *J Endovasc Ther* 2011;**18**:642–9.
- 132 Burkhart HM, Gomez GA, Jacobson LE, Pless JE, Broadie TA. Fatal blunt aortic injuries: a review of 242 autopsy cases. *J Trauma* 2001;**50**:113–5.
- 133 Neschis DG, Scalea TM, Flinn WR, Griffith BG. Blunt aortic injury. *N Engl J Med* 2008;**359**:1708–16.
- 134 Nagy K, Fabian T, Rodman G, Fulda G, Rodriguez A, Mirvis S. Guidelines for the diagnosis and management of blunt aortic injury: an EAST Practice Management Guidelines Work Group. *J Trauma* 2000;**48**:1128–43.
- 135 Malhorta AK, Fabian TC, Croce MA, Weiman DS, Gavant ML, Pate JW. Minimal aortic injury: a lesion associated with advancing diagnostic techniques. *J Trauma* 2001;**51**:1042–8.
- 136 Azizzadeh A, Keyhani K, Miller III CC, Coogan SM, Safi HJ, Estrera AL, et al. Blunt traumatic aortic injury: initial experience with endovascular repair. *J Vasc Surg* 2009;**49**:1403–8.
- 137 Heystraten FM, Rosenbusch G, Kingma LM, Lacquet LK. Chronic posttraumatic aneurysm of the thoracic aorta: surgically correctable occult threat. *AJR Am J Roentgenol* 1986;**148**:303–8.
- 138 Finkelmeier BA, Mentzner RM, Kaiser DL, Tegtmeier CJ, Nolan SP. Chronic traumatic thoracic aneurysm — influence of

- operative treatment on natural history: an analysis of reported case 1950–1980. *J Cardiovasc Surg* 1982;**84**:257–66.
- 139 Bennett DE, Cherry JK. The natural history of traumatic aneurysms of the aorta. *Surgery* 1967;**61**:516–23.
- 140 Kirkham JR, Blackmore CC. Screening for aortic injury with chest radiography and clinical factors. *Emerg Radiol* 2007;**14**: 211–7.
- 141 Ekeh AP, Peterson W, Woods RJ, Walusimbi M, Nwuneli N, Saxe JM, et al. Is chest x-ray an adequate screening tool for the diagnosis of blunt thoracic aortic injury? *J Trauma* 2008;**65**:1088–92.
- 142 Steenburg SD, Ravenel JG, Ikonomidis JS, Schönholz C, Reeves S. Acute traumatic aortic injury: imaging evaluation and management. *Radiology* 2008;**248**:748–62.
- 143 Patel NH, Hahn D, Comess KA. Blunt chest trauma victims: role of intravascular ultrasound and transesophageal echocardiography in cases of abnormal thoracic aortogram. *J Trauma* 2003;**55**:330–7.
- 144 Starnes BW, Lundgren RS, Gunn M, Quade S, Hatsukami TS, Tran NT, et al. A new classification scheme for treating blunt aortic injury. *J Vasc Surg* 2012;**55**:47–54.
- 145 Muhs BE, Vincken KL, van Prehn J, Stone MK, Bartels LW, Prokop M, et al. Dynamic cine-CT angiography for the evaluation of the thoracic aorta; insight in dynamic changes with implications for thoracic endograft treatment. *Eur J Vasc Endovasc Surg* 2006;**32**:532–6.
- 146 Fabian T, Richardson J, Croce M. Prospective study of blunt aortic injury: multicenter trial of the American Association for the Surgery of Trauma. *J Trauma* 1997;**42**:374–80.
- 147 Estrera AL, Gochnour DC, Azizzadeh A, Miller 3rd CC, Coogan S, Charlton-Ouw K, et al. Progress in the treatment of blunt thoracic aortic injury: 12-year single-institution experience. *Ann Thorac Surg* 2010;**90**:64–71.
- 148 Hemmila MR, Arbabi S, Rowe SA, Brandt MM, Wang SC, Taheri PA, et al. Delayed repair for blunt thoracic aortic injury: is it really equivalent to early repair? *J Trauma* 2004;**56**:13–23.
- 149 Demetriades D, Velmahos GC, Scalea TM, Jurkovich GJ, Karmy-Jones R, Teixeira PG, et al. Operative repair or endovascular stent graft in blunt traumatic thoracic aortic injuries: results of an American Association for the Surgery of Trauma Multicenter Study. *J Trauma* 2008;**64**:561–70.
- 150 Murad MH, Rizvi AZ, Malgor R, Carey J, Alkatib AA, Erwin PJ, et al. Comparative effectiveness of the treatments for aortic transection. *J Vasc Surg* 2011;**53**:193–9.
- 151 Lee WA, Matsumura JS, Mitchell RS, Farber MA, Greenberg RK, Azizzadeh A, et al. Endovascular repair of traumatic thoracic aortic injury: clinical practice guidelines of the Society for Vascular Surgery. *J Vasc Surg* 2011;**53**:187–92.
- 152 Bhaskar J, Foo J, Sharma AK. Clamp-and-sew technique for traumatic injuries of the aorta: 20-year experience. *Asian Cardiovasc Thorac Ann* 2010;**18**:161–5.
- 153 Von Oppel OU, Dunne TT, De Groot MK, Zilla P. Traumatic aortic rupture: twenty-year metaanalysis of mortality and risk of paraplegia. *Ann Thorac Surg* 1994;**58**:585–93.
- 154 Cardarelli MG, McLaughlin JS, Downing SW, Brown JM, Attar S, Griffith BP, et al. Management of traumatic aortic rupture: a 30 year experience. *Ann Surg* 2002;**236**:465–9.
- 155 Volodos NL. Historical perspective: the first steps in endovascular aortic repair: how it all began. *J Endovasc Ther* 2013;**20**(Suppl. 1):13–23.
- 156 Geisbusch P, Leszczynsky M, Kotelis D, Hyhlik-Durr A, Weber TF, Bockler D. Open versus endovascular repair of acute aortic transections—a non-randomized single center analysis. *Langenbecks Arch Surg* 2009;**394**:1101–7.
- 157 Steuer J, Björck M, Sonesson B, Resch T, Dias N, Hultgren R, et al. Editor's choice — Durability of endovascular repair in blunt traumatic thoracic aortic injury: long-term outcome from four tertiary referral centres. *Eur J Vasc Endovasc Surg* 2015;**50**:460–5.
- 158 Ugrnani F, Lerut P, Da Rocha M, Adriani D, Leon F, Rimbau V. Endovascular treatment of acute traumatic thoracic aortic injuries: a retrospective analysis of 20 cases. *J Thorac Cardiovasc Surg* 2009;**138**:1129–38.
- 159 Karmy-Jones R, Ferrigno L, Teso D, Long III WB, Shackford S. Endovascular repair compared with operative repair of traumatic rupture of the thoracic aorta: a nonsystematic review and a plea for trauma-specific reporting guidelines. *J Trauma* 2011;**71**:1059–72.
- 160 Hoffer EK, Forauer AR, Silas AM, Gemery JM. Endovascular stentgraft or OR for blunt thoracic aortic trauma: systematic review. *J Vasc Interv Radiol* 2008;**19**:1153–64.
- 161 Akowuah E, Angelini G, Bryan AJ. Open versus endovascular repair of traumatic aortic rupture: a systematic review. *J Thorac Cardiovasc Surg* 2009;**138**:768–9.
- 162 Hong MS, Feezor RJ, Lee WA, Nelson PR. The advent of thoracic endovascular aortic repair is associated with broadened treatment eligibility and decreased overall mortality in traumatic thoracic aortic injury. *J Vasc Surg* 2011;**53**:36–42.
- 163 Muhs BE, Balm R, White GH, Verhagen HJ. Anatomic factors associated with acute endograft collapse after Gore TAG treatment of thoracic aortic dissection or traumatic rupture. *J Vasc Surg* 2007;**45**:655–61.
- 164 Jonker FH, Verhagen HJ, Mojibian H, Davis KA, Moll FL, Muhs BE. Aortic endograft sizing in trauma patients with hemodynamic instability. *J Vasc Surg* 2010;**52**:39–44.
- 165 Demers P, Miller DC, Mitchell RS, Kee ST, Sze D, Razavi MK, et al. Chronic traumatic aneurysms of the descending thoracic aorta: mid-term results of endovascular repair using first and second-generation stent grafts. *Eur J Cardiothorac Surg* 2004;**25**:394–400.
- 166 Lookstein RA, Goldman J, Pukin L, Marin ML. Time-resolved magnetic resonance angiography as a noninvasive method to characterize endoleaks: initial results compared with conventional angiography. *J Vasc Surg* 2004;**39**:27–33.
- 167 Crawford ES. The diagnosis and management of aortic dissection. *J Am Med Assoc* 1990;**264**:2537–41.
- 168 Evangelista A, Salas A, Ribera A, Ferreira-González I, Cuellar H, Pineda V. Long-term outcome of aortic dissection with patent false lumen: predictive role of entry tear size and location. *Circulation* 2012;**125**:3133–41.
- 169 Winnerkvist A, Lockowandt U, Rasmussen E, Radegran K. A prospective study of medically treated acute type B aortic dissection. *Eur J Vasc Endovasc Surg* 2006;**32**:349–55.
- 170 Marui A, Mochizuki T, Mitsui N, Koyama T, Kimura F, Horibe M. Toward the best treatment for uncomplicated patients with type B acute aortic dissection: a consideration for sound surgical indication. *Circulation* 1999;**100**(Suppl. 19): II275–80.
- 171 Hata M, Shiono M, Inoue T, Sezai A, Niino T, Negishi N, et al. Optimal treatment of type B acute aortic dissection: long-term medical follow up results. *Ann Thorac Surg* 2003;**75**:1781–4.
- 172 Immer FF, Krähenbühl E, Hagen U, Stalder M, Berdat PA, Eckstein FS, et al. Large area of the false lumen favors

- secondary dilatation of the aorta after acute type A aortic dissection. *Circulation* 2005;**112**(Suppl. 9):I249–52.
- 173 Sueyoshi E, Sakamoto I, Hayashi K, Yamaguchi T, Imada T. Growth rate of aortic diameter in patients with type B aortic dissection during the chronic phase. *Circulation* 2004;**110**(Suppl. 1):II256–61.
- 174 Tsai TT, Evangelista A, Nienaber CA, Myrmel T, Meinhardt G, Cooper JV, et al. Partial thrombosis of the false lumen in patients with acute type B aortic dissection. *N Engl J Med* 2007;**357**:349–59.
- 175 Tsai TT, Schlicht MS, Khanafer K, Bull JL, Valassis DT, Williams DM, et al. Tear size and location impacts false lumen pressure in an ex vivo model of chronic type B aortic dissection. *J Vasc Surg* 2008;**47**:844–51.
- 176 Pitt MP, Bonser RS. The natural history of thoracic aortic aneurysm disease: an overview. *J Card Surg* 1997;**12**(Suppl.):270–8.
- 177 Elefteriades JA, Lovoulos CJ, Coady MA, Tellides G, Kopf GS, Rizzo JA. Management of descending aortic dissection. *Ann Thorac Surg* 1999;**67**:2002–5.
- 178 Griep RB, Ergin MA, Galla JD, Lansman SL, McCullough JN, Nguyen KH, et al. Natural history of descending thoracic and thoracoabdominal aneurysms. *Ann Thorac Surg* 1999;**67**:1927–30.
- 179 Onitsuka S, Akashi H, Tayama K, Okazaki T, Ishihara K, Hiromatsu S. Long-term outcome and prognostic predictors of medically treated acute type B aortic dissections. *Ann Thorac Surg* 2004;**78**:1268–73.
- 180 Zoli S, Etz CD, Roder F, Mueller CS, Brenner RM, Bodian CA, et al. Long-term survival after open repair of chronic distal aortic dissection. *Ann Thorac Surg* 2010;**89**:1458–66.
- 181 Nishida T, Masuda M, Tomita Y, Tokunaga S, Tanoue Y, Shiose A. The logistic EuroSCORE predicts the hospital mortality of the thoracic aortic surgery in consecutive 327 Japanese patients better than the additive EuroSCORE. *Eur J Cardiothorac Surg* 2006;**30**:578–82.
- 182 Bakaeen FG, Chu D, Huh J, LeMaire SA, Soltero ER, Petersen NJ, et al. Contemporary outcomes of open thoracic aortic surgery in a veteran population: do risk models exaggerate mortality? *Am J Surg* 2009;**198**:889–94.
- 183 Conrad MF, Chung TK, Cambria MR, Parachuri V, Brady TJ, Cambria RP. Effect of chronic dissection on early and late outcomes after descending thoracic and thoracoabdominal aneurysm repair. *J Vasc Surg* 2011;**53**:600–7.
- 184 Crawford ES, Crawford JL, Safi HJ, Coselli JS, Hess KR, Brooks B. Thoracoabdominal aortic aneurysms: pre-operative and intra-operative factors determining immediate and long-term results of operations in 605 patients. *J Vasc Surg* 1986;**3**:389–404.
- 185 Safi HJ, Miller 3rd CC, Estrera AL, Huynh TT, Porat EE, Hassoun HT, et al. Chronic aortic dissection not a risk factor for neurologic deficit in thoracoabdominal aortic aneurysm repair. *Eur J Vasc Endovasc Surg* 2002;**23**:244–50.
- 186 Conrad MF, Ergul EA, Patel VI, Paruchuri V, Kwolek CJ, Cambria RP. Management of diseases of the descending thoracic aorta in the endovascular era: a Medicare population study. *Ann Surg* 2010;**252**:603–10.
- 187 Thrumurthy SG, Karthikesalingam A, Patterson BO, Holt PJ, Hinchliffe RJ, et al. A systematic review of mid-term outcomes of thoracic endovascular repair (TEVAR) of chronic type B aortic dissection. *Eur J Vasc Endovasc Surg* 2011;**42**:632–47.
- 188 Nordon IM, Hinchliffe RJ, Loftus IM, Morgan RA, Thompson MM. Management of acute aortic syndrome and chronic aortic dissection. *Cardiovasc Intervent Radiol* 2011;**34**:890–902.
- 189 Song JM, Kim SD, Kim JH, Kim MJ, Kang DH, Seo JB, et al. Long-term predictors of descending aorta aneurysmal change in patients with aortic dissection. *J Am Coll Cardiol* 2007;**50**:799–804.
- 190 Nienaber CA, Kische S, Rousseau H, Eggebrecht H, Rehders TC, Kundt G, et al. Endovascular repair of type B aortic dissection: long-term results of the randomized investigation of stent grafts in aortic dissection trial. *Circ Cardiovasc Interv* 2013;**6**:407–16.
- 191 Kang WC, Greenberg RK, Mastracci TM, Eagleton MJ, Hernandez AV, Pujara AC, et al. Endovascular repair of complicated chronic distal aortic dissections: intermediate outcomes and complications. *Thorac Cardiovasc Surg* 2011;**142**:1074–83.
- 192 Rodriguez JA, Olsen DM, Lucas L, Wheatley G, Ramaiah V, Diethrich EB. Aortic remodeling after endografting of thoracoabdominal aortic dissection. *J Vasc Surg* 2008;**47**:1188–94.
- 193 Nordon IM, Hinchliffe RJ, Holt PJ, Morgan R, Jahangiri M, Loftus IM, et al. Endovascular management of chronic aortic dissection in patients with Marfan syndrome. *J Vasc Surg* 2009;**50**:987–91.
- 194 Kölbl T, Carpenter SW, Lohrenz C, Tsilimparis N, Larena-Avellaneda A, Debus ES. Addressing persistent false lumen flow in chronic aortic dissection: the knickerbocker technique. *J Endovasc Ther* 2014;**21**:117–22.
- 195 Bonser RS, Pagano D, Lewis ME, Rooney SJ, Guest P, Davies P, et al. Clinical and patho-anatomical factors affecting expansion of thoracic aortic aneurysms. *Heart* 2000;**84**:277–83.
- 196 Perko MJ, Norgaard M, Herzog TM, Olsen PS, Schroeder TV, Pettersson G. Unoperated aortic aneurysm: a survey of 170 patients. *Ann Thorac Surg* 1995;**59**:1204–9.
- 197 Mitchell SL. Stent grafts for the thoracic aorta: a new paradigm? *Ann Vasc Surg* 2002;**74**:S1818–20.
- 198 Jacobs MJ, de Mol BA, Elenbaas T, Mess WH, Kalkman CJ, Schurink GW, et al. Spinal cord blood supply in patients with thoracoabdominal aortic aneurysms. *J Vasc Surg* 2002;**35**:30–7.
- 199 Backes WH, Nijenhuis RJ, Mess WH, Wilmlink FA, Schurink GWH, Jacobs MJ, et al. Magnetic resonance angiography of collateral blood supply to spinal cord in thoracic and thoracoabdominal aortic aneurysm patients. *J Vasc Surg* 2008;**48**:261–71.
- 200 Czerny M, Eggebrecht H, Sodeck G, Verzini F, Cao P, Maritati G. Mechanisms of symptomatic spinal cord ischaemia after TEVAR: insights from the European Registry of Endovascular Aortic Repair Complications (EuREC). *J Endovasc Ther* 2012;**19**:37–43.
- 201 Mehta VK, Lafaro RJ, De Vincenzo S. Successful management of an aneurysmal aortoesophageal fistula. *J Cardiovasc Surg* 2000;**41**:721–3.
- 202 Estrera AL, Miller III CC, Chen EP, Meada R, Torres RH, Porat EE, et al. Descending thoracic aortic aneurysm repair: 12-year experience using distal aortic perfusion and cerebrospinal fluid drainage. *Ann Thorac Surg* 2005;**80**:1290–6.
- 203 Poldermans D, Schouten O, Vidakovic R, Bax JJ, Thomson IR, Hoeks SE, et al. A clinical randomized trial to evaluate the safety of a noninvasive approach in high risk patients undergoing major vascular surgery: the DECREASE-V Pilot Study. *J Am Coll Cardiol* 2007;**49**:1763–9.
- 204 Eagle KA, Rihal CS, Mickel MC, Holmes DR, Foster ED, Gersh BJ. Cardiac risk of noncardiac surgery. CASS Investigators and University of Michigan Heart Care Program influence of coronary disease and type of surgery in 3368

- operations. Coronary Artery Surgery Study. *Circulation* 1997;**96**:1882–7.
- 205 Svensson LG, Hess KR, Coselli JS, Safi HJ, Crawford ES. A prospective study of respiratory failure after high risk surgery on the thoracoabdominal aorta. *J Vasc Surg* 1991;**14**: 271–82.
- 206 Safi HJ, Harlin SA, Miller CC, Iliopoulos DC, Joshi A, Mohasci TG, et al. Predictive factors for acute renal failure in thoracic and thoracoabdominal aortic aneurysm surgery. *J Vasc Surg* 1996;**24**:338–44.
- 207 Fehrenbacher JW, Hart DW, Huddleston E, Siders H, Rice C. Optimal end-organ protection for thoracic and thoracoabdominal aortic aneurysm repair using deep hypothermic circulatory arrest. *Ann Thorac Surg* 2007;**83**:1041–6.
- 208 Patel HJ, Shillingford MS, Mihalik S, Proctor MC, Deeb GM. Resection of the descending thoracic aorta: outcomes after use of hypothermic circulatory arrest. *Ann Thorac Surg* 2006;**82**:90–5.
- 209 Minatoya K, Ogino H, Matsuda H, Sasaki H, Yagihara T, Kitamura S. Replacement of the descending aorta: recent outcomes of OR performed with partial cardiopulmonary bypass. *J Thorac Cardiovasc Surg* 2008;**136**:431–5.
- 210 Schermerhorn ML, Giles KA, Hamdan AD, Dalhberg SE, Hagberg R, Pomposelli F. Population-based outcomes of open descending thoracic aortic aneurysm repair. *J Vasc Surg* 2008;**48**:821–7.
- 211 Abraha I, Romagnoli C, Montedori A, Cirocchi R. Thoracic stent graft versus surgery for thoracic aneurysm. *Cochrane Database Syst Rev* 2016;(6):CD006796.
- 212 Walsh SR, Tang TY, Sadat U, Naik J, Gaunt ME, Boyle JR, et al. Endovascular stenting versus OR for thoracic aortic disease: systematic review and meta-analysis of peri-operative results. *J Vasc Surg* 2008;**47**:1094–8.
- 213 Goodney PP, Travis LF, Lucas FL, Fillinger MF, Goodman DC, Cronenwett JL, et al. Survival after open versus endovascular thoracic aortic aneurysm repair in an observational study of the Medicare population. *Circulation* 2011;**124**:2661–9.
- 214 Cheng D, Martin J, Shennib H, Dunning J, Muneretto C, Schueler S, et al. Endovascular aortic repair versus OR for descending thoracic aortic disease a systematic review and meta-analysis of comparative studies. *J Am Coll Cardiol* 2010;**55**:986–1001.
- 215 Coady MA, Ikonomidis JS, Cheung AT, Matsumoto AH, Dake MD, Chaikof EL, et al. Surgical management of descending thoracic aortic disease: open and endovascular approaches: a scientific statement from the American Heart Association. *Circulation* 2010;**121**:2780–804.
- 216 Ullery BW, Cheung AT, Fairman RM, Jackson BM, Woo EY, Bavaria J, et al. Risk factors, outcomes, and clinical manifestations of spinal cord ischaemia following thoracic endovascular aortic repair. *J Vasc Surg* 2011;**54**:677–84.
- 217 Martin DJ, Martin TD, Hess PJ, Daniels MJ, Feezor RJ, Lee WA. Spinal cord ischaemia after TEVAR in patients with abdominal aortic aneurysms. *J Vasc Surg* 2009;**49**:302–6.
- 218 Chiesa R, Melissano G, Marrocco-Trischitta MM, Civilini E, Setacci F. Spinal cord ischaemia after elective stent graft repair of the thoracic aorta. *J Vasc Surg* 2005;**42**:11–7.
- 219 Cooper DG, Walsh SR, Sadat U, Hayes PD, Boyle JR. Neurological complications after left subclavian artery coverage during thoracic endovascular aortic repair: a systematic review and meta-analysis. *J Vasc Surg* 2009;**49**: 1594–601.
- 220 Leon Jr LR, Mills Sr JL, Jordan W, Morasch MM, Kovacs M, Becker GJ, et al. The risks of coeliac artery coverage during endoluminal repair of thoracic and thoracoabdominal aortic aneurysms. *Vasc Endovascular Surg* 2009;**43**:51–60.
- 221 Libicher M, Reichert V, Aleksic M, Brunkwall J, Lackner KJ, Gawenda M. Balloon occlusion of the coeliac artery: a test for evaluation of collateral circulation prior endovascular coverage. *Eur J Vasc Endovasc Surg* 2008;**36**:303–5.
- 222 Safi HJ, Winnerkvist A, Miller 3rd CC, Iliopoulos DC, Reardon MJ, Espada R. Effect of extended cross-clamp time during thoracoabdominal aortic aneurysm repair. *Ann Thorac Surg* 1998;**66**:1204–9.
- 223 Cambria RA, Gloviczki P, Stanson AW, Cherry Jr KJ, Bower TC, Hallett Jr JW, et al. Outcome and expansion rate of 57 thoracoabdominal aortic aneurysms managed non-operatively. *Am J Surg* 1995;**170**:213–7.
- 224 Suzuki S, Davis 3rd CA, Miller 3rd CC, Huynh TT, Estrera AL, Porat EE, et al. Cardiac function predicts mortality following thoracoabdominal and descending thoracic aortic aneurysm repair. *Eur J Cardiothorac Surg* 2003;**24**:119–24.
- 225 Coselli JS, LeMaire SA, Conklin LD, Koksoy C, Schmittling ZC. Morbidity and mortality after extent II thoracoabdominal aortic aneurysm repair. *Ann Thorac Surg* 2002;**73**:1107–15.
- 226 LeMaire SA, Miller 3rd CC, Conklin LD, Schmittling ZC, Koksoy C, Coselli JS. A new predictive model for adverse outcomes after elective thoracoabdominal aortic aneurysm repair. *Ann Thorac Surg* 2001;**71**:1233–8.
- 227 Coselli JS, Bozinovski J, LeMaire SA. OR of 2286 thoracoabdominal aortic aneurysms. *Ann Thorac Surg* 2007;**83**: S862–4.
- 228 LeMaire SA, Jones MM, Conklin LD, Carter SA, Criddell MD, Wang XL, et al. Randomized comparison of cold blood and cold crystalloid renal perfusion for renal protection during thoracoabdominal aortic aneurysm repair. *J Vasc Surg* 2009;**49**:11–9.
- 229 Hanssen SJ, Derikx JP, Vermeulen Windsant IC, Heijmans JH, Koeppel TA, Schurink GW, et al. Visceral injury and systemic inflammation in patients undergoing extracorporeal circulation during aortic surgery. *Ann Surg* 2008;**248**:117–25.
- 230 Fedorow CA, Moon MC, Mutch WA, Grocott HP. Lumbar cerebrospinal fluid drainage for thoracoabdominal aortic surgery: rationale and practical considerations for management. *Anesth Analg* 2010;**111**:46–58.
- 231 Conrad MF, Crawford RS, Davison JK, Cambria RP. Thoracoabdominal aneurysm repair: a 20-year perspective. *Ann Thorac Surg* 2007;**83**:S856–61.
- 232 Bicknell CD, Riga CV, Wolfe JHN. Prevention of paraplegia during thoracoabdominal aortic aneurysm repair. *Eur J Vasc Endovasc Surg* 2009;**37**:654–60.
- 233 Rigberg DA, McGory ML, Zingmond DS, Maggard MA, Agustin M, Lawrence PF, et al. Thirty-day mortality statistics underestimate the risk of repair of thoracoabdominal aortic aneurysms: a state wide experience. *J Vasc Surg* 2006;**43**: 217–22.
- 234 Cowan JA, Dimick JB, Henke PK, Huber TS, Stanley JC, Upchurch Jr GR. Surgical treatment of intact thoracoabdominal aortic aneurysms in the United States: hospital and surgeon volume-related outcomes. *J Vasc Surg* 2003;**37**:1169–74.
- 235 Karthikesalingam A, Hinchliffe RJ, Loftus IM, Thompson MM, Holt PJ. Volume-outcome relationships in vascular surgery: the current status. *J Endovasc Ther* 2010;**17**:356–65.

- 236 Lee WA, Brown MP, Martin TD, Seeger JM, Huber TS. Early results after staged hybrid repair of thoracoabdominal aortic aneurysms. *J Am Coll Surg* 2007;**205**:420–31.
- 237 Chiesa R, Tshomba Y, Marone EM, Logaldo D, Bertoglio L, Kahlberg A, et al. Hybrid procedures for the treatment of thoracoabdominal aortic aneurysms and dissections. *J Cardiovasc Surg* 2010;**51**:821–32.
- 238 Shahverdyan R, Gawenda M, Brunkwall J. Five-year patency rates of renal and visceral bypasses after abdominal debranching for thoracoabdominal aortic aneurysms. *Eur J Vasc Endovasc Surg* 2013;**45**:648–56.
- 239 Maurel B, Delclaux N, Sobocinski J, Hertault A, Martin-Gonzalez T, Moussa M, et al. The impact of early pelvic and lower limb reperfusion and attentive peri-operative management on the incidence of spinal cord ischemia during thoracoabdominal aortic aneurysm endovascular repair. *Eur J Vasc Endovasc Surg* 2015;**49**(3):248–54.
- 240 Verhoeven EL, Katsargyris A, Bekkema F, Oikonomou K, Zeebregts CJ, Ritter W, et al. Editor's Choice — Ten-year experience with endovascular repair of thoracoabdominal aortic aneurysms: results from 166 consecutive patients. *Eur J Vasc Endovasc Surg* 2015;**49**:524–31.
- 241 Mastracci TM, Greenberg RK, Eagleton MJ, Hernandez AV. Durability of branches in branched and fenestrated endografts. *J Vasc Surg* 2013;**57**:926–33.
- 242 Haulon S, Barillà D, Tyrrell M. Fenestrated endografts should be restricted to a small number of specialized centers. *Eur J Vasc Endovasc Surg* 2013;**45**:200–3.
- 243 Clough RE, Modarai B, Bell RE, Salter R, Sabharwal T, Taylor PR, et al. Total endovascular repair of thoracoabdominal aortic aneurysms. *Eur J Vasc Endovasc Surg* 2012;**43**:262–7.
- 244 Takayasu M. *A case with peculiar changes of the central retinal vessels*, 12. Tokyo: Acta Societatis Ophthalmologicae Japonicae; 1908. p. 554.
- 245 Arend WP, Michel BA, Bloch DA, Hunder GG, Calabrese LH, Edworthy SM, et al. The American College of Rheumatology 1990 criteria for the classification of Takayasu arteritis. *Arthritis Rheum* 1990;**33**:1129–34.
- 246 Baril DT, Carroccio A, Palchik E, Ellozy SH, Jacobs TS, Teodorescu V, et al. Endovascular treatment of complicated aortic aneurysms in patients with underlying arteriopathies. *Ann Vasc Surg* 2006;**20**:464–71.
- 247 Hunder GG, Bloch DA, Michel BA, Stevens MB, Arend WP, Calabrese LH, et al. The American College of Rheumatology 1990 criteria for the classification of giant cell arteritis. *Arthritis Rheum* 1990;**33**:1122–8.
- 248 Ninan J, Nguyen AM, Cole A, Rischmueller M, Dodd T, Roberts-Thomson P. Mortality in patients with biopsy-proven giant cell arteritis: a South Australian population-based study. *J Rheumatol* 2011;**38**:2215–7.
- 249 Cid MC, Cebrian M, Font C, Coll-Vinent B, Hernández-Rodríguez J, Esparza J, et al. Cell adhesion molecules in the development of inflammatory infiltrates in giant cell arteritis: inflammation-induced angiogenesis as the preferential site of leukocyte-endothelial cell interactions. *Arthritis Rheum* 2000;**43**:184–94.
- 250 Taylor-Gjevne R, Vo M, Shukla D, Resch L. Temporal artery biopsy for giant cell arteritis. *J Rheumatol* 2005;**32**:1279–82.
- 251 Nuenninghoff DM, Hunder GG, Christianson TJ, McClelland RL, Matteson EL. Incidence and predictors of large-artery complication (aortic aneurysm, aortic dissection, and/or large-artery stenosis) in patients with giant cell arteritis: a population-based study over 50 years. *Arthritis Rheum* 2003;**48**:3522–31.
- 252 Nuenninghoff DM, Hunder GG, Christianson TJ, McClelland RL, Matteson EL. Mortality of large-artery complication (aortic aneurysm, aortic dissection, and/or large-artery stenosis) in patients with giant cell arteritis: a population-based study over 50 years. *Arthritis Rheum* 2003;**48**:3532–7.
- 253 Töpel I, Zorger N, Steinbauer M. Inflammatory diseases of the aorta: Part 1: non-infectious aortitis. *Gefasschirurgie* 2016;**21**(Suppl 2):80–6.
- 254 Hoffman GS, Cid MC, Rendt-Zagar KE, Merkel PA, Weyand CM, Stone JH, et al. Infliximab for maintenance of glucocorticosteroid-induced remission of giant cell arteritis: a randomized trial. *Ann Intern Med* 2007;**146**:621–30.
- 255 Neshar G, Berkun Y, Mates M, Baras M, Rubinow A, Sonnenblick M. Low-dose aspirin in the treatment of giant cell arteritis. *Arthritis Rheum* 2004;**50**:1026–7.
- 256 Demirkesen C, Öz B, Göksel S. Behçet's disease: pathology. In: Yazöcö Y, Yazöcö H, editors. *Behçet's syndrome*. 1st ed. New York: Springer; 2010. p. 215–42.
- 257 Tuzun H, Seyahi E, Arslan C, Hamuryudan V, Besirli K, Yazici H. Management and prognosis of nonpulmonary large arterial disease in 25 patients with Behçet disease from a single center. *J Vasc Surg* 2012;**55**:157–63.
- 258 Tunacı A, Berkmen YM, Gokmen E. Thoracic involvement in Behçet's disease: pathologic, clinical, and imaging features. *Am J Roentgenol* 1995;**164**:51–6.
- 259 Miller DV, Maleszewski JJ. The pathology of large-vessel vasculitides. *Clin Exp Rheumatol* 2011;**29**(1 Suppl. 64):S92–8.
- 260 Abe S, Ooyasu T, Itou M, Kamikubo Y, Takahira M. Ruptured descending aortic aneurysm in a young woman with systemic lupus erythematosus. *Kyobu Geka* 2010;**63**:565–7.
- 261 Ho VB, Bakalov VK, Cooley M, Van PL, Hood MN, Burklow TR, et al. Major vascular anomalies in Turner syndrome: prevalence and magnetic resonance angiographic features. *Circulation* 2004;**110**:1694–700.
- 262 Connolly HM, Huston 3rd J, Brown Jr RD, Warnes CA, Ammash NM, Tajik AJ. Intracranial aneurysms in patients with coarctation of the aorta: a prospective magnetic resonance angiographic study of 100 patients. *Mayo Clin Proc* 2003;**78**:1491–9.
- 263 Nielsen JC, Powell AJ, Gauvreau K, Marcus EN, Prakash A, Geva T. Magnetic resonance imaging predictors of coarctation severity. *Circulation* 2005;**111**:622–8.
- 264 Campbell M. Natural history of coarctation of the aorta. *Br Heart J* 1970;**32**:633–40.
- 265 Babu-Narayan SV, Mohiaddin RH, Cannell TM, Muhll IV, Dimopoulos K, Mullen M, et al. Cardiovascular changes after transcatheter endovascular stenting of adult aortic coarctation. *Int J Cardiol* 2011;**149**:157–63.
- 266 Brown ML, Burkhart HM, Connolly HM, Dearani JA, Hagler DJ, Schaff HV, et al. Late outcomes of re-intervention on the descending aorta after repair of aortic coarctation. *Circulation* 2010;**122**:S81–4.
- 267 Carr JA. The results of catheter-based therapy compared with surgical repair of adult aortic coarctation. *J Am Coll Cardiol* 2006;**47**:1101–7.
- 268 Tanous D, Collins N, Dehghani P, Benson LN, Horlick EM. Covered stents in the management of coarctation of the aorta in the adult: initial results and 1 year angiographic and hemodynamic follow up. *Int J Cardiol* 2010;**140**:287–95.

- 269 Moltzer E, Roos-Hesselink JW, Yap SC, Cuypers JA, Bogers AJ, de Jaegere PP, et al. Endovascular stenting for aortic (re) coarctation in adults. *Neth Heart J* 2010;**18**:430–6.
- 270 Keane MG, Pyeritz RE. Medical management of Marfan syndrome. *Circulation* 2008;**117**:2802–13.
- 271 Mizuguchi T, Collod-Beroud G, Akiyama T, Abifadel M, Harada N, Morisaki T, et al. Heterozygous TGFBR2 mutations in Marfan syndrome. *Nat Genet* 2004;**36**:855–60.
- 272 Mátyás G, Arnold E, Carrel T, Baumgartner D, Boileau C, Berger W, et al. Identification and in silico analyses of novel TGFBR1 and TGFBR2 mutations in Marfan syndrome-related disorders. *Hum Mutat* 2006;**27**:760–9.
- 273 Mizuguchi T, Matsumoto N. Recent progress in genetics of Marfan syndrome and Marfan-associated disorders. *J Hum Genet* 2007;**52**:1–12.
- 274 Gautier M, Detaint D, Fermanian C, Aegerter P, Delorme G, Arnoult F. Nomograms for aortic root diameters in children using two-dimensional echocardiography. *Am J Cardiol* 2010;**105**:888–94.
- 275 Radonic T, de Witte P, Baars MJ, Zwinderman AH, Mulder BJ, Groenink M. COMPARE Study Group. Losartan therapy in adults with Marfan syndrome: study protocol of the multi-centre randomized controlled COMPARE trial. *Trials* 2010;**12**:11–3.
- 276 Gambarin FI, Favalli V, Serio A, Regazzi M, Pasotti M, Klersy C. Rationale and design of a trial evaluating the effects of losartan vs. nebivolol vs. the association of both on the progression of aortic root dilation in Marfan syndrome with FBN1 gene mutations. *J Cardiovasc Med (Hagerstown)* 2009;**10**:354–62.
- 277 Rahman J, Rahman FZ, Rahman W, al-Suleiman SA, Rahman MS. Obstetric and gynecologic complications in women with Marfan syndrome. *J Reprod Med* 2003;**48**:723–8.
- 278 Loeys BL, Chen J, Neptune ER, Judge DP, Podowski M, Holm T, et al. A syndrome of altered cardiovascular, craniofacial, neurocognitive and skeletal development caused by mutations in TGFBR1 or TGFBR2. *Nat Genet* 2005;**37**:275–81.
- 279 Loeys BL, Schwarze U, Holm T, Callewaert BL, Thomas GH, Pannu H, et al. Aneurysm syndromes caused by mutations in the TGF-beta receptor. *N Engl J Med* 2006;**355**:788–98.
- 280 Williams JA, Loeys BL, Nwakanma LU, Dietz HC, Spevak PJ, Patel ND, et al. Early surgical experience with Loeys-Dietz: a new syndrome of aggressive thoracic aortic aneurysm disease. *Ann Thorac Surg* 2007;**83**:S757–63.
- 281 Hughes GC. Aggressive aortic replacement for Loeys-Dietz syndrome. *Tex Heart Inst J* 2011;**38**:663–6.
- 282 Beridze N, Frishman WH. Vascular Ehlers-Danlos syndrome: pathophysiology, diagnosis, and prevention and treatment of its complications. *Cardiol Rev* 2012;**20**:4–7.
- 283 Ong KT, Perdu J, De Backer J, Bozec E, Collignon P, Emmerich J, et al. Effect of celiprolol on prevention of cardiovascular events in vascular Ehlers-Danlos syndrome: a prospective randomised, open, blinded-endpoints trial. *Lancet* 2010;**376**:1476–84.
- 284 Oderich GS, Panneton JM, Bower TC, Lindor NM, Cherry KJ, Noel AA. The spectrum, management and clinical outcome of Ehlers-Danlos syndrome type IV: a 30 year experience. *J Vasc Surg* 2005;**42**:98–106.
- 285 Lum YW, Brooke BS, Arnaoutakis GJ, Williams TK, Black 3rd JH. Endovascular procedures in patients with Ehlers-Danlos syndrome: a review of clinical outcomes and iatrogenic complications. *Ann Vasc Surg* 2012;**26**:25–33.
- 286 Erez Y, Ezra Y, Rojansky N. Ehlers-Danlos type IV in pregnancy. A case report and a literature review. *Fetal Diagn Ther* 2008;**23**:7–9.
- 287 Stochholm K, Juul S, Juel K, Naeraa RW, Gravholt CH. Prevalence, incidence, diagnostic delay, and mortality in Turner syndrome. *J Clin Endocrinol Metab* 2006;**91**:3897–902.
- 288 Carlson M, Silberbach M. Dissection of the aorta in Turner syndrome: two cases and review of 85 cases in the literature. *J Med Genet* 2007;**44**:745–9.
- 289 Matura LA, Sachdev V, Bakalov VK, Rosing DR, Bondy CA. Growth hormone treatment and left ventricular dimensions in Turner syndrome. *J Pediatr* 2007;**150**:587–91.
- 290 Keramati AR, Sadeghpour A, Farahani MM, Chandok G, Mani A. The non-syndromic familial thoracic aortic aneurysms and dissections maps to 15q21 locus. *BMC Med Genet* 2010;**11**:143.
- 291 Tulsyan N, Valentin MD, Ombrellino M, Moritz M, Agis H, Kabnick L. Recurrent aortic angiosarcoma — a case report and review of the literature. *Angiology* 2006;**57**:123–5.
- 292 Wright EP, Glick AD, Virmani R, Page DL. Aortic intimal sarcoma with embolic metastases. *Am J Surg Pathol* 1985;**9**:890–7.
- 293 Sibille L, Ilonca D, Oziol E, Gandilhon P, Micheau A, Vernhet-Kovacsik H, et al. FDG PET/CT in aortic angiosarcoma. *Clin Nucl Med* 2010;**35**:134–7.
- 294 Chiche L, Mongrédien B, Brocheriou I, Kieffer E. Primary tumors of the thoracoabdominal aorta: surgical treatment of 5 patients and review of the literature. *Ann Vasc Surg* 2003;**17**:354–64.
- 295 Hales SL, Locke R, Sandison A, Jenkins M, Hamady M. Aortic angiosarcoma: a rare cause for leaking thoracic aneurysm. *Cardiovasc Intervent Radiol* 2011;**34**(Suppl. 2):S20–4.
- 296 Pagni S, Trivedi J, Ganzel BL, Williams M, Kapoor N, Ross C, et al. Thoracic aortic mobile thrombus: is there a role for early surgical intervention? *Ann Thorac Surg* 2011;**91**:1875–81.
- 297 Avegliano G, Evangelista A, Elorz C, González-Alujas MT, García del Castillo H, Soler-Soler J. Acute peripheral arterial ischaemia and suspected aortic dissection. Usefulness of transesophageal echocardiography in differential diagnosis with aortic thrombosis. *Am J Cardiol* 2002;**90**:674–7.
- 298 Criado F, Wall P, Lucas P, Gasparis A, Proffitt T, Ricotta J. Transesophageal echo-guided endovascular exclusion of thoracic aortic mobile thrombi. *J Vasc Surg* 2004;**39**:238–45.
- 299 Desai ND, Burtch K, Moser W, Moeller P, Szeto WY, Pochettino A. Long-term comparison of thoracic endovascular aortic repair (TEVAR) to OR for the treatment of thoracic aortic aneurysms. *J Thorac Cardiovasc Surg* 2012;**144**:604–9.
- 300 Ayuso JR, de Caralt TM, Pages M, Rimbau V, Ayuso C, Sanchez M, et al. MRA is useful as a follow up technique after endovascular repair of aortic aneurysms with nitinol endoprotheses. *J Magn Reson Imaging* 2004;**20**:803–10.
- 301 Bruggink JL, Glaudemans AW, Saleem BR, Meerwaldt R, Alkefaji H, Prins TR, et al. Accuracy of FDG-PET-CT in the diagnostic work up of vascular prosthetic graft infection. *Eur J Vasc Endovasc Surg* 2010;**40**:348–54.
- 302 Therrien J, Thorne SA, Wright A, Kilner PJ, Somerville J. Repaired coarctation: a “cost-effective” approach to identify complications in adults. *J Am Coll Cardiol* 2000;**35**:997–1002.
- 303 Ralovich K, Itu L, Mihalef V, Sharma P, Ionasec R, Vitanovski D, et al. Hemodynamic assessment of pre- and post-operative aortic coarctation from MRI. *Med Image Comput Comput Assist Interv* 2012;**15**:486–93.
- 304 Parmer SS, Carpenter JP, Stavropoulos SW, Fairman RM, Pochettino A, Woo EY, et al. Endoleaks after endovascular repair of thoracic aortic aneurysms. *J Vasc Surg* 2006;**44**:447–52.