

CLINICAL PRACTICE GUIDELINE DOCUMENT

## Editor's Choice – European Society for Vascular Surgery (ESVS) 2020 Clinical Practice Guidelines on the Management of Vascular Graft and Endograft Infections<sup>☆</sup>

Nabil Chakfé<sup>\*,a,e</sup>, Holger Diener<sup>a</sup>, Anne Lejay<sup>a,e</sup>, Ojan Assadian<sup>a</sup>, Xavier Berard<sup>a</sup>, Jocelyne Caillon<sup>a,e</sup>, Inge Fourneau<sup>a</sup>, Andor W.J.M. Glaudemans<sup>a,d</sup>, Igor Koncar<sup>a</sup>, Jes Lindholt<sup>a</sup>, Germano Melissano<sup>a</sup>, Ben R. Saleem<sup>a</sup>, Eric Senneville<sup>a,e</sup>, Riemer H.J.A. Slart<sup>a,d</sup>, Zoltan Szeberin<sup>a</sup>, Maarit Venermo<sup>a</sup>, Frank Vermassen<sup>a</sup>, Thomas R. Wyss<sup>a</sup>

ESVS Guidelines Committee<sup>b</sup>, Gert J. de Borst, Frederico Bastos Gonçalves, Stavros K. Kakkos, Philippe Kolh, Riikka Tulamo, Melina Vega de Ceniga

Document Reviewers<sup>c</sup>, Regula S. von Allmen, Jos C. van den Berg, E. Sebastian Debus, Mark J.W. Koelemay, Jose P. Linares-Palomino, Gregory L. Moneta, Jean-Baptiste Ricco, Anders Wanhainen

### DEDICATION

After studying medicine at Hanover Medical School and philosophy and social psychology at the Leibniz University Hanover, Omke E. Teebken joined the Christian Albrechts University in Kiel at the end of the 1990s as a research fellow at the Clinic for Cardiovascular Surgery headed by Professor Dr Axel Haverich, whom Omke E. Teebken later followed back to Hanover.

In Hanover, besides working as a clinician, Omke E. Teebken was particularly active scientifically, contributing to the establishment of the then newly founded Leibniz Laboratories for Biotechnology and Artificial Organs (LEBAO). His work focused on regenerative medicine and tissue engineering, and subsequently he wrote his habilitation thesis in this field. After basic training in cardiac surgery, he specialised clinically in vascular surgery and played a pioneering role in the development of this field. Before being appointed director of the Clinic for Vascular Surgery – Endovascular Surgery at the Peine Clinic in 2016, Omke E. Teebken headed the Vascular Surgery – Endovascular Surgery Division of the Department of Cardiothoracic, Thoracic, Transplantation and Vascular Surgery at Hanover Medical School. Professor Teebken was a highly appreciated, committed, and competent colleague and teacher.

On 8 April 2019, Professor Teebken passed away after a short and severe illness. He was member and author of the ESVS guideline writing committee, an esteemed colleague, and friend.

We will always honor his memory.



Prof. Dr. med. Omke Enno Teebken  
21.8.1968 – 8.4.2019

<sup>☆</sup> The ESVS 2020 Guidelines on Management of Vascular Graft Infections are Endorsed by the European Association of Nuclear Medicine (EANM) For full list of Author's affiliations, please refer to [Appendix](#).

<sup>a</sup> **Writing Committee:** Nabil Chakfé (Chair)<sup>\*</sup> (Strasbourg, France), Holger Diener (Co-Chair) (Hamburg, Germany), Anne Lejay (Strasbourg, France), Ojan Assadian (Vienna, Austria), Xavier Berard (Bordeaux, France), Jocelyne Caillon (Nantes, France), Inge Fourneau (Leuven, Belgium), Andor W.J.M. Glaudemans (Groningen, The Netherlands), Igor Koncar (Belgrade, Serbia), Jes Lindholt (Odense, Denmark), Germano Melissano (Milan, Italy), Ben R. Saleem (Groningen, The Netherlands), Eric Senneville (Tourcoing, France), Riemer H.J.A. Slart (Groningen, The Netherlands), Zoltan Szeberin (Budapest, Hungary), Omke Teebken (Peine, Germany), Maarit Venermo (Helsinki, Finland), Frank Vermassen (Ghent, Belgium), Thomas R. Wyss (Bern, Switzerland).

<sup>b</sup> **ESVS Guidelines Committee:** Gert J. de Borst (Chair) (Utrecht, The Netherlands), Frederico Bastos Gonçalves (Lisbon, Portugal), Stavros K. Kakkos (Patras, Greece), Philippe Kolh (Liège, Belgium), Riikka Tulamo (Helsinki, Finland), Melina Vega de Ceniga (Review coordinator) (Bizkaia, Spain).

<sup>c</sup> **Document Reviewers:** Regula S. von Allmen (Gallen, Switzerland), Jos C. van den Berg (Bern, Switzerland), E. Sebastian Debus (Hamburg-Eppendorf, Germany), Mark J.W. Koelemay (Amsterdam, The Netherlands), Jose P. Linares-Palomino (Granada, Spain), Gregory L.L. Moneta (Portland, OR, USA), Jean-Baptiste Ricco (Poitiers, France), Anders Wanhainen (Uppsala, Sweden).

<sup>d</sup> **European Association of Nuclear Medicine**

<sup>e</sup> **Groupe de Recherche sur les Infections de Prothèses**

<sup>\*</sup> Corresponding author.

E-mail address: [nabil.chakfe@chru-strasbourg.fr](mailto:nabil.chakfe@chru-strasbourg.fr) (Nabil Chakfé).

1078-5884/© 2019 European Society for Vascular Surgery. Published by Elsevier B.V. All rights reserved.

<https://doi.org/10.1016/j.ejvs.2019.10.016>

## TABLE OF CONTENTS

List of abbreviations .....	342
<b>1. Introduction and General Aspects .....</b>	<b>343</b>
1.1. Purpose of the guidelines .....	343
1.2. Methods .....	343
1.2.1. The writing committee .....	343
1.2.2. Evidence collection .....	343
1.2.2.1. Search strategy .....	343
1.2.2.2. Literature search and selection .....	343
1.2.2.3. Evidence and recommendation grading criteria .....	343
1.2.2.4. The patient's perspective .....	343
1.2.3. The revision process .....	344
1.2.4. The update plan .....	344
<b>2. General Considerations .....</b>	<b>344</b>
2.1. Definition of incisional surgical site infection .....	344
2.2. Classifications .....	344
2.3. Definition of vascular graft/endograft infection .....	344
2.4. Epidemiology .....	344
2.4.1. Incidence .....	344
2.4.2. Risk factors .....	344
2.5. Pathogenesis .....	344
2.6. Clinical presentation .....	345
2.7. Microbiology and sampling techniques .....	346
2.7.1. Microbiology .....	346
2.7.2. Sampling techniques .....	347
2.7.2.1. Directly obtained specimens .....	347
2.7.2.2. Indirectly obtained specimens .....	347
2.7.3. Microbiological sample processing .....	348
2.8. Imaging modalities .....	348
2.8.1. Introduction .....	348
2.8.2. Conventional techniques .....	348
2.8.2.1. Ultrasound .....	348
2.8.2.2. Computed tomography angiography .....	348
2.8.2.3. Magnetic resonance angiography .....	348
2.8.3. Nuclear imaging techniques .....	348
2.8.3.1. Positron emission tomography .....	349
2.8.3.2. White blood cell scintigraphy .....	350
<b>3. Strategies to Prevent Graft or Endograft Infection .....</b>	<b>351</b>
3.1. Raw materials .....	351
3.2. Logistics and peri-operative care .....	352
3.2.1. Staphylococcus nasal carriage .....	352
3.2.2. Peri-operative care .....	352
3.2.2.1. Shower regimen and hair removal .....	352
3.2.2.2. Antimicrobial prophylaxis .....	352
3.2.2.3. Gloves .....	352
3.2.2.4. Wound closure .....	352
3.3. Antibiotic prophylaxis during dental extraction .....	352
<b>4. General Therapeutic Strategies .....</b>	<b>353</b>
4.1. Antimicrobial therapy .....	353
4.1.1. Choice of antimicrobial therapy .....	353
4.1.2. Duration of treatment .....	353
4.1.3. Antimicrobial therapy management .....	353
4.1.4. Isolation .....	353
4.2. Surgical principles .....	353
<b>5. Supra-aortic Trunks .....</b>	<b>354</b>
5.1. Specific aspects .....	354
5.1.1. Incidence .....	354
5.1.2. Clinical presentation .....	354
5.1.3. Specific diagnostic modalities .....	354
5.2. Treatment options for supra-aortic trunk vascular graft/endograft infection .....	354
5.2.1. Conservative treatment .....	354
5.2.2. Endovascular treatment .....	354
5.2.3. Reconstruction .....	355
5.2.3.1. Graft material .....	355
5.2.3.2. Partial or total explantation .....	355
5.2.3.3. Adjunctive therapy .....	355
5.3. Follow up and prognosis .....	356
<b>6. Thoracic/Thoraco-abdominal Aorta .....</b>	<b>356</b>
6.1. Specific aspects .....	356
6.1.1. Incidence .....	356
6.1.2. Clinical presentation .....	356

6.1.3.	Specific diagnostic modalities	356
6.2.	<i>Thoracic vascular graft/endograft infection without fistula</i>	357
6.2.1.	Conservative treatment	357
6.2.1.1.	<i>Percutaneous drainage</i>	357
6.2.1.2.	<i>Irrigation</i>	357
6.2.2.	<i>In situ reconstruction</i>	358
6.2.2.1.	<i>Specific techniques</i>	358
6.2.2.2.	<i>Graft materials</i>	358
6.2.2.3.	<i>Adjunctive therapy</i>	358
6.2.3.	Extra-anatomic reconstruction	358
6.2.3.1.	<i>Technique</i>	358
6.2.3.2.	<i>Stump management</i>	359
6.2.4.	Partial or total graft explantation	359
6.3.	<i>Thoracic vascular graft or endograft infection with oesophageal fistula</i>	359
6.3.1.	Conservative treatment	359
6.3.2.	Endovascular treatment as bridging therapy	359
6.3.3.	Treatment of the oesophagus	360
6.3.3.1.	<i>Limited treatment of fistula</i>	360
6.3.3.2.	<i>Radical fistula treatment</i>	360
6.3.3.3.	<i>Oesophageal prosthesis</i>	360
6.3.3.4.	<i>Definitive treatment: one or two stage</i>	360
6.4.	<i>Thoracic vascular graft or endograft infection with airway fistula</i>	360
6.4.1.	Endovascular treatment	360
6.4.2.	Open surgical treatment	361
6.5.	<i>Follow up and prognosis</i>	361
7.	<b>Abdominal Aorta</b>	362
7.1.	<i>Specific aspects</i>	362
7.1.1.	Incidence	362
7.1.2.	Clinical presentation	362
7.1.3.	Specific diagnostic modalities	362
7.2.	<i>Treatment options</i>	362
7.2.1.	Conservative treatment	362
7.2.1.1.	<i>Percutaneous drainage</i>	362
7.2.1.2.	<i>Irrigation</i>	362
7.2.2.	<i>In situ reconstruction</i>	362
7.2.2.1.	<i>Specific techniques</i>	362
7.2.2.2.	<i>Graft materials</i>	363
7.2.2.2.1.	Reconstruction with autologous vein	363
7.2.2.2.2.	Cryopreserved allografts	363
7.2.2.2.3.	Rifampicin bonded grafts	363
7.2.2.2.4.	Silver coated grafts	363
7.2.2.2.5.	Xenogenous grafts	365
7.2.2.3.	<i>Adjunctive therapies</i>	365
7.2.3.	Extra-anatomic reconstruction	365
7.2.3.1.	<i>Two stage procedure</i>	365
7.2.3.2.	<i>Stump management</i>	365
7.2.4.	Systematic reviews and meta-analyses on <i>in situ</i> reconstruction, extra-anatomic reconstruction, and graft materials	366
7.2.5.	Partial or total excision of the material	366
7.2.6.	Endograft infection	366
7.3.	<i>Graft enteric fistula</i>	366
7.3.1.	Specific treatment modalities	366
7.3.2.	Stent grafts as a temporary or a definitive solution	366
7.3.3.	<i>In situ</i> reconstruction or extra-anatomic reconstruction	367
7.3.4.	Total or partial graft excision	367
7.3.5.	Bowel repair	367
7.3.5.1.	<i>Direct suture vs. complex bowel reconstruction</i>	367
7.3.5.2.	<i>Omental interposition</i>	367
7.4.	<i>Visceral artery revascularisation infection</i>	367
7.5.	<i>Ureteral fistula</i>	367
7.6.	<i>Follow up and prognosis</i>	367
8.	<b>Peripheral Arteries</b>	369
8.1.	<i>Specific aspects</i>	369
8.1.1.	Incidence and risk factors	369
8.1.2.	Clinical presentation	369
8.2.	<i>Treatment options</i>	370
8.2.1.	Conservative treatment	370
8.2.1.1.	<i>Negative pressure wound therapy</i>	370
8.2.1.2.	<i>Irrigation</i>	370
8.2.2.	<i>In situ reconstruction</i>	370
8.2.2.1.	<i>Specific technical aspects</i>	370
8.2.2.2.	<i>Graft materials</i>	370

8.2.2.2.1.	Reconstruction with autologous material	370
8.2.2.2.2.	Cryopreserved allografts	371
8.2.2.2.3.	Prosthetic grafts	371
8.2.2.2.4.	Xenogenous grafts	371
8.2.2.3.	<i>Adjunctive therapy</i>	371
8.2.2.3.1.	Sartorius muscle flap (SMF)	371
8.2.2.3.2.	Rectus femoris flap (RFF)	371
8.2.2.3.3.	Gracilis muscle flap (GMF)	371
8.2.2.3.4.	Rectus abdominis flap (RAF)	372
8.2.2.3.5.	Musculocutaneous anterolateral thigh flap	372
8.2.2.3.6.	Antibiotic loaded beads	372
8.2.3.	Extra-anatomic reconstruction	372
8.2.3.1.	<i>Obturator bypass (OB)</i>	372
8.2.3.2.	<i>Lateral retrosartorius bypass (LRSB)</i>	372
8.2.3.3.	<i>Perigeniculate arteries (PGAs)</i>	372
8.2.3.4.	<i>Lateral approach to crural arteries (LACA)</i>	372
8.2.4.	Total or partial graft explantation and need for revascularisation	373
8.2.5.	Timing of surgery	373
8.3.	<i>Follow up and prognosis</i>	373
9.	<b>Patients' Perspectives</b>	374
9.1.	<i>Specific aspects</i>	374
9.1.1.	Pathological presentations	374
9.1.2.	Patient age and comorbidities	374
9.1.3.	The "easy" endovascular surgery	374
9.2.	<i>Patient feedback</i>	374
9.2.1.	Question 1: Did you feel your physician provided enough information about the risk of infection at the time of the initial procedure?	374
9.2.2.	Question 2: What did you think about the management once the diagnosis of VGEI was made?	374
9.2.3.	Question 3: Did you think your physician provided enough information on the risks related to the VGEI?	374
9.3.	<i>Ways of improvement</i>	374
10.	<b>Unresolved Issues</b>	375
	Appendix Authors' Affiliations	375
	References	376

## LIST OF ABBREVIATIONS

ABF	Aortobronchial fistula	GC	Guidelines Committee
AESF	Aorto-oesophageal fistula	GMF	Gracilis muscle flap
AEnF	Aorto-enteric fistula	GSV	Great saphenous vein
APF	Aortopulmonary fistula	ISR	<i>In situ</i> reconstruction
AUF	Arterio-ureteral fistula	LACA	Lateral approach to crural arteries
CDC	Centers for Disease Control and Prevention	LCCA	Left common carotid artery
CI	Confidence interval	LSCA	Left subclavian artery
CoNS	Coagulase negative staphylococci	LRSB	Lateral retrosartorius bypass
CRP	C reactive protein	MAGIC	Management of Aortic Graft Infection
CT	Computed tomography	MDR	Multidrug resistant
CTA	Computed tomography angiography	MRA	Magnetic resonance angiography
EANM	European Association of Nuclear Medicine	MRSA	Methicillin resistant <i>Staphylococcus aureus</i>
EAR	Extra-anatomic reconstruction	NPWT	Negative pressure wound therapy
EG	Endograft	OR	Odds ratio
EGI	Endograft infection	OB	Obturator bypass
ePTFE	Expanded polytetrafluoroethylene	PCR	Polymerase chain reaction
ESC	European Society of Cardiology	PET	Polyethylene terephthalate
ESVS	European Society for Vascular Surgery	PGA	Perigeniculate artery
EVAR	Endovascular aneurysm repair	PTFE	Polytetrafluoroethylene
EuREC	European Registry of Endovascular Aortic Complications	RAF	Rectus abdominis flap
		RCT	Randomised controlled trial
		RFF	Rectus femoris flap
<sup>18</sup> F-FDG-PET/CT	<sup>18</sup> F-fluoro-D-deoxyglucose positron emission tomography/computed tomography	RR	Relative risk
		SAT	Supra-aortic trunk
		SFA	Superficial femoral artery
		SMF	Sartorius muscle flap

SPECT/CT	Single photon emission computed tomography	VAC	Vacuum assisted closure
SSI	Surgical site infection	VG	Vascular graft
SUV <sub>max</sub>	Maximum standardised uptake value	VGI	Vascular graft infection
TEVAR	Thoracic endovascular aneurysm repair	VGEI	Vascular graft or endograft infection
US	Ultrasound	WBCS	White blood cell scintigraphy
		WC	Writing Committee

## 1. INTRODUCTION AND GENERAL ASPECTS

### 1.1. Purpose of the guidelines

Guidelines driven by scientific societies on vascular graft/endograft infection (VGEI) have not been published. The European Society for Vascular Surgery (ESVS) has developed clinical practice guidelines for the care of patients with VGEI. The aim of this document is to assist physicians involved in the diagnosis and treatment of patients with VGEI in selecting the best management strategy in different scenarios. The potential users of this guideline include angiologists, vascular, cardiovascular and general surgeons, infectious disease physicians, and radiologists, and the target population comprises patients with VGEI in the supra-aortic trunks, thoracic and/or abdominal aorta, and peripheral arteries.

Guidelines have the purpose of promoting a standard of care according to specialists in the field, in this case represented by members of the ESVS. However, under no circumstances should these guidelines be seen as the legal standard of care in all patients. As the word guidelines states in itself, the document is a guiding principle, but the care given to a single patient is always dependent on the individual (symptom variability, comorbidities, age, etc.) and treatment setting (techniques available, local expertise).

### 1.2. Methods

**1.2.1. The writing committee.** The members of this guidelines Writing Committee (WC) were selected by the ESVS, the European Association of Nuclear Medicine (EANM), and the Groupe de Recherche sur les Infections de Prothèses, to represent physicians involved in the management of patients with VGEI. They include vascular surgeons, radiologists, and infectious disease specialists. WC members have provided disclosure statements of all relationships that might be perceived as real or potential sources of conflicts of interest, which are kept on file at the ESVS headquarters. No ESVS reviewers or individual WC members received any financial support from third parties in direct or indirect relation to this guideline, and all WC members and reviewers signed declarations of interest.

### 1.2.2. Evidence collection

**1.2.2.1. Search strategy.** The purpose, list of topics, and tasks and methods regarding the construction of the guidelines were agreed and distributed among the WC members in an initial meeting held in Strasbourg on 30 June 2017.

**1.2.2.2. Literature search and selection.** All WC members performed a systematic literature search strategy for each of their assigned sections, carried out in PubMed, Scopus,

Cardiosource Clinical Trials Database, and the Cochrane Library databases, first from January 1997 to November 2017, with a later update to February 2019 for relevant papers published in English. Reference checking and a hand search added other relevant literature. Abstracts were excluded. Single case reports or case series were included if they were of paramount importance to these guidelines to enlighten the manuscript.

Selection of the literature was performed based on information provided in the title and abstract of the retrieved studies. Only peer reviewed published literature and studies presenting pre-defined outcomes were considered. The selection process followed the pyramid of evidence, with aggregated evidence at the top of the pyramid (systematic reviews, meta-analysis), followed by randomised controlled trials (RCTs), then observational studies, leaving expert opinion at the bottom. The level of evidence per section in the guidelines is dependent on the level of evidence available on the specific subject.

**1.2.2.3. Evidence and recommendation grading criteria.** To define the current guidelines, members of the WC reviewed and summarised the selected literature. Conclusions were drawn based on the availability and quality of the scientific evidence, and recommendations for the evaluation and treatment of patients with VGEI were formulated based on the analysis of the evidence and through consensus when evidence was scarce.

The European Society of Cardiology (ESC) grading system was used for evidence and recommendation rating. The letter A, B, or C reflects the level of current evidence (Table 1), and weighing the level of evidence and expert opinion, each recommendation is graded as class I, IIa, IIb, or III (Table 2). For those recommendations tables of evidence were built and are available as supplementary material.

**1.2.2.4. The patient's perspective.** The goals behind patient participation in healthcare decision making can be categorised as democratisation and increased quality of decisions. Patient engagement improves the validity of clinical guidelines and is encouraged by international and national groups. In order to better understand patient feedback,

**Table 1. Level of evidence**

Level of evidence A	Data derived from multiple randomized clinical trials or meta analyses.
Level of evidence B	Data derived from a single randomized clinical trials or large non-randomized studies.
Level of evidence C	Consensus of opinion of the experts and/or small studies, retrospective studies, registries.

**Table 2.** Classes of recommendations

Classes of recommendations	Definition
Class I	Evidence and/or general agreement that a given treatment or procedure is beneficial, useful, effective.
Class II	Conflicting evidence and/or a divergence of opinion about the usefulness/efficacy of the given treatment or procedure.
Class IIa	Weight of evidence/opinion is in favour of usefulness/efficacy.
Class IIb	Usefulness/efficacy is less well established by evidence/opinion.
Class III	Evidence or general agreement that the given treatment or procedure is not useful/effective, and in some cases may be harmful.

European patients were interviewed: representatives of patient associations in the field of aortic dissection and infectious diseases; and patients treated for abdominal VGEI (patients operated on by surgeons of the WC). The main questions that arose from discussions were: (1) Did you feel your physician provided enough information about the risk of infection at the time of the initial procedure? (2) What did you think about the management once the diagnosis of VGEI was made? and (3) Did you think that your physician provided enough information on the risks related to VGEI? Patients were interviewed with a focus on these three open questions.

**1.2.3. The revision process.** The guidelines document, merged and harmonised by the co-chairmen of the WC, underwent internal review. Once approved by every WC member, it moved on to external revision by the ESVS Guidelines Committee (GC) members and chosen external experts in the field. Each draft was revised by the WC and the final document, approved by all WC and GC members and external reviewers, was submitted to *the European Journal of Vascular and Endovascular Surgery* on 20 July 2019.

**1.2.4. The update plan.** As technology and disease knowledge in this field changes rapidly, current recommendations can become outdated. It is an aim of the ESVS to revise the guidelines when important new insights in the evaluation and management of VGEI become available or every five years at the latest.

## 2. GENERAL CONSIDERATIONS

### 2.1. Definition of incisional surgical site infection

Studies dealing with VGEI are mostly case series rather than randomised studies. Diagnosis of VGEI is usually related to clinical findings, imaging studies, and microbiological examinations.<sup>1</sup> Criteria for incisional surgical site infections (SSI), which can be both superficial and deep, have been described by the Centers for Disease Control and Prevention (CDC) and can be applied to the description of VGEI (Table 3).<sup>2</sup>

### 2.2. Classifications

While the CDC definitions<sup>2</sup> differentiate between superficial and deep incisional SSIs without placing emphasis on vascular grafts (VGs), the Szilagyi classification and the Samson classification specifically also consider VG involvement, while the extent of graft involvement can be described using the Bunt classification (Table 4).<sup>3–5</sup> Furthermore, aortic VGEI can also be divided into early (< 4 months) or late (> 4 months) onset, which, in many cases, is also extrapolated to other VGEI.<sup>6</sup> However, the clinical relevance of differentiation between early and late infections remains a matter of debate.

### 2.3. Definition of vascular graft/endograft infection

To overcome the numerous shortcomings of current classifications, the Management of Aortic Graft Infection (MAGIC) group has developed a list of major and minor criteria with respect to clinical, surgical, radiological, and laboratory findings (Table 5).<sup>1</sup> Once VGEI is suspected, an exhaustive evaluation of the clinical status, signs of infection, and comorbidities of the patient according to the MAGIC criteria is recommended.

According to the MAGIC criteria, VGEI is suspected in the presence of one major or two minor criteria of the three different categories, and VGEI is diagnosed when there is at least a single major criterion and any other criterion from another category. For example, a fever  $\geq 38^{\circ}\text{C}$  is considered non-specific for VGEI and therefore it is required that no other clinical cause is apparent. Sepsis and systemic inflammatory response syndrome may be caused by something other than VGEI and is defined as combinations of different findings. Anorexia, lethargy, and malaise may accompany aortic graft and endograft (EG) infection, but are also considered insufficiently specific.<sup>1</sup> Intra-operative fluids around a graft can represent pus, but despite a yellowish or cloudy appearance may be present for non-infective reasons and microbiological culture will be negative. Therefore, pus cells must be proven by direct microscopy to be considered a major criterion. Furthermore, a direct communication between non-sterile sites and a prosthesis indicates graft infection: aorto-enteric fistula (AeNF), aorto-bronchial fistula (ABF), deployment of a stent graft in an already infected field (e.g., infected aneurysm), and exposed grafts in deep open wounds.

### 2.4. Epidemiology

**2.4.1. Incidence.** VGEI are usually multifactorial and result from the complex involvement of patient, surgical, and environmental factors, making the real incidence difficult to assess. Reported incidences of VGEI by type and anatomical location will be developed in specific sections.

**2.4.2. Risk factors.** Multiple risk factors contribute to VGEI and are listed in Table 6.

### 2.5. Pathogenesis

The pathogenesis of VGEI is multifactorial. Presumably, early VGEI are mostly caused by a breach in sterility during

<b>Table 3. Centers for Disease Control and Prevention criteria for superficial and deep surgical site infections (SSI)<sup>2</sup></b>		
<b>Criteria</b>	<b>Superficial SSI</b>	<b>Deep SSI</b>
<i>Diagnostic criteria*</i>		
1	Infection occurs within 30 days after the operative procedure	Infection occurs within 30 days after the operative procedure if no implant is left in place, or within one year if implant is in place and the infection appears to be related to the operative procedure
and 2	Infection involves only skin and subcutaneous tissue of the incision	Infection involves deep soft tissues (e.g., fascia and muscle layers) of the incision
and 3	Patient has at least one of the following:	Patient has at least one of the following:
	<ul style="list-style-type: none"> <li>• Purulent drainage from the superficial incision</li> <li>• Organisms isolated from an aseptically obtained culture of fluid or tissue from the superficial incision</li> <li>• At least one of the following signs or symptoms of infection: pain or tenderness, localised swelling, redness or heat, and superficial incision is deliberately opened by surgeon and is culture positive or not cultured. A culture negative finding does not meet this criterion</li> <li>• Diagnosis of superficial incisional SSI by a surgeon or attending physician</li> </ul>	<ul style="list-style-type: none"> <li>• Purulent drainage from the deep incision but not from the organ/space component of the surgical site</li> <li>• A deep incision spontaneously dehisces or is deliberately opened by a surgeon and is culture positive or not cultured when the patient has at least one of the following signs or symptoms: fever (&gt;38°C), or localised pain or tenderness. A culture negative finding does not meet this criterion</li> <li>• An abscess or other evidence of infection involving the deep incision is found on direct examination, during re-operation, or by histopathological or radiological examination</li> <li>• Diagnosis of a deep incisional SSI by a surgeon or attending physician</li> </ul>
<i>Types</i>		
Incisional primary	A superficial incisional SSI that is identified in the primary incision in a patient who has had an operation with one or more incisions	A deep incisional SSI that is identified in a primary incision in a patient who has had an operation with one or more incisions
Incisional secondary	A superficial incisional SSI that is identified in the secondary incision in a patient who has had an operation with >1 incision (e.g., donor site [leg] incision to harvest autologous veins for <i>in situ</i> reconstruction of an abdominal vascular graft infection)	A deep incisional SSI that is identified in the secondary incision in a patient who has had an operation with >1 incision (e.g., donor site [leg] incision to harvest autologous veins for <i>in situ</i> reconstruction of an abdominal vascular graft infection)
<i>Reporting instructions</i>		
	Do not report a skin suture abscess with minimal inflammation and discharge confined to the points of suture penetration, as an infection	Classify infection that involves both superficial and deep incision sites as deep incisional SSI
	Do not report a localised stab wound infection as SSI; instead, report as skin or soft tissue infection, depending on its depth	
	If the incisional site infection involves or extends into the fascial and muscle layers, report as a deep incisional SSI	

\* For diagnosis of SSI, diagnostic criteria 1, 2, and 3 must all be true.

implantation or the presence of bacteria in the aneurysmal thrombus, while late VGEI are mostly caused by haematogenous seeding from a bacteraemia (mostly arising from the urinary or respiratory tract), or from bacterial translocation or iatrogenic contamination during catheterisation.<sup>6–8</sup> The pathogenesis of AEnF, aorto-oesophageal (AEsF), and ABF remains unclear. Ischaemia of the visceral wall due to occlusion of the feeding arteries, and mechanical erosion by the aneurysm or of a suture line pseudo-aneurysm, especially when still under pressure due to presence of an endoleak, have all been suggested. Fistula can occur as a result of direct trauma related to surgical injury, poor tunnelling, erosion by direct contact, or by the penetration of an oversized EG. Previous adjacent or remote infection in any site is considered to be a causative or contributing factor.<sup>9,10</sup>

The quality of material incorporation related to tissue ingrowth and healing also plays a role, explaining that VEGI

might even be more frequent than VG infection (VGI), as there is no tissue ingrowth in the wall of the EG fabric that is surrounded only by thrombotic material, contrary to VG.<sup>11</sup>

## 2.6. Clinical presentation

As mentioned in the MAGIC criteria, the clinical presentation of patients with VGEI varies between mild symptoms (redness of the skin, non-purulent effusion from a wound) to severe and evident symptoms such as sepsis or anastomotic rupture with hypovolaemic shock.<sup>1</sup> Fever of unclear origin and an unexplained leukocytosis with concomitant increase of C reactive protein (CRP) and fever may be the only clinical or laboratory sign of VGEI. In other cases the clinical manifestations may include abscess, mass, septic embolisation, septic shock, bleeding, melaena, haematemesis, haematuria, ileus, or abdominal distension. When VGEI is suspected, a complete clinical and biochemical evaluation

**Table 4. Classifications for wound and vascular graft infections with respect to wound infection (Szilagy, Samson) and to the extent of graft involvement (Bunt)<sup>3-5</sup>**

<i>Szilagy classification:</i>
Grade I: cellulitis involving the wound
Grade II: infection involving subcutaneous tissue
Grade III: infection involving the vascular prosthesis
<i>Samson classification:</i>
Group 1: no deeper than dermis
Group 2: subcutaneous tissue, no direct contact with the graft
Group 3: body of graft but not anastomosis
Group 4: exposed anastomosis, no bleeding, no bacteraemia
Group 5: anastomosis involved, bleeding, bacteraemia
<i>Extent of graft involvement (Bunt classification modified)</i>
<i>Peripheral graft infection:</i>
P0 graft infection: infection of a cavitory graft (e.g., aortic arch; abdominal and thoracic aortic interposition; aorto-iliac, aortofemoral, iliofemoral graft infections)
P1 graft infection: infection of a graft whose entire anatomical course is non-cavitory (e.g., carotid-subclavian, axillo-axillary, axillofemoral, femorofemoral, femorodistal, dialysis access bridge graft infections)
P2 graft infection: infection of the extracavitory portion of a graft whose origin is cavitory (e.g., infected groin segment of an aortofemoral or thoracofemoral graft, cervical infection of an aortocarotid graft)
P3 graft infection: infection involving a prosthetic patch angioplasty (e.g., carotid and femoral endarterectomies with prosthetic patch closure)
Graft-enteric erosion
Graft-enteric fistula
Aortic stump sepsis after excision of an infected aortic graft

of the patient is required in order to provide a sufficient analytical overview.<sup>12</sup>

Post-implantation syndrome, characterised by transitory fever associated with elevated leukocytes and CRP may be observed following endograft implantation, but might also be distinguishing from an actual infection.<sup>13</sup>

## 2.7. Microbiology and sampling techniques

**2.7.1. Microbiology.** Micro-organism identification is a key issue in order to provide the patient with the best treatment. Using the different available sampling techniques, micro-organisms can be isolated in about 75% – 98% of cases.<sup>14-16</sup> Responsible pathogens are Gram positive

**Table 5. The MAGIC classification<sup>1</sup>**

Criterion	Clinical/surgical	Radiology	Laboratory
<i>Major</i>			
	Pus (confirmed by microscopy) around graft or in aneurysm sac at surgery	Perigraft fluid on CT scan $\geq$ 3 months after insertion	Organisms recovered from an explanted graft
	Open wound with exposed graft or communicating sinus	Perigraft gas on CT scan $\geq$ 7 weeks after insertion	Organisms recovered from an intra-operative specimen
	Fistula development, e.g., aorto-enteric or aortobronchial	Increase in perigraft gas volume demonstrated on serial imaging	Organisms recovered from a percutaneous, radiologically guided aspirate of perigraft fluid
	Graft insertion in an infected site, e.g., fistula, mycotic aneurysm, or infected pseudo-aneurysm		
<i>Minor</i>			
	Localised clinical features of graft infection, e.g., erythema, warmth, swelling, purulent discharge, pain	Other, e.g., suspicious perigraft gas/fluid soft tissue inflammation; aneurysm expansion; pseudo-aneurysm formation: focal bowel wall thickening; discitis/osteomyelitis; suspicious metabolic activity on FDG-PET/CT; radiolabelled leukocyte uptake	Blood culture(s) positive and no apparent source except graft infection
	Fever $\geq$ 38°C with graft infection as most likely cause		Abnormally elevated inflammatory markers with graft infection as most likely cause, e.g., erythrocyte sedimentation rate, C reactive protein, white cell count

CT = computed tomography; FDG-PET/CT = 18F-fluoro-D-deoxyglucose positron emission tomography/computed tomography



**Table 6. Risk factors for vascular graft/endograft infection**<sup>6,7</sup>

<i>Pre-operative risk factors</i>
Prolonged pre-operative hospitalisation
Infection in a remote or adjacent site
Recent percutaneous arterial access at the implant site
Emergency/urgent procedure
Re-intervention
Lower limb infection (ulcer, gangrene, cellulitis)
Groin incision
<i>Intra-operative risk factors</i>
Breach in aseptic technique
Prolonged operation time
Concomitant gastrointestinal or genitourinary procedure
<i>Post-operative risk factors</i>
Post-operative wound complications (infection, skin necrosis, lymphocele, seroma, haematoma)
Graft thrombosis
<i>Patient related risk factors/altered host defences</i>
Malignancy
Lymphoproliferative disorder
Immune disorders
Corticosteroid administration
Chemotherapy
Malnutrition
Diabetes mellitus/peri-operative hyperglycaemia
Chronic renal insufficiency/end stage renal disease
Liver disease/cirrhosis
Immunosuppression by non-suspended anti-tumour necrosis factor alpha

bacteria in up to 58% of VGEI (including enterococci, *Staphylococcus aureus*, and coagulase negative staphylococci); Gram negative bacteria account for about 34% of VGEIs and anaerobes 8%.<sup>14–17</sup>

In a recent meta-analysis, the risk of re-infection has been studied according to different infecting micro-organisms.<sup>17</sup> *Staphylococcus aureus*, Enterobacteriaceae, *Pseudomonas aeruginosa*, and beta haemolytic streptococci were classified as virulent, while bacteria belonging to the skin colonising flora such as *Staphylococcus epidermidis*, corynebacterial, and *Cutibacterium acnes* were classified as non-virulent agents. The results of this meta-analysis established that virulent organisms were significantly associated with an increased risk of re-infection.

Antimicrobial resistance of the causative bacteria is another factor that may reduce the chance of healing, but this relationship has not been clearly established in the setting of VGEIs.<sup>14</sup>

The susceptibility of bacteria to the few antibiotics that exhibit a sustained activity in the environment of a biofilm (e.g., rifampicin combinations for staphylococcal implant infections) is another element that may lead to re-infection in patients treated for VGEIs.<sup>18–20</sup>

**2.7.2. Sampling techniques.** Microbiological samples may support establishing the diagnosis of a VGEI. Ideally samples should be harvested before the start of antimicrobial therapy. However the accuracy and relevance of microbiological tests depend on whether specimens were

collected without contamination, and in an adequate quantity.<sup>21</sup> Moreover, samples should be forwarded quickly to the microbiology laboratory. If they cannot be forwarded immediately they should be stored at +4°C.

**2.7.2.1. Directly obtained specimens.** Meaningful results will be achieved with specimens obtained directly from the suspected infection site. These may include surgically explanted prosthetic materials, intra-operatively obtained tissue and graft biopsies from the infected area, or at least three samples from perigraft fluid collection.<sup>22</sup> Paediatric anaerobic tubes, which require very small amounts of material, can be used.

Aspirated specimens obtained under ultrasound (US) or computed tomography (CT) guidance provide material for an accurate microbiological diagnosis. The presence of graft incorporation into tissue reliably excluded the presence of bacteria in cultures in 97% of investigated grafts, whereas the finding of graft disincorporation accurately predicted a positive culture in 89% of all positive VGEI cases.<sup>23</sup> In general, tissue specimens or a portion of the graft material are superior to swab specimens of infected sites, even when collected using a sterile technique intra-operatively. At least three direct specimens should be collected in sterile containers.<sup>22</sup> Swabs should be avoided because they do not allow differentiation of colonising micro-organisms from true pathogens and may lead to overprescription of broad spectrum antibiotics. Swabs have an inherent difficulty transferring bacteria or fungi from the swab fibres onto culture media, and because the inoculum from the swab often is not uniformly distributed across several different agar plates.<sup>24</sup> If swabs are used, the type of swab should be selected on basis of its ability to collect micro-organisms. Polyethylene terephthalate (PET) swabs should be used.

A new innovative specimen collection technology (microDTTect) could help in the future, as it allows for contamination free sampling, and also it can dislodge bacteria embedded in a biofilm from prosthetic surfaces.<sup>25</sup>

**2.7.2.2. Indirectly obtained specimens.** Indirect specimens might also be meaningful, especially when direct specimens are not collected in cases when redo surgery is not performed. Such specimens include blood cultures, specimens obtained from a superficial wound, a draining sinus, or otherwise close anatomical structures.

Despite being an indirect microbiological sampling method, blood cultures may yield supportive information, as pre-operative blood cultures have been found to be positive in about 35% of cases and both pre- and peri-operative samples are positive for the same micro-organism in about 22% – 30% of cases.<sup>14,15</sup>

However, other indirectly obtained specimens using swabs, biopsy samples or aspirates obtained from a superficial wound, a draining sinus, or otherwise close anatomical structures always contain skin flora or colonisation, and might not accurately reflect the causative micro-organism of a VGEI.<sup>26</sup> Bacteriological

investigation of negative pressure wound therapy (NPWT) foams should not be performed to support the diagnosis of a VGEI because of the low sensitivity and specificity.<sup>27</sup>

Therefore, results from indirectly obtained specimens should be considered with caution.

**2.7.3. Microbiological sample processing.** Specimens may be investigated using different techniques such as direct streaking specimens on agar plates, placing specimens into broth culture, homogenisation of tissue or graft specimens with serial dilution techniques, sonication of a harvested graft, or vortex mixing tissue samples in order to enhance the recovery of biofilm forming microorganisms.<sup>28</sup>

Enhanced sample processing techniques such as vortex mixing specimens or sonication improve the detection rate of microorganisms attached to graft material.<sup>28–30</sup> One study found that ultrasonic bath treatment released consistently more bacteria than direct ultrasonic disruption or vortex agitation.<sup>31</sup> Importantly, the high energy levels of direct ultrasonic disruption can decrease the number of viable Gram negative bacteria, and vortex agitation consistently produced the lowest bacterial numbers among the three methods tested. An ultrasonic bath treatment of one to five minutes duration of infected VG at a frequency of 25 – 40 KHz may be the optimal preparation method for causative bacteria detection.<sup>31</sup> Adding broad range polymerase chain reaction (PCR) detection to sonicated fluid cultures may even increase the detection rate of bacteria attached to graft material.<sup>32</sup>

## 2.8. Imaging modalities

**2.8.1. Introduction.** Various imaging techniques are used in the diagnostic work up when VGEI is suspected. Conventional imaging techniques such as US, CT, CT with angiography (CTA), and magnetic resonance with angiography (MRA) are used most frequently. Other available imaging tools are nuclear medicine techniques, such as 18F-fluoro-D-deoxyglucose positron emission tomography (18F-FDG-PET) with or without diagnostic contrast enhanced CT (18F-FDG-PET/CT), and white blood cell scintigraphy (WBCS), that can be combined with single photon emission computed tomography (SPECT/CT) for better localisation of the infection.<sup>33</sup>

### 2.8.2. Conventional techniques

**2.8.2.1. Ultrasound.** US is the most common, non-invasive, low cost imaging modality to identify findings associated with VGEI.

US characteristics of VGEI are the presence of pseudo-aneurysm, sustained presence of gas (if still present after > 7 weeks), and purely anechoic fluid collections (if still present >3 months after surgery).<sup>33,34</sup> It can differentiate between haematoma or abscess formation, which makes it a good primary imaging screening modality, especially for superficial peripheral VG. However, the absence of peri-

prosthetic collections on US does not allow ruling out of a VGEI. US also allows investigating for graft thrombosis, which can be the first sign of VGEI, and it can guide puncture for bacteriological purposes.<sup>14,33,35</sup>

However, US has a high interoperator variability and the predictive value is limited in the case of a centrally located graft due to overlying bowel gas or obesity.<sup>14,34</sup> Therefore, the sensitivity of US for the diagnosis of VGEI is considered as low, and additional investigations are often needed to obtain more detailed information on VG status.

**2.8.2.2. Computed tomography angiography.** CTA has been considered the reference imaging standard in diagnosing VGEI for a long time, as it is able to visualise the characteristic features of VGEI.<sup>33</sup> The use of intravenous contrast, with images acquired in the arterial phase, may show certain signs such as ectopic gas, fluid, soft tissue enhancement, pseudo-aneurysm, focal bowel thickening, and discontinuation of the aneurysmal wall, all of which can all be used as criteria to increase the likelihood of a VGEI.<sup>36</sup> Furthermore, in the arterial phase it may be possible to detect contrast passage from the aorta to the digestive tract in cases of AEnF.<sup>33</sup>

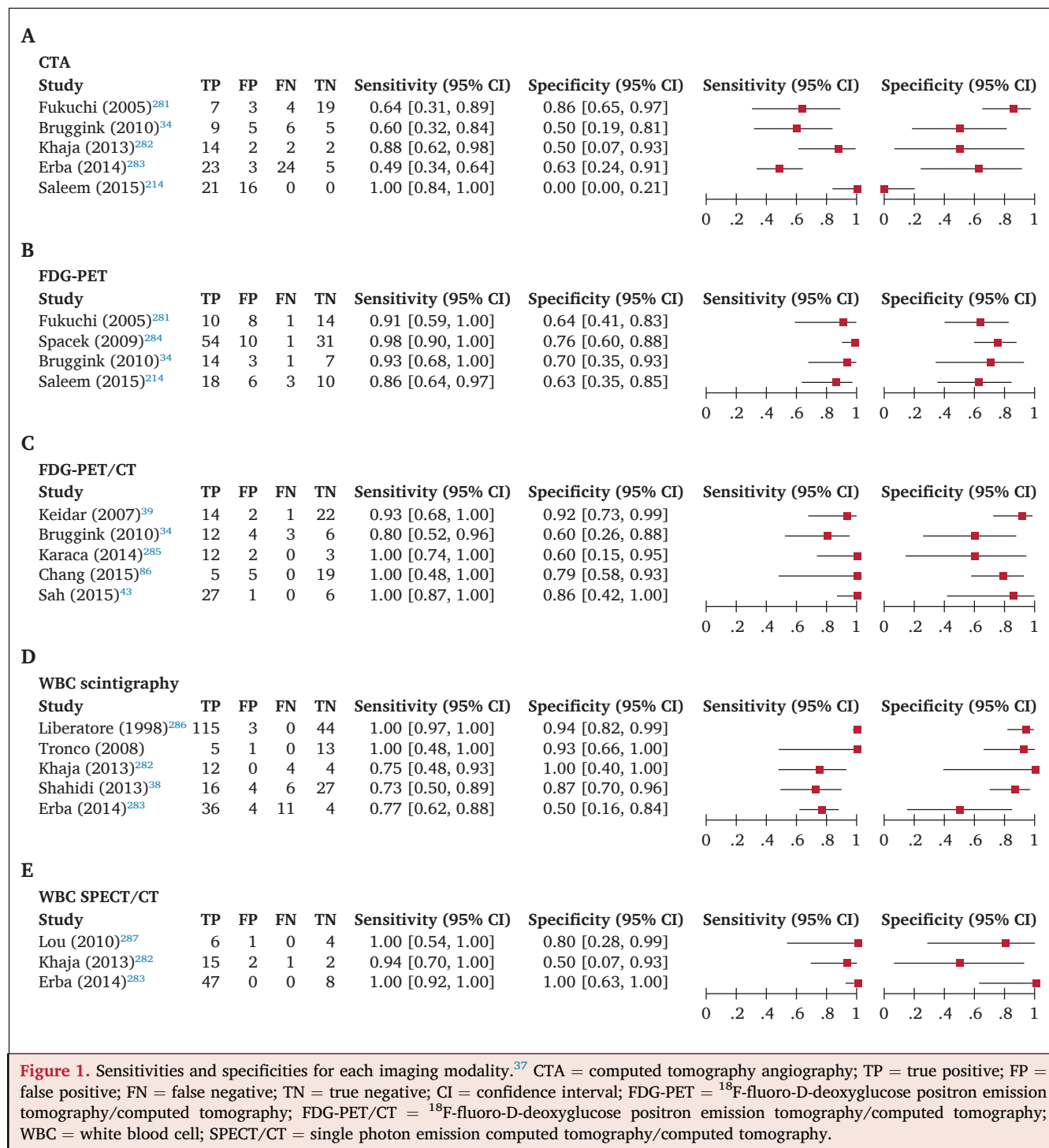
Although better than US, CTA sensitivity and specificity remains moderate and variable.<sup>34</sup> In a systematic review and meta-analysis of patients with suspected VGEI, the pooled sensitivity of CTA in diagnosing VGEI was 0.67 (95% confidence interval [CI] 0.57 – 0.75) and the pooled specificity was 0.63 (95% CI 0.48 – 0.76). This meta-analysis showed that an isolated CTA does not provide enough evidence to establish the diagnosis of VGEI (Fig. 1).<sup>37</sup>

Standalone CTA can confirm the diagnosis of VGEI, but a second imaging modality such as 18F-FDG-PET/CT or WBCS combined with SPECT/CT may be useful to map the extent of the infection.

**2.8.2.3. Magnetic resonance angiography.** MRA has not been evaluated as extensively as CTA for the diagnosis of VGEI, but several studies have suggested that MRA offers better anatomical and functional information than CTA, including tissue characterisation.<sup>14,35</sup> Simultaneous or sequential acquisition of 18F-FDG-PET with MRA provides additional quantitative molecular functional information concerning the inflammatory lesion, and accurate localisation, as well as anatomical changes with motion correction. After six post-operative weeks, the presence of collections with a hypo-intense signal in T1 and a hyperintense signal in T2 strongly suggests a VGEI.<sup>14,35</sup>

In a series of patients with suspected aortic VGEI, the sensitivity of MRA was 0.68 (95% CI 0.50 – 0.86), and the specificity 0.97 (95% CI 0.91 – 1.00).<sup>38</sup> However, owing to low availability and long acquisition times resulting in motion artefacts, MRA is currently not used as a first line diagnostic modality if VGEI is suspected.

**2.8.3. Nuclear imaging techniques.** Nuclear medicine imaging techniques, such as 18F-FDG-PET combined with (low



dose or contrast enhanced) CT and WBCS combined with SPECT/CT, incorporate anatomical and metabolic information at the same time and are able to differentiate between VGEL, soft tissue infection, and, in some cases, inflammation by pattern recognition, heterogeneity, and intensity of uptake with FDG-PET,<sup>39</sup> and by increase in size or intensity with time with WBCS.40

**2.8.3.1. Positron emission tomography.** 18F-FDG-PET imaging is based on the uptake of radioactive labelled glucose in

cells/tissue with enhanced glucose metabolism, such as inflammatory cells and micro-organisms such as bacteria or fungi. This diagnostic method may differentiate between peri-prosthetic collection and involvement of the graft material but should be combined with low dose CT for anatomical correlation. Nowadays, 18F-FDG-PET is mainly performed in hybrid mode with FDG-PET/CT, which has an established role in the assessment of suspected VGEL, providing accurate anatomical localisation of the site of infection.

The EANM and Society of Nuclear Medicine and Molecular Imaging published procedural guidelines on how to perform a  $^{18}\text{F}$ -FDG-PET scan for infectious purposes.<sup>41</sup> As the administered dose of  $^{18}\text{F}$ -FDG and time interval between the scan acquisition may cause heterogeneity between studies, the EANM launched a strategy to harmonise  $^{18}\text{F}$ -FDG-PET/CT studies (EANM Research Limited, EARL).<sup>42</sup> There are different ways to analyse and interpret  $^{18}\text{F}$ -FDG-PET/CT studies. The main interpretation criteria are the calculated maximum standardised uptake value (SUVmax), the tissue to background ratio, the pattern of uptake (focal/diffuse), or the visual grading scale.<sup>41,43</sup> It is suggested that SUVmax > 8 in the perigraft area is the cut off value for distinguishing infected grafts from non-infected grafts, but this is based on a small number of patients. It is also considered that linear, diffuse, and homogeneous uptake with projection of the vessel is highly suggestive of infection. Although in the past diabetes and use of antibiotics were supposed to degrade image quality, two recent studies demonstrated that diagnostic accuracy was not affected.<sup>44,45</sup>

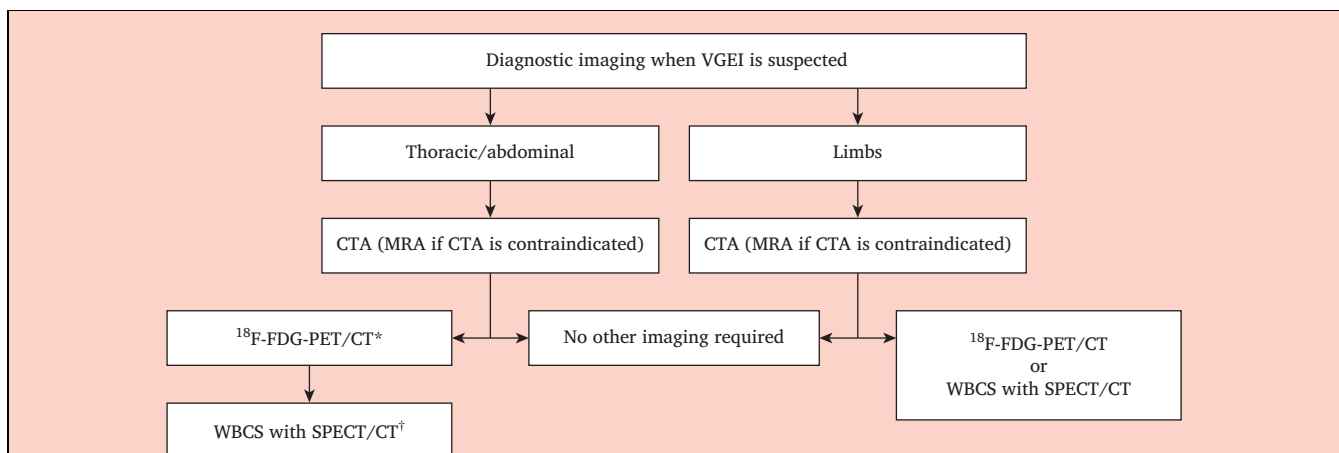
In a meta-analysis, the sensitivity of single  $^{18}\text{F}$ -FDG PET without combined low dose or contrast enhanced CT in diagnosing VGEL in patients with a suspected VGEL was 0.94 (95% CI 0.88 – 0.98), with a specificity of 0.70 (95% CI 0.59 – 0.79).<sup>37</sup>  $^{18}\text{F}$ -FDG-PET combined with CT (adding low dose or contrast enhanced CT) showed even better results, with a sensitivity of 0.95 (95% CI 0.87 – 0.99) and a specificity of 0.80 (95% CI 0.69 – 0.89) (Fig. 1).<sup>37</sup>

**2.8.3.2. White blood cell scintigraphy.** WBCS detects infected sites by visualizing the increase of accumulation of radiolabelled white blood cells over time. Recently, procedural guidelines for the labelling of the white blood cells, and for the correct acquisition and interpretation criteria for WBCS were published.<sup>40</sup> The diagnosis of VGEL infection is

based on the presence of pathological accumulation of labelled white blood cells at the site of infection. At least two sets of images are required (2 – 4 and 20 – 24 hours after injection) and an increase in intensity or size with time is considered positive for an infection. When positive, SPECT/CT images are mandatory for exact localisation of the infection (soft tissue only, graft, or extension).<sup>40</sup>

WBCS is a very specific method, but it has some limitations. The procedure is time consuming and labour intensive, as the imaging needs to be performed at least at two different time points (preferably 2 – 4 and 20 – 24 hours after injection) and in a laboratory specifically equipped to perform leukocyte labelling. Furthermore, the diagnostic accuracy of WBCS depends on the region of the body in which the images are performed. The accuracy is somewhat lower in the central parts of the body than in peripheral parts (so in case of aortic VGEL) as the tracer is eliminated via the intestinal tract and physiologically taken up in the bone marrow, leading to a difficult interpretation of the aorta. Using antigranulocyte antibody scintigraphy as an alternative does not demand laboratory labelling, but does require dual time point imaging and is hampered by physiological uptake in bone marrow and excretion in the intestinal tract.<sup>40</sup> Moreover, the diagnostic accuracy of antigranulocyte antibody scintigraphy is, in general, somewhat lower than WBCS.<sup>40</sup>

The estimated sensitivity of WBCS (without SPECT/CT) in diagnosing VGEL in the most recent meta-analysis was 0.90 (95% CI 0.85 – 0.94) with a specificity of 0.88 (95% CI 0.81 – 0.94).<sup>37</sup> When WBCS was combined with SPECT/CT, the sensitivity increased to 0.99 (95% CI 0.92 – 1.00), with a specificity of 0.82 (95% CI 0.57 – 0.96) (Fig. 1).<sup>37</sup> It is, however, not recommended as the first imaging modality in diagnosing VGEL because of the aforementioned limitations and limited availability (Fig. 2).



**Figure 2.** Imaging workflow if vascular graft/endograft infection (VGEL) is suspected, divided into thoracic/abdominal and limb grafts. CTA = computed tomography angiography; MRA = magnetic resonance angiography;  $^{18}\text{F}$ -FDG-PET/CT =  $^{18}\text{F}$ -fluoro-D-deoxyglucose positron emission tomography/computed tomography; WBCS = white blood cell scintigraphy; SPECT/CT = single photon emission computed tomography/computed tomography. \* $^{18}\text{F}$ -FDG PET/CT can add more information, particularly in inconclusive CT. In some high grade infection cases a second imaging modality as  $^{18}\text{F}$ -FDG PET/CT and/or WBCS combined with SPECT/CT may be useful to map the extent of the infection. †WBCS can be applied if available otherwise,  $^{18}\text{F}$ -FDG PET/CT can be used.

Recommendation 1		
Once vascular graft/endograft infection is suspected, exhaustive evaluation of clinical status, signs of infection and patient comorbidities according to the MAGIC criteria is recommended.		
Class	Level	References
I	C	Lyons <i>et al.</i> (2016), <sup>1</sup> Back (2014), <sup>6</sup> Teebken <i>et al.</i> (2012) <sup>12</sup>

Recommendation 2		
When a vascular graft/endograft infection is suspected, it is recommended that every effort is made to obtain microbiological proof of infection.		
Class	Level	References
I	C	Baron <i>et al.</i> (2013) <sup>21</sup>

Recommendation 3		
To obtain microbiological proof of vascular graft/endograft infection, the yield of at least three deep rather than superficial samples should be considered.		
Class	Level	References
Ila	C	Baron <i>et al.</i> (2013), <sup>21</sup> Padberg <i>et al.</i> (1995) <sup>23</sup>

Recommendation 4		
Microbiological investigation of negative pressure wound therapy foams should not be performed in order to support the diagnosis of vascular graft/endograft infection.		
Class	Level	References
III	C	Scherrer <i>et al.</i> (2016) <sup>37</sup>

Recommendation 5		
Sonification of intra-operatively harvested graft material may be considered in order to improve the micro-organism detection rate.		
Class	Level	References
Ilb	C	Wengrowitz <i>et al.</i> (1991) <sup>30</sup>

Recommendation 6		
For patients suspected of vascular graft/endograft infection, the use of ultrasound as the sole diagnostic modality is not recommended.		
Class	Level	References
III	C	Bruggink <i>et al.</i> (2011) <sup>34</sup>

Recommendation 7		
For suspected vascular graft/endograft infection, CTA is recommended as the first line diagnostic modality.		
Class	Level	References
I	B	Reinders Folmer <i>et al.</i> (2018) <sup>37</sup>

Recommendation 8		
For patients suspected of vascular graft/endograft infection, if CTA is contra-indicated, the use of MRA may be considered.		
Class	Level	References
Ilb	C	Shahidi <i>et al.</i> (2007) <sup>38</sup>

Recommendation 9		
For patients with a clinical suspicion of vascular graft/endograft infection and with non-convincing findings on CTA, the use of 18F-FDG-PET combined with low dose CT is recommended as an additional imaging modality to improve diagnostic accuracy.		
Class	Level	References
I	B	Reinders Folmer <i>et al.</i> (2018) <sup>37</sup>

Recommendation 10		
In patients with a clinical suspicion of peripheral vascular graft/endograft infection, single photon emission computed tomography, if available, is recommended as an additional imaging modality to improve diagnostic accuracy.		
Class	Level	References
I	B	Reinders Folmer <i>et al.</i> (2018) <sup>37</sup>

### 3. STRATEGIES TO PREVENT GRAFT OR ENDOGRAFT INFECTION

#### 3.1. Raw materials

Currently, vascular devices are mainly made of two different polymers, PET or expanded polytetrafluoroethylene (ePTFE) for soft materials, and different alloys, nitinol being the most used, for stents. The choice of these polymers and alloys is mainly related to their chemical and mechanical stability, rather than their properties for inhibiting micro-organism colonisation. They can be implanted as raw materials or associated with different adjuncts such as matrices of impregnation or surface treatment. There is no strong evidence on differences of susceptibility to infection of synthetic vascular raw biomaterials. Differences of susceptibility to infection between PET and ePTFE have been evaluated *in vitro* and *in vivo* with conflicting results. *In vivo* studies did not find differences in infectability between PET and ePTFE materials,<sup>46–48</sup> or less adherence of bacteria for ePTFE than for PET.<sup>49</sup> Although all bacteria are able to adhere to an inert support, some bacteria, such as coagulase negative staphylococci (e.g., *S. epidermidis*) or streptococcus viridans (e.g., *Streptococcus mitis oralis*), show a high propensity for adhesion to foreign materials.<sup>50</sup> No significant difference has been found *in vivo* between PET and glutaraldehyde treated bovine pericardium, used as aortic patches, to resist bacterial infection.<sup>51</sup> Geometric configuration, early plasma protein adhesion, and healing sequence can influence the risk of bacterial adherence with subsequent infection.<sup>52</sup> Bacterial strains demonstrated a greater affinity to

velour knitted PET than to ePTFE grafts.<sup>51</sup> No difference of susceptibility to infection between different alloys currently used for stents or stent grafts has been demonstrated.<sup>48</sup>

### 3.2. Logistics and peri-operative care

**3.2.1. *Staphylococcus* nasal carriage.** The high prevalence of nasal carriage of *S. aureus* in the general population and its role in potentially severe VGEIs raises the question of the beneficial effect of its decolonisation in patients undergoing vascular surgery.<sup>53</sup> In a prospective study, *S. aureus* nasal carriage using a PCR technique was not different in patients with or without post-operative SSIs.<sup>54</sup> In another prospective study, patients undergoing aorto-iliac surgery were screened for *S. aureus* nasal carriage and, if positive, were treated with mupirocin nasal ointment and chlorhexidine body washes, and compared with a historical control group of patients who tested positive but received no treatment. The incidence of *S. aureus* SSI was significantly lower in patients who were screened positive and who were treated for methicillin resistant *S. aureus* (MRSA) nasal carriage compared with patients negative for nasal MRSA carriage (0% vs. 13.6%).<sup>55</sup> In addition, both 30 day mortality re-intervention rates were significantly lower in the treated group (1.3% vs. 13.6%).<sup>55</sup> Of note, *S. aureus* eradication in this setting was associated with a decrease in *S. aureus* related SSIs but not in the SSIs due to other bacteria, which may be explained by the competing behaviour of bacteria causing SSI.<sup>55</sup>

### 3.2.2. Peri-operative care

**3.2.2.1. Shower regimen and hair removal.** In a meta-analysis, there was no evidence of any benefit from a pre-operative bathing or shower regimen with antiseptic agents over unmedicated bathing.<sup>56</sup>

A number of measures have been found to reduce the risk of SSI of 51% in patients undergoing open and endovascular elective surgery or elective lower limb amputation: peri-operative normothermia; hair removal the day before surgery; and discipline in aseptic care in the operating room.<sup>57</sup>

**3.2.2.2. Antimicrobial prophylaxis.** In a meta-analysis, antimicrobial prophylaxis with broad spectrum systemic antibiotics significantly reduced the risk of wound infection and early graft infection in arterial reconstructions (relative risk [RR] 0.25, 95% CI 0.17 – 0.38; and RR 0.31, 95% CI 0.11 – 0.85, respectively).<sup>56</sup> In all patients undergoing open or endovascular abdominal aortic aneurysm repair, therefore peri-operative systemic antimicrobial prophylaxis is recommended.<sup>58</sup> However, antimicrobial prophylaxis for more than 24 hours does not seem to bring any additional benefit.<sup>56</sup>

Antimicrobial prophylaxis for vascular surgery should cover the bacteria most likely to be responsible for SSIs and achieve adequate tissue levels at the time of incision and throughout the procedure to prevent any bacterial

colonisation of injured skin/soft tissue and implant. First or second generation cephalosporins are the most widely used agents owing to their profile of tolerance and antibacterial spectrum that cover methicillin susceptible staphylococci (i.e., *S. aureus* and coagulase negative staphylococci), streptococci, and some Gram negative bacilli. A meta-analysis of 22 RCTs concluded that prophylactic systemic antibiotics for patients undergoing peripheral arterial reconstruction reduced the risk of SSI (RR 0.25, 95% CI 0.17 – 0.38) and early VGI (RR 0.31, 95% CI 0.11 – 0.85).<sup>56</sup> In the same study, no difference in the protective effect on SSI rate was noted between first or second generation cephalosporins, penicillins with lactamase inhibitors, aminoglycosides, or vancomycin.<sup>56</sup>

The coverage of MRSA and/or coagulase negative staphylococci may be considered according to the local prevalence of these strains, even though no significant difference concerning SSI rates using cefazolin plus vancomycin or daptomycin vs. cefazolin alone has been found.<sup>59,60</sup>

Antibiotic prophylaxis has the best efficacy when administered before the incision (ideally within 30 min) with re-injection for longer interventions according to the half life of the compound (i.e., two hours for cefuroxime and four hours for cefazolin).<sup>56</sup>

**3.2.2.3. Gloves.** A prospective RCT did not establish the benefit of intra-operative glove change before handling prosthetic grafts.<sup>61</sup>

**3.2.2.4. Wound closure.** In a retrospective study including all SSIs after lower extremity revascularisation procedures between 2012 and 2016, meticulous wound closure with a monofilament absorbable suture has been shown to be superior to staples in decreasing SSI rates.<sup>62</sup>

### 3.3. Antibiotic prophylaxis during dental extraction

Beyond the peri-operative risk of SSI, the implant can be infected at any time after the intervention, especially in the presence of bacteraemia (i.e., secondary haematogenous related to SSI). Analogous to prosthetic cardiac valves, antibiotic prophylaxis after VG for secondary infection may follow the recommendations of the ESC and American College of Cardiology/American Heart Association.<sup>63</sup> In their most recent guidelines, antimicrobial prophylaxis was recommended for patients with a prosthetic cardiac valve for high risk procedures such as dental procedures involving the manipulation of the gingival or peri-apical region of teeth or perforation of the oral mucosa, including scaling and root canal procedures.<sup>63</sup> Antibiotic prophylaxis has therefore been proposed recently for those patients with an aortic prosthesis, whether placed by open surgical repair or endovascular aneurysm repair (EVAR), before any dental procedure involving the manipulation of the gingival or peri-apical region of teeth or perforation of the oral mucosa, including scaling and root canal procedures.<sup>58</sup>

Recommendation 11		
In every case where a vascular graft/endograft is implanted, antimicrobial prophylaxis to cover the first 24 hours, by intravenous administration of a first/second generation cephalosporin or vancomycin in the event of penicillin allergy, is recommended.		
Class	Level	References
I	A	Stewart <i>et al.</i> (2007) <sup>56</sup>

Recommendation 12		
Before implantation of any vascular graft/endograft, elimination of any potential source of sepsis, especially of dental origin, should be considered.		
Class	Level	References
Ila	C	Habib <i>et al.</i> (2015) <sup>63</sup>

Recommendation 13		
Antimicrobial prophylaxis to prevent vascular graft/endograft infection should be considered before any dental procedure involving the manipulation of the gingival or peri-apical region of teeth or perforation of the oral mucosa, including scaling and root canal procedures for patients previously operated on with a vascular/endovascular graft.		
Class	Level	References
Ila	C	Habib <i>et al.</i> (2015) <sup>63</sup>

## 4. GENERAL THERAPEUTIC STRATEGIES

In view of the rarity of VG/EG, the complexity of diagnosis and treatment, and the difficulty of the interventions and severity of complications, centralisation of the patients suffering from VG/EG is clearly indicated. Accordingly, patients should be transferred to specialised high volume centres with multidisciplinary experience in VG/EG, including angiologists, vascular, cardiovascular and general surgeons, microbiologists and radiologists.

### 4.1. Antimicrobial therapy

**4.1.1. Choice of antimicrobial therapy.** Antimicrobial therapy is an integral part of VG/EG treatment. In the acute phase intensive antimicrobial therapy with broad spectrum antibiotics or antibiotics directed against the most likely infecting organisms is indicated to control infection and sepsis. In the choice of antimicrobial therapy the fact that the graft material may be covered with a biofilm and also the local epidemiology of resistance patterns have to be considered. In some specific situations, the addition of antifungal agents should be considered, especially in visceral fistula cases. Once the responsible infecting organisms are known the spectrum should be narrowed if possible.

**4.1.2. Duration of treatment.** There is no consensus on the optimal length of antimicrobial therapy for VG/EG. If

prosthetic material can be removed and a thorough debridement of all infected tissue can be performed, a minimum of two weeks of intravenous therapy, if possible, followed by an oral regimen for another two to four weeks is indicated. If the infected material is replaced by a new VG, four to six weeks of intensive antimicrobial therapy is usually proposed to prevent recurrent infection. Many authors favour a total treatment time of three to six months in this situation, and some even advocate one year of treatment. In those patients in whom general conditions preclude any surgery, lifelong treatment should be considered.<sup>64,65</sup> This can be an option in patients at higher risk of surgery, especially in low grade infections with less virulent infecting organisms, susceptible to suitable antibiotics, and without other complications. In some cases, the infection cannot be totally eradicated but kept under control by year long or even lifelong therapy.<sup>66</sup>

**4.1.3. Antimicrobial therapy management.** Because of the complexity of interpreting microbiological tests results and the permanent evolution of antimicrobial therapies and micro-organism resistance, antimicrobial therapy management must be done by an infectious diseases specialist within a multidisciplinary team, including vascular surgeons, radiologists, microbiologists, anaesthetists, and gastrointestinal and pulmonary specialists for cases with a concomitant fistula.<sup>65,67</sup>

**4.1.4. Isolation.** Patients with multidrug resistant (MDR) bacteria (such as MRSA, but not methicillin resistant coagulase negative staphylococci, extended spectrum beta lactamase producing Enterobacteriaceae, or glycopeptide resistant enterococci) should be isolated and should remain isolated during the hospital stay as carriage is prolonged, especially in patients receiving antibiotics. The wearing of gloves is required for the manipulation of any biological material, but this is not specific to MDR bacteria (gown for any contact with the patient, mask if pulmonary colonisation or infection). Both colonised and infected patients with these bacteria should be managed in a single patient room to reduce the risk of spread to other patients.<sup>68</sup>

### 4.2. Surgical principles

Historically, total removal of the infected VG or EG, debridement and rinsing with antiseptic solution of the infected area, and extra-anatomic reconstruction (EAR) outside the infected field was considered as the gold standard to avoid recurrent infection. This procedure should be performed in two stages when possible. However, this approach is not always feasible, often not easy, and increases the risk of complications like stump blowout. Therefore, most authors now prefer an *in situ* reconstruction (ISR) with infection resistant material combined with removal of the infected graft material, aggressive debridement of the arterial bed and targeted antimicrobial therapy.<sup>67,69</sup> In most situations the

results with ISR are at least equivalent to extra-anatomic repair.

In thoracic and abdominal procedures especially, it is recommended that any VG and anastomosis should be covered with viable tissue such as omentum, muscle, or pericardial patch.<sup>70</sup> Direct contact with viscera or organs should also be avoided. If no viable tissue is available, a bovine pericardial patch can be used. Anastomoses or suture lines can be reinforced with fascia or pledgets.

Recommendation 14		
Antimicrobial therapy is recommended in every patient with an infected graft/endograft.		
Class	Level	References
I	B	Darouiche (2004), <sup>65</sup> Revest et al. (2015) <sup>67</sup>

Recommendation 15		
For the diagnosis and treatment of vascular graft/endograft infection it is recommended that the patient be transferred to specialised high volume centre with multidisciplinary experience in this pathology.		
Class	Level	References
I	C	Consensus of expert opinion

## 5. SUPRA-AORTIC TRUNKS

### 5.1. Specific aspects

**5.1.1. Incidence.** The exact incidence of VGEI in the supra-aortic trunks (SAT) is unknown, but probably extremely low. SAT VGEI includes prosthetic patch, bypass, and stent graft infections.<sup>71</sup> However, infection rates might be underestimated, owing to lack of recognition and under reporting, as in other locations.

Over the last three decades, a total of 140 cases of SAT patch/bypass infections have been reported, mostly involving carotid patches. An overall incidence of 0.25% – 0.5% was reported in a systematic review of carotid endarterectomies involving PET patches.<sup>72</sup> Because of its infrequent occurrence, it is difficult to identify the aetiology of SAT EG or endograft infection (EGI), but haematoma could be a risk factor in promoting the development of early infection.<sup>73,74</sup>

The incidence of SAT EGI is low, with an estimated incidence of less than one EGI in 10 000 cases.<sup>75</sup> A systematic review of the literature identified only 12 patients with SAT stent graft infections in the last three decades: eight patients presented with infected carotid stent graft, three with infected subclavian stent graft, and one with an infected tandem brachiocephalic and subclavian artery stent graft.<sup>71</sup>

**5.1.2. Clinical presentation.** Half of all reported infections occurred within the first four post-operative months and involved carotid patches. The most common clinical presentation for early infection is abscess, neck mass, and haemorrhage. When infection presents later, the main symptom is a draining sinus. Patients with SAT stent graft infection typically present with fever, malaise, and pain. SAT stent graft infection is mostly encountered after stent graft implantation for carotid blowout syndrome.<sup>76,77</sup> However, it is often a diagnosis of exclusion after other sources of bacteraemia are excluded or inconclusive.<sup>72,74,78</sup> In the setting of early post-operative infection, *S. aureus* is the most commonly encountered micro-organism, while *S. epidermidis* is the predominant pathogen in patients who present with late infections.<sup>71,79</sup>

**5.1.3. Specific diagnostic modalities.** US allows the evaluation of the patency of the revascularisation, the presence of a collection, and its characterisation. It has been highlighted that carotid patch corrugation on US might be an early warning sign of VGI.<sup>80</sup> CTA in combination with cerebral CT may show pseudo-aneurysm formation, abscess, thrombosis or perivascular stranding, and brain abscesses.<sup>81</sup>

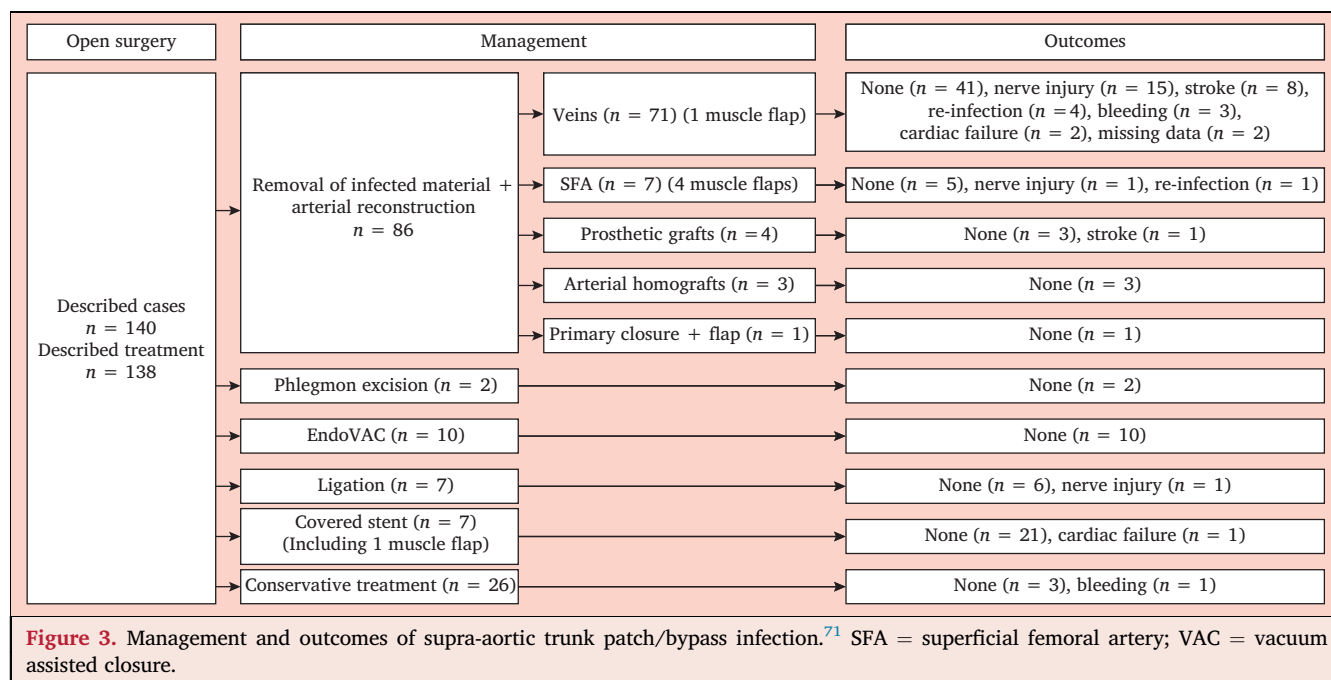
### 5.2. Treatment options for supra-aortic trunk vascular graft/endograft infection

**5.2.1. Conservative treatment.** Conservative treatment of SAT VGEI is not recommended in patients fit for intervention because of the risk of suture line rupture for patch/bypass and vascular wall necrosis for stent graft, potentially leading to uncontrollable major bleeding in the chest and tracheal compression in the neck. However, successful conservative treatment of the infected stent graft using parenteral antimicrobial therapy alone has been described.<sup>75</sup>

**5.2.2. Endovascular treatment.** Endovascular treatment is also an option for SAT VGEI. It is mostly used in life threatening presentations in order to control a major bleeding related to VGEI.<sup>82</sup> For acute bleeding related to blowout syndrome, open surgery in an irradiated area may be challenging, and emergency operative ligation may be associated with high rates of major morbidity, meaning that an endovascular approach is usually preferred. A systematic review and meta-analysis including 559 patients demonstrated that both coil embolisation and reconstruction with stent grafts may be safe treatment options for carotid blowout syndrome: peri-operative mortality was 3% for patients treated by carotid embolisation and 12% for patients treated with covered stent grafts, while the peri-operative stroke rate was 1% in both groups.<sup>83</sup>

The stent graft first strategy can also be considered as a bridge to definitive therapy in unstable patients. This





strategy allows a controlled and semi-elective graft revision, including excision and reconstruction. Patients should receive intravenous broad spectrum or microbiology based antimicrobial therapy, followed by long term treatment.

The endo vacuum assisted closure (VAC) technique is a hybrid approach that has been used in 10 cases of infected SAT reconstructions. The EndoVAC technique is a three step procedure: relining of the infected reconstruction with a stent graft; removal of the infected VG without clamping; and use of NPWT to permit granulation.<sup>84,85</sup> This technique provided good results but was performed in few patients selected on an individual basis for the treatment as they had severe comorbidity and adverse anatomy, providing limited evidence.

### 5.2.3. Reconstruction

**5.2.3.1. Graft material.** A surgical approach with total explantation of infected foreign material is recommended in the elective setting only. Replacement of the explanted bypass/patch or arterial segment is usually mandatory to avoid cerebral ischaemia or infarction. However, primary ligation of the vessel may be considered in emergency life threatening situations, if the infected reconstruction is already thrombosed without neurological symptoms or with an already completed cerebral infarct, to avoid revascularisation syndrome and cerebral haemorrhage.<sup>86</sup>

Autologous material is usually considered as the first line option for reconstruction. Because of the typically short length of these reconstructions, autologous saphenous vein reconstruction (bypass or patch) can be performed in the majority of cases.<sup>79,87,88</sup>

**5.2.3.2. Partial or total explantation.** A direct surgical approach with total explantation of the foreign material is mostly performed in non-emergency conditions in an

attempt to avoid emergency procedures for life threatening haemorrhage in the neck or chest. Usually, bypasses and arterial segments with infected patches or stent grafts are short, except bypasses starting from the ascending aorta.<sup>89</sup> Consequently total explantation is usually performed. Obtaining proximal arterial control is mandatory, even using an occlusion balloon or at an unscarred site through a sternotomy or a thoracotomy, in order safely to enter the cervical phlegmon and minimise peri-operative complications.<sup>90</sup>

The approach that involves proximal arterial control is even more relevant in cases with active bleeding due to infection associated arterial wall breakdown.<sup>90–92</sup> Indeed, primary arterial control through the same cervical incision may be difficult, with the risk of significant blood loss and increased inadvertent peripheral nerve injuries.

Partial explantation with local wound debridement is less often performed.

**5.2.3.3. Adjunctive therapy.** A muscle flap may be considered as a possible adjunctive option for SAT VGEL infection. Sternocleidomastoid or pectoralis major muscle flaps have been reported in 11 cases following SAT patch/bypass infections. Of these 11, seven flaps were following complete removal of the infected material and arterial reconstruction, while four flaps were combined with local wound debridement.<sup>93–96</sup> None of the 11 patients died from a related cause. Of the seven patients who underwent complete removal of the infected material and arterial reconstruction, one stroke and two transient nerve injuries were reported. Of the four patients who underwent local wound debridement, one pseudo-aneurysm occurred requiring the placement of a covered stent.

### 5.3. Follow up and prognosis

Over the last three decades, 140 cases of SAT patch/bypass infections have been reported and 138 treatment modalities described: total removal of infected material and arterial reconstruction in 86 cases; phlegmon excision in two cases; the EndoVAC technique in 10; ligation in seven; endovascular treatment using covered stent grafts in seven; and conservative treatment in 26 cases.<sup>71</sup> Peri-operative complications occurred in 27.9% of cases. Six patients died from related causes with a median follow up of 36 months (Fig. 3).<sup>71</sup>

Of the 12 cases of SAT stent graft infections reported over the last three decades, 11 treatment modalities were described: stent graft removal and arterial reconstruction in six cases; stent graft removal without arterial reconstruction in two cases; carotid embolisation in two cases; and conservative treatment in one case. Peri-operative complications were described in 54.6% of cases. Median follow up was 4.5 months, and five patients died from related causes (Fig. 4).<sup>71</sup>

Recommendation 16		
When patch corrugation is found on ultrasound follow up after carotid endarterectomy further investigations may be considered to exclude a vascular graft infection.		
Class	Level	References
IIB	C	Lazaris <i>et al.</i> (2005) <sup>80</sup>

Recommendation 17		
For patients with supra-aortic trunk vascular graft/endograft infection, total removal of infected material followed by reconstruction with autologous material is recommended.		
Class	Level	References
I	C	Lejay <i>et al.</i> (2018), <sup>71</sup> Son <i>et al.</i> (2014), <sup>79</sup> Grazziotin <i>et al.</i> (2002), <sup>87</sup> Kaviani <i>et al.</i> (2006) <sup>88</sup>

Recommendation 18		
The EndoVAC technique may be considered as a treatment option in selected patients with supra-aortic trunk vascular graft/endograft infection when neither total removal of infected material nor when usual conservative VAC therapy are considered feasible or safe.		
Class	Level	References
IIB	C	Kragsterman <i>et al.</i> (2011), <sup>84</sup> Thorbjornsen <i>et al.</i> (2016) <sup>85</sup>

Recommendation 19		
In the emergency setting with active bleeding in patients with supra-aortic trunk vascular graft/endograft infection, a combined endovascular and surgical approach may be considered.		
Class	Level	References
IIB	C	Younis <i>et al.</i> (2006) <sup>82</sup>

### Recommendation 20

Conservative treatment, including antimicrobial therapy without reconstruction, for supra-aortic trunk vascular graft/endograft infection may be considered for patients unfit for surgery.

Class	Level	References
IIB	C	Myles <i>et al.</i> (2000) <sup>75</sup>

## 6. THORACIC/THORACO-ABDOMINAL AORTA

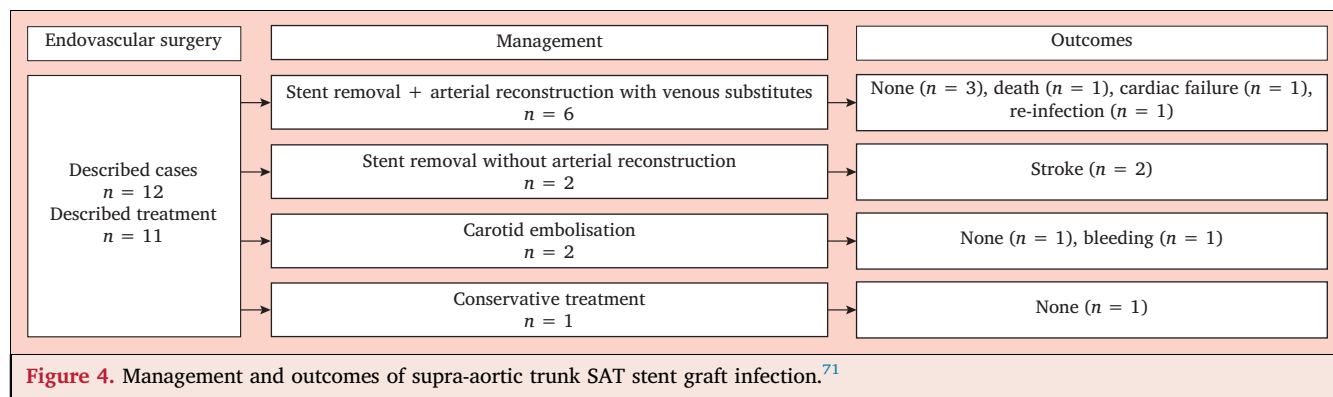
### 6.1. Specific aspects

**6.1.1. Incidence.** The frequency of thoracic aortic VGEI is reported to be up to 6%, with mortality rates, depending on the clinical presentation, of up to 75%.<sup>15,64</sup> Together with the increasing number of procedures performed on the thoracic aorta, including thoracic EVAR (TEVAR), the incidence of thoracic VGEI is also increasing. Additionally, thoracic VGEI is often associated with AEsF, ABF, or aorto-pulmonary fistula (APF), which makes treatment more complicated, with the need (besides the aortic reconstruction) for adjunctive surgical procedures to repair the oesophageal or bronchial lesion.<sup>97–99</sup>

A systematic review identified 43 studies reporting on 233 patients with 49 VGI and 184 EGI. Only four were multicentre studies, which included 107 patients, all with EGI. The remaining 39 single centre studies included 49 patients with VGI and 77 with EGI.<sup>100</sup> In two large registries on complications after TEVAR, the incidence of AEsF was estimated to be 1.7% and 1.5%, respectively.<sup>97,99</sup> In a systematic review, the association with AEF was significantly more frequent (60% vs. 31%) and the time interval from index procedure to infection was significantly shorter (17 ± 21 months vs. 32 ± 61 months) with EG compared with VG, respectively.<sup>100</sup>

**6.1.2. Clinical presentation.** The clinical symptoms of thoracic aortic VGEI can range from unexplained fever, as observed in post-implantation syndrome, to sepsis, massive bleeding, and shock. Owing to the depth of the thoracic aorta, visible local signs of infection are mostly absent. Septic emboli can cause secondary loci of infection or even abscesses. For AEsF or ABF, haematemesis or haemoptysis may be the first symptom. This bleeding may be massive, especially for AEsF but is often preceded by self limiting “herald bleeding”.

**6.1.3. Specific diagnostic modalities.** Definite diagnosis mostly demands a CTA showing perigraft fluid, air in the aneurysm sac or surrounding it, or abscess formation in the surrounding tissues.<sup>1,8</sup> 18F-FDG-PET/CT should be performed when low grade infection is suspected but not confirmed by CT.<sup>43</sup> When an AEsF is present, the prosthetic material may be seen protruding in the oesophagus on oesophagoscopy. In case of an ABF the defect in the bronchus can only be seen when it is centrally located, e.g., in the left main bronchus. Diagnostic examinations should



be performed without delay when infection of a thoracic aortic VGEI is suspected.<sup>66</sup>

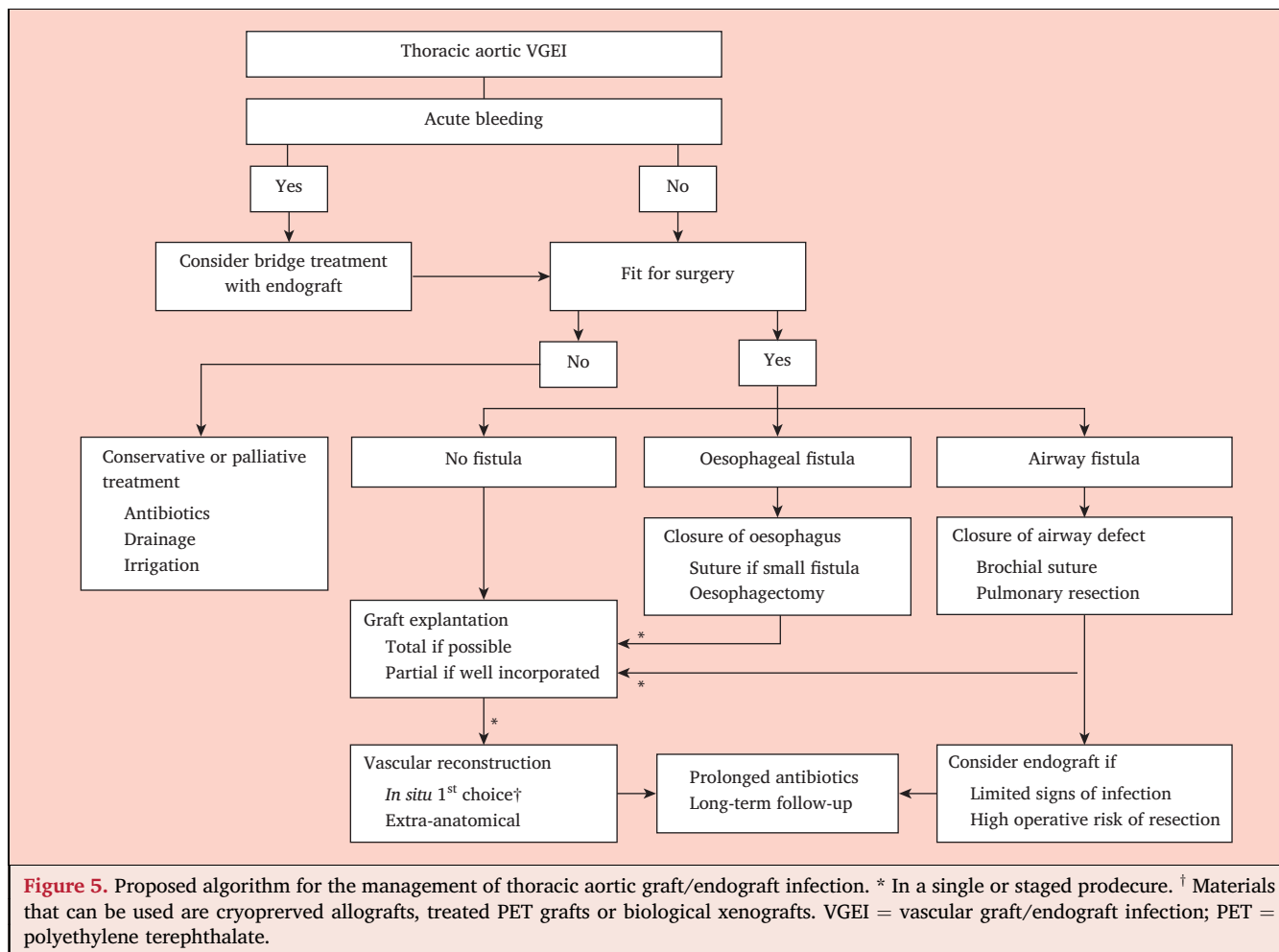
**6.2. Thoracic vascular graft/endograft infection without fistula**

**6.2.1. Conservative treatment.** Although surgical principles dictate control of sepsis, removal of all infected prosthetic material, and reconstruction in a clean field, this is not always achievable because it places a huge burden on an already sick patient (Fig. 5). Therefore,

staged repair or conservative treatment are the only options.<sup>101</sup>

**6.2.1.1. Percutaneous drainage.** In the presence of peri-graft fluid collections or abscesses, percutaneous drainage under ultrasound or CT guidance can be performed in combination with antimicrobial therapy. A 10 – 14 F pigtail catheter or a 12 – 20 F drain is inserted percutaneously and left in place until the collection is totally or sufficiently drained.

**6.2.1.2. Irrigation.** Irrigation with saline or an antiseptic solution can be used in order to dilute the bacterial burden



in prosthetic and peri-prosthetic tissues. It can be performed through percutaneous drains or after a surgical procedure with aortic reconstruction.<sup>66</sup>

In a systematic review of single centre series, conservative treatment (antimicrobial therapy with or without percutaneously inserted drainage of fluid collections or flushing) was performed in 2% of patients with VGI ( $n = 1/49$ ) and 17% with EGI ( $n = 13/77$ ). The mortality rate was 100% at 30 days in VGI group; and 38% at 30 days, 75% at one year, and 100% at five years in the EGI group.<sup>100</sup>

Five studies provided data on one year mortality in both conservatively ( $n = 12$ ) and surgically ( $n = 42$ ) treated patients.<sup>102–106</sup> One year mortality was 75% and 50%, respectively, without any significant difference.<sup>100</sup>

**6.2.2. In situ reconstruction.** Removal of the infected graft material, aggressive debridement of the arterial bed, and arterial reconstruction with suturing in healthy non-infected tissue using infection resistant material constitute the basis of this treatment modality

**6.2.2.1. Specific techniques.** The operative technique largely depends on the VG or EG location. If the prosthesis extends into the aortic arch, a median sternotomy or a clamshell incision is indicated, and the intervention needs to be performed under total cardiopulmonary bypass, circulatory arrest, and selective cerebral perfusion. If the proximal extent of the VG or EG is distal to the left subclavian artery (LSCA), the procedure can be performed through a left thoracotomy with single lung ventilation and left heart bypass. Dissection of the proximal neck, usually between the left common carotid artery (LCCA) and the LSCA, can be difficult owing to the inflammation caused by the infection or the previous intervention. Care should be taken not to damage adjacent structures, like the lung, vagus nerve, or oesophagus. If extensive reconstructions need to be performed, measures like cerebrospinal fluid drainage may be considered in order to reduce the risk of spinal cord ischaemia. Intraoperative evaluation using motor evoked or somatosensory evoked potentials may also be used. If the VG or EG extends to the level of the LSCA and clamping between the LCCA and the LSCA is not possible, hypothermic circulatory arrest is needed to allow complete prosthetic material excision.<sup>107</sup> When exposure of the thoraco-abdominal aorta is required, a thoracophrenolaparotomy is the preferred approach. As in primary procedures, the splanchnic arteries can be perfused with normothermic blood and the renal arteries with cold crystalloids during cross clamping.

**6.2.2.2. Graft materials.** Cryopreserved aortic allografts have been proposed for the replacement of infected thoracic VG/EG.<sup>102,108</sup> As a biological material, allografts have demonstrated a higher resistance to infection than synthetic VGs, but are exposed to the subsequent risk of degeneration, rupture, and bleeding when the infection is caused by necrotising organisms, such as *P. aeruginosa* or *Candida spp.*<sup>66,109–111</sup> Long term durability results,

especially with regard to the development of calcification and aneurysms when used in the thoracic aorta, are still lacking.<sup>64</sup>

Treated PET VGs, such as rifampicin soaked and silver coated (with or without triclosan) VGs, have been proposed in order to decrease the risk of early infection.<sup>64,66,112</sup> In a series including mainly explanted infected abdominal endografts, treated PET VGs have been shown to provide better results in terms of prevention of re-infection and five year overall survival than standard PET VGs (53% vs. 12%) These results can probably be extrapolated to the TEVAR setting. Bovine pericardium has been reported as a technical option for ISR of thoracic aortic VG/EG, tailoring a custom made tube by sewing pericardial sheets.<sup>113–115</sup> While promoted in case series, this technique still needs further studies and longer follow up.

**6.2.2.3. Adjunctive therapy.** The recommended VG coverage to avoid its direct contact with surrounding organs like lung or oesophagus using the surrounding tissues is often not possible. Therefore, it is advised to cover the VG with other viable tissue. Intercostal flap coverage can be used, as well as pericardial or omental flaps. An intercostal flap has limited volume and is best prepared at the moment of thoracotomy to avoid damage caused by the retractor. When a pericardial flap is used, the pericardial defect may need to be repaired with synthetic material. Omentum can be prepared by laparoscopic access and routed through the diaphragm via the aortic hiatus, to cover the VG and fill a dead space after mediastinal debridement.<sup>66</sup> More extensive muscular flaps, such as latissimus dorsi or serratus muscle have been proposed.<sup>101</sup> If there is no viable tissue available, use of a bovine pericardial patch is suggested.

**6.2.3. Extra-anatomic reconstruction.** To avoid reconstruction in a contaminated field and recurrent infection, EAR outside the infected field and secondary aortic ligation with removal of the infected VG or EG can be performed in one or two stages.

**6.2.3.1. Technique.** To restore distal perfusion after aortic ligation, axillo-bifemoral or bilateral axillofemoral bypasses can be performed, but retrograde blood flow to the visceral organs under all these circumstances may be insufficient.<sup>101</sup> The most commonly used EAR is the so called ventral aorta, consisting of a retrosternally placed VG that originates from the ascending aorta, the distal anastomosis being on the supraceliac abdominal aorta or more distally, on the infrarenal aorta or iliac arteries.<sup>101,116</sup> If possible, this reconstruction is performed in two steps, the first step being the bypass through sternotomy and upper laparotomy, and the second step being the removal of the thoracic VG or EG through thoracotomy.<sup>66</sup> The main limitations of this technique are acute bleeding, or involvement of the aortic arch because of the necessity to intervene first on the infected VG or EG.<sup>100</sup> Depending on the situation, alternative routes can be used, such as a posterior pericardial bypass.

**6.2.3.2. Stump management.** The aortic stump is oversewn and covered with an omental or muscular flap in order to reinforce the stump and diminish the risk of blow out.<sup>101</sup> Typically, the aorta is transected just distal to the LSCA origin or at the level of the diaphragm. Alternatively, staplers can be used to divide the aorta, but these stapled stumps should also be covered with viable tissue, such as pedicled intercostal muscle flap.<sup>101</sup>

**6.2.4. Partial or total graft explantation.** Partial removal of graft material is usually not an option as the whole of the VG or EG needs to be considered to be infected,<sup>109</sup> the only exception being when only part of the VG or EG is documented as being infected through clinical and imaging findings.<sup>109</sup>

In a meta-analysis, the one year mortality was 37% (*n* = 15/41) for graft material explantation vs. 85% (*n* = 17/20) for total or partial graft material preservation.<sup>100</sup> In a systematic review and meta-analysis including 96 patients with infected thoracic endografts (41 EG explantation, 55 EG preservation), in hospital mortality was 37% vs. 42%, while late mortality was 46% vs. 82% for EG explantation and EG preservation, respectively.<sup>117</sup>

Recommendation 21		
For persistent fever or inflammatory symptoms after implantation of a thoracic graft/endograft, further diagnostic investigations are recommended in the search for infection.		
Class	Level	References
I	C	Lyons <i>et al.</i> (2016) <sup>1</sup>

Recommendation 22		
For fit patients with proven thoracic/thoraco-abdominal vascular graft/endograft infection, total graft explantation is recommended.		
Class	Level	References
I	B	Kahlberg <i>et al.</i> (2019), <sup>100</sup> Moulakakis <i>et al.</i> (2013) <sup>117</sup>

Recommendation 23		
For patients with <i>in situ</i> reconstructions of thoracic/thoraco-abdominal vascular graft/endograft infection, coverage of the newly inserted graft with autologous, and ideally vascularised, tissue is recommended.		
Class	Level	References
I	C	Spiliotopoulos <i>et al.</i> (2018), <sup>66</sup> Roselli <i>et al.</i> (2014) <sup>101</sup>

Recommendation 24		
For patients with thoracic vascular graft/endograft infection that are at major risk of surgery, conservative treatment may be considered.		
Class	Level	References
Iib	B	Czerny <i>et al.</i> (2014), <sup>97</sup> Kahlberg <i>et al.</i> (2019), <sup>100</sup> Chiesa <i>et al.</i> (2010) <sup>111</sup>

Recommendation 25		
For patients with suspected thoracic graft/endograft infection, in the absence of fistulisation to the oesophagus or airway, or generalised sepsis, prolonged antimicrobial therapy combined with drainage of peri-graft fluid and/or irrigation, may be considered.		
Class	Level	References
Iib	C	Kahlberg <i>et al.</i> (2019) <sup>100</sup>

Recommendation 26		
For patients with thoracic/thoraco-abdominal vascular graft/endograft infection, partial explantation may be considered if infection is limited.		
Class	Level	References
Iib	C	Kahlberg <i>et al.</i> (2019) <sup>100</sup>

Recommendation 27		
For the reconstruction of thoracic/thoraco-abdominal vascular graft/endograft infection, cryopreserved allografts may be considered the first choice graft material.		
Class	Level	References
Iib	C	Smeds <i>et al.</i> (2016) <sup>110</sup>

Recommendation 28		
After extra-anatomic reconstruction for thoracic/thoraco-abdominal vascular graft/endograft infection, reinforcement of the aortic stump with autologous, and ideally vascularised, tissues should be considered.		
Class	Level	References
Iia	C	Roselli <i>et al.</i> (2014) <sup>101</sup>

**6.3. Thoracic vascular graft or endograft infection with oesophageal fistula**

Thoracic aortic VGEIs associated with AEsF or ABF require a more complex and difficult treatment than those without the presence of a fistula. Even when an aortic VG is resected and the oesophagus repaired, the mortality is twice that of a VGEI without fistula.<sup>117</sup> An AEsF seems to occur more frequently and earlier in the thoracic aorta than in the abdominal aorta and after EG than VG implantation.<sup>110</sup>

Any strategy in this patient population needs to be highly individualised given the risks associated with major thoracic aortic surgery often in a hostile operative field.

**6.3.1. Conservative treatment.** Conservative treatment of an AEsF is almost invariably fatal.<sup>97,99,103,110</sup> Only one conservatively managed case of secondary AEsF after EG implantation without sign of recurrent haemorrhage or chronic mediastinitis at 14 months has been described.<sup>118</sup> Conservative treatment should be considered palliative in patients unfit for major surgery.

**6.3.2. Endovascular treatment as bridging therapy.** In patients presenting active and life threatening bleeding from

an AEsF, emergency EG insertion may be proposed as the primary strategy to control bleeding and restore haemodynamic stability.<sup>119</sup> This approach has been proposed as a “stopgap” strategy. However, it has considerable limitations, mainly related to the inability to eliminate the primary infected material and therefore should be considered mainly as a bridge to definitive treatment.<sup>64</sup>

In a national survey that analysed 25 cases of AEsF and ABF treated by TEVAR, the 30 day mortality rate was 28%. After a follow up of 23 months, overall mortality was 44% and the re-intervention rate due to TEVAR failure was 28%, with an associated re-intervention mortality rate of 60%. Patients treated by TEVAR associated with oesophageal or bronchial repair had a lower mortality than patients treated with TEVAR alone (30% vs. 55%).<sup>99</sup> The European Registry of Endovascular Aortic Repair Complications (EuREC) also showed a statistically significant survival benefit for a radical surgical approach compared with any other treatment strategy in cases of AEsF after TEVAR.<sup>97</sup> Other reports confirmed the idea that patients with VGEI, treated by initial TEVAR and considered unfit for subsequent definitive open surgical repair, had the worst prognosis, with mortality approaching 100% in most series.<sup>64</sup>

To conclude, patients with bleeding due to an AEsF can be treated successfully in the emergency setting by TEVAR, but once they have recovered and conditions are stable, a definitive surgical procedure must be performed to ensure durable results.<sup>100,106</sup>

### 6.3.3. Treatment of the oesophagus

**6.3.3.1. Limited treatment of fistula.** In the presence of an AEsF, both the aortic and oesophageal lesions need to be addressed. To avoid persistent or recurrent infection and/or mediastinitis and fistula recurrence, closure of the oesophageal lesion is needed. This can be performed together with the vascular reconstruction or as an isolated procedure.

Administration of methylene blue through a naso-oesophageal tube can help to localise a small oesophageal lesion. If the lesion is limited, primary oesophageal repair can be accomplished by a double layer of absorbable interrupted stitches to the oesophageal wall. In this case, the oesophageal repair is usually reinforced and covered by a pericardial flap or a previously prepared pedicled intercostal muscle flap.<sup>64</sup> Primary repair of the oesophageal defect always entails the risk of anastomotic leakage and mediastinitis with the subsequent need to remove the oesophagus. Therefore, most authors agree that limited fistula treatment has a limited place in treatment of AEsF.<sup>112</sup>

**6.3.3.2. Radical fistula treatment.** In most cases, the oesophageal lesion cannot be repaired primarily because it is too large, the oesophageal wall is of insufficient quality or ischaemic, or the infection is too extensive. In these situations, more radical treatment with partial or total resection of the oesophagus is indicated. When a staged procedure is used, in a first step (e.g., when a thoracic EG is inserted to control the bleeding) a cervicostomy with closure of the

cervical oesophagus and a nutritional gastro- or jejunostomy is performed. This is followed by removal of the oesophagus and reconstruction with gastric or colonic pull up in a second or third stage.<sup>100</sup>

**6.3.3.3. Oesophageal prosthesis.** The goal of the oesophageal endoprosthesis implantation is to close the fistula from the oesophageal side and prevent further contamination of the mediastinum. It can be performed as a standalone procedure or be combined with aortic stenting in the case of bleeding.<sup>120</sup> In a EuREC report, survival at one year was only 17% with oesophageal stenting alone vs. 43% when oesophagectomy was performed.<sup>97</sup> Therefore, this technique should only be considered in patients unfit for further surgery. Migration of the stent with need for repositioning can occur.<sup>121</sup>

**6.3.3.4. Definitive treatment: one or two stage.** When massive bleeding occurs, insertion of an EG to control the bleeding can be a life saving procedure. Multiple combinations of treatment options have been used to deal with AEsF, including arterial ISR, extra-anatomic bypass with concomitant primary oesophageal repair, or oesophagectomy with cervical oesophagostomy and secondary restoration of gastrointestinal tract continuity.<sup>109,112</sup>

Resection of the oesophagus and restoration of gastrointestinal continuity can be performed in a one stage or two stage procedure. The same applies to the vascular reconstruction and resection of the aortic graft.<sup>105</sup> The choice of strategy to be followed will often depend on the urgency of the situation, the condition of the patient and the possibility of controlling the infection.

Encouraging results were reported in a series of eight patients operated on for AEsF or ABF by means of a staged approach: emergency endovascular exclusion of the aortic rupture, followed by staged open surgical repair of the oesophageal or bronchial lesion and removal of the infected aortic graft with associated intercostal muscle flap interposition. At a mean follow up of 34 months, one death was observed (87.5% overall survival), and no conversion or aortic bleeding was recorded.<sup>122</sup>

In every case, patients should receive intensive medical and nutritional support to get them into a better general condition before being referred for open surgery.<sup>123</sup>

## 6.4. Thoracic vascular graft or endograft infection with airway fistula

In the EuREC registry, the incidence of ABF and APF is 0.56%.<sup>98</sup>

**6.4.1. Endovascular treatment.** Acceptable results have been described after treatment of ABF or APF by TEVAR, with the risk of delayed recurrent fistula or persistent infection, despite EG coverage with a muscle or pleural flap.<sup>124,125</sup> In the EuREC report, 15 patients presented with ABF, predominantly on the left side ( $n = 14/15$ ) and 11 with APF of 4 680 TEVAR procedures. In half of the patients, external compression, mostly due to presence of an endoleak, was considered to be the responsible mechanism.

A systematic review including 134 patients showed that emergency TEVAR for ABF can be performed with 93.2% technical success in the short term, and 5.9% 30 day mortality.<sup>126</sup> Aortic related mortality was 14.3% at 17.4 months, and ABF recurrence was 11.1%.<sup>126</sup> Despite these results, the risk of ABF recurrence and infection of the newly inserted EG remains, as the defect in the respiratory system is not treated.<sup>119</sup>

In a systematic review with meta-analysis of patients that underwent TEVAR for AEsF or ABF, 114 patients were included (71 ABF and 43 AEsF). Patients with AEsF presented more frequently with hypovolaemic shock (33% vs. 13%) and systemic infection (36% vs. 9%) than patients with ABF. In hospital mortality was 3% for ABF and 19% for AEsF. Additional procedures after TEVAR and within the first 30 days were performed in 3% of ABF and 37% of patients with AEsF. Therefore, ABF and AEsF are not comparable and should be considered separately.<sup>127</sup>

**6.4.2. Open surgical treatment.** Open ABF operative mortality ranged from 15% to 41%.<sup>123,128</sup> Open surgical treatment remains the first choice for patients fit for surgery as the EuREC registry showed that a radical surgical approach resulted in significantly better survival (63% at two years) compared with any other treatment strategy.<sup>98</sup>

To decrease the risk of ABF recurrence and re-infection, the bronchial defect needs to be repaired surgically. The defect can be closed primarily or with an intercostal muscle or pericardial flap, but in most cases a bronchial resection and anastomosis or a lung resection (mostly wedge resection) is necessary. After bronchus repair, the EG should be covered with a muscle or pleural flap.<sup>99,123</sup> Sometimes APF can be treated successfully in a more conservative manner by implantation of an EG to control the bleeding, followed by conservative treatment with antimicrobial agents. For persistent infection or recurrent of EG infection, pulmonary resection is indicated.<sup>123</sup>

It is not clear whether the EG always needs to be removed to definitely treat an ABF.<sup>129</sup> In patients fit for surgery, EG removal and *in situ* vascular repair should be considered.<sup>125,126,130</sup>

**6.5. Follow up and prognosis**

Overall mid term mortality ranges from 14.3% to 75% but largely depends on presentation, the condition of the patient, and the treatment that has been given.<sup>64,66,99,105,126</sup> The presence of an AEsF or ABF is a worsening prognostic factor.

Follow up, including inflammatory parameter monitoring and repeated imaging with CTA and/or 18F-FDG-PET/CT, remains indicated for a longer time to detect delayed recurrent infection and the risk of degeneration of cryopreserved allograft when used.

Recurrence or persistent infection and subsequent multi-organ failure due to septic shock are the main reasons for the demise of these patients.<sup>66</sup> Secondary interventions

due to infective or bleeding complications can be needed in up to 50% of patients.<sup>105</sup>

Recommendation 29		
For patients with aorto-oesophageal fistula complicating thoracic/thoraco-abdominal vascular graft/endograft infection, explantation of the infected material, repair of the oesophagus, and coverage with viable tissue is recommended as definitive treatment.		
Class	Level	References
I	B	Kahlberg <i>et al.</i> (2019), <sup>100</sup> Moulakakis <i>et al.</i> (2013) <sup>117</sup>

Recommendation 30		
In the emergency setting with active bleeding complicating thoracic/thoraco-abdominal vascular graft/endograft infection with an aorto-oesophageal fistula, initial treatment with an aortic endograft, as a bridge to definitive treatment, should be considered.		
Class	Level	References
Ia	B	Chiesa <i>et al.</i> (2010), <sup>99</sup> Chiesa <i>et al.</i> (2010), <sup>111</sup> Canaud <i>et al.</i> (2014), <sup>125</sup> Canaud <i>et al.</i> (2014) <sup>130</sup>

Recommendation 31		
Conservative treatment of patients with an aorto-oesophageal fistula complicating thoracic/thoraco-abdominal vascular graft/endograft infection is not recommended, except in a palliative setting.		
Class	Level	References
III	B	Czerny <i>et al.</i> (2014), <sup>97</sup> Chiesa <i>et al.</i> (2010), <sup>99</sup> Smeds <i>et al.</i> (2016), <sup>110</sup> Chiesa <i>et al.</i> (2010) <sup>111</sup>

Recommendation 32		
Treatment of aorto-oesophageal fistula complicating thoracic/thoraco-abdominal vascular graft/endograft infection with an oesophageal endoprosthesis alone is not recommended.		
Class	Level	References
III	C	Czerny <i>et al.</i> (2014) <sup>97</sup>

Recommendation 33		
In patients with aortobronchial or aortopulmonary fistula complicating thoracic/thoraco-abdominal vascular graft/endograft infection, closure of the airway defect and explantation of the infected material with <i>in situ</i> reconstruction should be considered as definitive treatment.		
Class	Level	References
Ia	C	Czerny <i>et al.</i> (2015), <sup>98</sup> Chiesa <i>et al.</i> (2010), <sup>99</sup> Chiesa <i>et al.</i> (2010) <sup>111</sup>

Recommendation 34		
In the emergency setting of active bleeding complicating thoracic/thoraco-abdominal vascular graft/endograft infection with an aortobronchial or aortopulmonary fistula, treatment with an aortic endograft should be considered.		
Class	Level	References
Iia	C	Canaud <i>et al.</i> (2013), <sup>123</sup> Canaud <i>et al.</i> (2013) <sup>126</sup>

Recommendation 35		
For patients with an aortobronchial or aortopulmonary fistula complicating thoracic/thoraco-abdominal vascular graft/endograft infection, preservation of the endograft may be considered after closure of the airway defect and coverage with viable tissue.		
Class	Level	References
Iia	C	Canaud <i>et al.</i> (2013), <sup>123</sup> Canaud <i>et al.</i> (2013) <sup>126</sup>

Recommendation 36		
For all patients treated for thoracic/thoraco-abdominal vascular graft/endograft infection, lifelong follow up is recommended because of the risk of recurrent infections or fistulae.		
Class	Level	References
I	C	Kahlberg <i>et al.</i> (2017), <sup>64</sup> Spiliotopoulos <i>et al.</i> (2018), <sup>66</sup> Kahlberg <i>et al.</i> (2019), <sup>100</sup> Luehr <i>et al.</i> (2014) <sup>105</sup>

## 7. ABDOMINAL AORTA

### 7.1. Specific aspects

**7.1.1. Incidence.** In a large population of 13 902 patients, the two year rate of abdominal aortic VGI was 0.19% after open surgery vs. 0.16% after EVAR, without a significant difference, and 0.2% in both elective and non-elective patients.<sup>53</sup> On the basis of 514 patients, the 30 day incidence was 1.6% (95% CI 0.4% – 2.8%), one year incidence 3.6% (95% CI 1.7% – 5.5%), and two year incidence 4.5% (95% CI 2.4% – 6.6%).<sup>131</sup> EGI is a rare complication, the incidence being < 1%.<sup>132</sup> AEnF was present in 1% – 2% of the reported cases. In an American multicentre registry including 180 infected stent grafts, 43 EGI (23.9%) with an AEnF were reported.<sup>110</sup> In a multicentre study, an AEnF occurred in 32 patients (0.08%).<sup>133</sup> EVAR after anastomotic postsurgical pseudoaneurysm was significantly associated with developing an AEnF.

**7.1.2. Clinical presentation.** Most patients (70%) with abdominal VGEI have pain, fever, and leucocytosis; 33% of patients suffer weight loss, fatigue, or generalised weakness.<sup>132</sup> In a systematic review of the literature conducted in 2016, 216 studies representing 823 patients with AEnF were compiled.<sup>134</sup> Bleeding was the most common

symptom (71.7%), followed by sepsis (39.7%) and haemorrhagic shock (33.1%).

**7.1.3. Specific diagnostic modalities.** In cases of suspected AEnF or haemorrhage, gastroduodenoscopy and/or colonoscopy are indicated. Polymicrobial Gram negative and enteric species, *Candida* spp., or fungi are highly suggestive of an AEnF.

### 7.2. Treatment options

**7.2.1. Conservative treatment.** Conservative treatment, including percutaneous drainage irrigation can be either a preparation for open surgery at a later stage or a definitive palliative strategy in patients unfit for open surgery, owing to comorbidities or their current state of infection (e.g., sepsis). For all conservative strategies, long term or lifelong antimicrobial therapy is important. AEnF or suture line rupture precludes a conservative approach.<sup>135</sup> Conservative management of abdominal aortic VGI is hardly ever possible. Persisting septic complications and rupture are the major drawbacks, with a 30 day mortality rate of 100% in small series.<sup>136</sup>

**7.2.1.1. Percutaneous drainage.** Fluid collections around the aortic VGEI may be amenable to percutaneous drainage. This minimally invasive intervention potentially reduces the local bacterial and infectious burden, and provides directly obtained specimens for microbiological sampling. Image guided insertion of a pigtail catheter into the perigraft space is performed under local anaesthesia. The catheter is connected to a gravity drainage bag, and repeated saline irrigation prevents occlusion. Catheter removal can be considered once drainage output is low and after imaging confirmation of resolution of the fluid collection. A further benefit of drainage is the possibility of performing sinography to rule out enteric fistula. A 30 day mortality rate of 40% in infrarenal VGEI treated with percutaneous drainage alone has been reported.<sup>137</sup> Its role in the eradication of aortic VGEI remains controversial.

**7.2.1.2. Irrigation.** Irrigation of the infected perigraft space can be started once a drainage catheter has been inserted. Mainly earlier reports (published before 1997) on the use of povidone iodine solution, antibiotic solution, gentian violet, and saline solution are available. A few case reports with limited follow up data and no comparison of the irrigation solutions address this technique.<sup>138,139</sup>

**7.2.2. In situ reconstruction.** ISR includes complete removal of the infected material with reconstruction in the infected field, and can be done with autologous veins, cryopreserved allografts, rifampicin bonded or silver coated synthetic grafts, and xenogenous grafts.

**7.2.2.1. Specific techniques.** For treatment, surgeons need to decide for each patient individually. Whatever the type of reconstruction chosen, removal of the infected material is necessary at a certain point. The first step of this intervention consists of securing the aortic clamping zone.<sup>140</sup> For



**Table 7. Autologous vein reconstruction of abdominal aortic vascular graft infection: a literature overview**

Author	Publication date	Study type	n	Follow up – mo	Early mortality – %	Late mortality – %	Amputation rate – %	Graft occlusion – %	Re-infection – %	Graft rupture – %
Cardozo <i>et al.</i> <sup>267</sup>	2002	Retrospective	12	22	15.3	15.3	16.7	NA	0	NA
Daenens <sup>268</sup>	2003	Prospective database	49	41	8	NA	2	4	0	NA
Beck <sup>269</sup>	2008	Retrospective	240	59	NA	NA	NA	6	NA	NA
Ali <i>et al.</i> <sup>145</sup>	2009	Prospective database	165	32	10	33	7.4	0	5	5
Aavik <sup>270</sup>	2008	Retrospective	11	59	0	0	18.2	9.1	0	NA
Ehsan and Gibbons <sup>223</sup>	2009	Retrospective	46	48	4.3	30	7	9	4	NA
Batt <i>et al.</i> <sup>137</sup>	2012	Retrospective	6	41	NA	NA	0	0	16	NA
Dorweiler <i>et al.</i> <sup>142</sup>	2014	Retrospective	67	60	9	55	6	3	0	NA
Charlton-Ouw <i>et al.</i> <sup>177</sup>	2015	Retrospective	11	42	0	9	27	NA	14	NA
Heinola <i>et al.</i> <sup>143</sup>	2016	Retrospective	55	32	9	40	7	3.6	4	5

NA = not available.

bleeding with haemodynamic instability, some authors have proposed the use of an intra-aortic balloon inserted via a femoral approach.<sup>141</sup>

#### 7.2.2.2. Graft materials.

**7.2.2.2.1. Reconstruction with autologous vein.** Autologous veins have the lowest infection rates (0% – 6%) and low graft thrombosis rates (Table 7). Disadvantages include harvesting difficulties in the emergency setting and a longer operation time so that it may not be tolerated by elderly patients with comorbidities. Previous deep vein thrombosis is a contraindication.<sup>142,143</sup> Harvesting veins is associated with venous morbidity with chronic venous insufficiency reported in up to 15%. Deep vein thrombosis occurred in up to 22%.<sup>142,143</sup> Venous grafts might be effective for highly virulent pathogens, but their use in multiresistant strains remains unclear.<sup>17,142</sup> There are reports of poor outcomes in the presence of Gram negative micro-organisms, MRSA, or *Candida* spp., especially when concomitant sepsis or AENF exists.<sup>144,145</sup>

**7.2.2.2.2. Cryopreserved allografts.** A number of studies have employed cryopreserved allografts for ISR of abdominal aortic VEGI.<sup>146–153</sup> Cryopreserved allografts have shown low re-infection rates (0% – 7%). Their limited availability, and rate of graft related complications resulting from allograft degradation (up to 21%), including aneurysm, dilatation, and graft rupture, are the main drawbacks.<sup>146–153</sup> Allograft related re-intervention rates were found in up to 55% of patients after five years (Table 8).<sup>147</sup> However, a better outcome with no dilatation or aneurysm during a mean follow up of five years was observed in another series of 71 patients.<sup>154</sup> Survival rates varied between 40% and 54% after five years.<sup>147,154</sup>

Graft specific factors such as allograft age, pre-treatment, and cryopreservation were of no prognostic value in multivariable analysis for ISR with cryopreserved allografts.<sup>150</sup> There is no evidence that post-operative

immunosuppressive therapy would prevent rejection in patients with cryopreserved allografts.

**7.2.2.2.3. Rifampicin bonded grafts.** Rifampicin bonded grafts can be used in less virulent and low grade infections, especially if these infections are caused by *S. aureus* or coagulase negative staphylococci. The re-infection rate is 11.5% (range 0% – 18%), but the amputation rate is low (Table 9).<sup>17,144,155–158</sup> Experimentally, there is weak activity against non-fermenter Gram negative bacilli, such as *Pseudomonas* species.<sup>159,160</sup> In retrospective studies, they are less effective in infections caused by MRSA, Gram negative strains, and fungi.<sup>156,157</sup> The antimicrobial efficiency of rifampicin bonded grafts is concentration and time dependent. Owing to dilution, the protective effect is reduced after approximately one week.<sup>157,159</sup> The rifampicin bonded concentration currently used in the treatment solution is heterogeneous, making the prediction of outcomes impossible. Concentrations of 1 – 60 mg/mL, with a maximum dose of 600 mg (soaked for 15 – 30 min) have been used in clinical and *in vitro* studies.<sup>140,144,155,157,159</sup> Development of rifampicin resistance might occur.<sup>157</sup> Their major advantage is their off the shelf availability in the emergency setting.

**7.2.2.2.4. Silver coated grafts.** Silver coated grafts are available in two different options, silver acetate, which dissolves within two to four weeks, and elemental silver, which remains for about one year.<sup>161,162</sup> The advantage of silver is its wide antimicrobial activity and paucity of resistance development in experimental studies. But in clinical trials for ISR, the re-infection rate of silver grafts is 11% (range 0% – 16%) within 2.5 years. Low amputation rates and high patency rates are reported (Table 10).<sup>17,163</sup> There is no comparison between different silver coatings. Only one study ( $n = 10$  patients) has reported the effect of elemental silver graft for ISR in the aorto-iliac position, and describing one re-infection.<sup>164</sup>

**Table 8.** *In situ* reconstruction with cryopreserved allografts for abdominal aortic vascular graft infection: an overview

Author	Publication date	Study type	n	Follow up – mo	Early mortality – %	Late mortality – %	Graft related complications					
							Total – %	Re-infection – %	Aneurysm dilatation – %	Rupture – %	Thrombotic occlusion – %	Amputation – %
Nevelsteen <i>et al.</i> <sup>271</sup>	1998	Retrospective	30	25	27	10	NA	7	13	3	23	6.7
Lesèche <i>et al.</i> <sup>185</sup>	2001	Retrospective	28	35.4	17.8	17.8	17	0	11	0	9	0
Verhelst <i>et al.</i> <sup>227</sup>	2000	Retrospective	90	36	17	16	21.1	1	7.8	8.8	10	1
Vogt <i>et al.</i> <sup>272</sup>	2002	Retrospective	49	27	6	20	16.3	0	0	8.1	2	0
Noel <i>et al.</i> <sup>273</sup>	2002	Registry database	56	5.3	13	25	25	0	2	9	9	5
Kieffer <i>et al.</i> <sup>102</sup>	2003	Retrospective	68	34	30	28	20.3	7	NA	0	29.7	0
Bisdas <i>et al.</i> <sup>151</sup>	2010	Retrospective	57	36	9	36	5.3	0	1.8	1.8	1.8	NA
McCready <i>et al.</i> <sup>228</sup>	2011	Retrospective	26	46.6	31	62	19	0	0	0	0	NA
Garot <i>et al.</i> <sup>152</sup>	2014	Retrospective	18	12	48	48	NA	0	NA	NA	23	NA
Touma <i>et al.</i> <sup>150</sup>	2014	Retrospective	54	12	28	39	19	3.7	1.9	11.1	11.1	1.9
Harlander-Locke <i>et al.</i> <sup>148</sup>	2014	Retrospective	220	30	9	49	24	3.6	2.7	5.5	4.1	NA
Minga Lowampa <i>et al.</i> <sup>229</sup>	2016	Retrospective	96	49	8	85	29	0	9.4	7	11.7	NA
Heo <i>et al.</i> <sup>149</sup>	2017	Retrospective	25	19	8	28	12	0	4	4	4	NA
Batt <i>et al.</i> <sup>198</sup>	2011	Retrospective	21	41	45.5	72.7	NA	14.2	NA	NA	18.2	0
Lejay <i>et al.</i> <sup>147</sup>	2018	Retrospective	25	47	24	40	55	NA	20	24	NA	NA
Ben Ahmed <i>et al.</i> <sup>154</sup>	2018	Retrospective	71	45	2.8	2.8	18.3	4	0	2	7	1.4

NA = not available.

**Table 9.** *In situ* reconstruction with rifampicin bonded grafts for abdominal aortic vascular graft infection: an overview

Author	Publication date	Study type	n	Rifampicin dose – mg/ml	Follow up – mo	Early mortality – %	Late mortality – %	Amputation rate – %	Graft occlusion – %	Re-infection – %
Torsello <i>et al.</i> <sup>158</sup>	1997	Retrospective	11	60	33	18	18	0	NA	9
Hayes <i>et al.</i> <sup>156</sup>	1999	Retrospective	11	45–60	12	18.2	36.4	0	18.2	0
Young <i>et al.</i> <sup>155</sup>	1999	Retrospective	25	1	36	8	24	0	14	4
Bandyk <i>et al.</i> <sup>157</sup>	2001	Retrospective	19	45–60	17	9.1	NA	0	0	8
Oderich <i>et al.</i> <sup>144</sup>	2006	Retrospective	52	2.4	41	8	16	0	8.8	11.5
Batt <i>et al.</i> <sup>198</sup>	2011	Retrospective	8	NA	41	31.8	40	NA	0	0
Schaeffers <i>et al.</i> <sup>274</sup>	2018	Retrospective	10	NA	27	0	0	NA	NA	0

NA = not available.

**Table 10.** *In situ* reconstruction with silver coated grafts for abdominal aortic vascular graft infection: an overview

Author	Publication date	Study type	Graft type	n	Follow up – mo	Early mortality – %	Late mortality – %	Amputation rate – %	Graft occlusion – %	Reinfection – %
Batt <i>et al.</i> <sup>275</sup>	2003	Prospective	Silver acetate	24	17	16.6	16.6	0	0	0
Mirzaie <i>et al.</i> <sup>163</sup>	2007	Prospective	Silver acetate	11	30	0	0	0	0	0
Batt <i>et al.</i> <sup>276</sup>	2008	Prospective	Silver acetate	24	32.5	20.8	25	4	8.3	12.5
Pupka <i>et al.</i> <sup>277</sup>	2011	Prospective	Silver acetate	27	22.8	11	NA	0	0	16
Bisdas <i>et al.</i> <sup>151</sup>	2010	Retrospective	Silver acetate	11	24	18	27	0	0	9
Zegelman <i>et al.</i> <sup>164</sup>	2013	Retrospective	Metallic silver	10	18	NA	NA	NA	NA	10

NA = not available.

**7.2.2.2.5. Xenogenous grafts.** Bovine pericardium is an off the shelf solution and can be tailored to form a tube or bifurcated graft. There are a few case series involving thoracic, thoraco-abdominal, and abdominal reconstructions. Re-infection rates were described in up to 16% in small series; other studies reported 100% freedom from re-infection or re-intervention in follow ups of up to four years involving thoracic, thoraco-abdominal, and abdominal reconstructions.<sup>113–115,165–168</sup> The largest series included 35 patients and four years of follow up, and reported only seven patients who got bovine pericardium for abdominal aortic VGIs. Four of the seven died within 30 days owing to ongoing sepsis and multi-organ failure. Three were free of re-infection, without signs of degeneration. Further studies with longer follow ups are mandatory. Their role in case of sepsis remains unclear.

There is little experience with the use of ovine, mesh reinforced biosynthetic prosthesis in ISR for abdominal aortic VGIs ( $n = 13$ , follow up 11 – 26 months), with a trend to low infection rates, but only case series have been reported.<sup>169,170</sup> Consequently, no recommendation can be made.

**7.2.2.3. Adjunctive therapies.** During ISR, the proximal anastomosis can be re-inforced with fascia.<sup>143,171</sup> After inserting the new VG, it should be covered by biological material, especially pedicled omentum flap, muscle, fascia, or retroperitoneal tissue.<sup>171</sup> An omental wrap around the graft lowers the rate of infection, even when rifampicin or silver coated VGs are used.<sup>144,155</sup> There are insufficient data on the efficacy of bio-absorbable and non-absorbable local antibiotic beads or sponges, and reported data have described their use in an extracavity position only.<sup>172,173</sup> If the groin is involved, the distal anastomosis can be covered by a muscle flap.<sup>142,143</sup>

The use of NPWT in abdominal aortic VGI has only been described in five patients with aorto-iliac VGI treated via a retroperitoneal approach with radical debridement and placement of the foam directly on the graft. There was no 30 day mortality and no one year re-infection. The technique requires repeated dressing changes every three to five days, but long term data are not available.<sup>174</sup>

**7.2.3. Extra-anatomic reconstruction.** Axillobifemoral or axillobipopliteal bypasses through a non-infected field were performed to restore lower limb perfusion following excision of an infected graft. The disadvantages of axillobifemoral reconstructions are low patency rates (64% – 75% at five years) and high amputation rates (up to 11% at five years). Stump rupture with life threatening haemorrhage can occur in up to 27% of reported cases (Table 11).<sup>137</sup> Finally, re-infection rates after extra-anatomic bypasses were 0% – 15%<sup>144,175,176</sup> and up to 27% in small series.<sup>137,177</sup> A 30 day mortality rate of 18% (range 11% – 45%) and a late mortality of 32% (range 22% – 44% within 47 months) have been described (Table 11).<sup>137,138,175,177,178</sup> Compromised colonic and pelvic blood supply due to insufficient internal iliac and inferior mesenteric artery perfusion might also lead to complications.

Axillofemoral and axillopopliteal bypass patency rates were lower in patients with concomitant occlusive disease (primary patency of 71% vs. 73%, secondary patency rates of 79% vs. 92% after five years).<sup>175,179</sup> The outcome for axillopopliteal bypasses in abdominal aortic VGEI is poor, with a reported primary patency of 0% at 7 months, and a secondary patency 53% at 17 months and 27% at 50 months in a series of five axillopopliteal bypasses performed for abdominal aortic VGEI.<sup>175</sup>

**7.2.3.1. Two stage procedure.** EARs can be performed directly after bypass removal for reconstruction of the lower extremities or as staged procedure. A two stage procedure one to five days before removal of the infected graft should be considered in haemodynamically stable patients because of the reduction of operative metabolic (acidosis) and haemodynamic stress.<sup>175,179,180</sup> Reductions in the mortality and amputation rates were found when staged procedures were performed.<sup>181</sup> Competitive flow has never been reported to be the causative factor of graft occlusions, but no specific studies have been performed.

**7.2.3.2. Stump management.** Risk of stump rupture is related to the mechanical consequences of too short a stump and to the properties of the persistent infected

**Table 11. Extra-anatomic reconstructions for abdominal aortic vascular graft infection: literature overview**

Author	Publication date	Study type	n	Follow up – mo	Early mortality – %	Late mortality – %	Amputation rate – %	Graft occlusion – %	Re-infection – %	Stump rupture – %
Seeger <i>et al.</i> <sup>175</sup>	2000	Prospective	36	32	11	44	11	31	3	3
Ohta <i>et al.</i> <sup>138</sup>	2001	Retrospective	9	47	11	22	NA	33	0	0
Bandyk <i>et al.</i> <sup>157</sup>	2001	Retrospective	19	17	9.1	NA	11	34.4	2.8	NA
Hart <i>et al.</i> <sup>184</sup>	2005	Retrospective	15	15	40	45	6	NA	13	7
Armstrong <i>et al.</i> <sup>216</sup>	2005	Retrospective	25	51	21	NA	6.9	NA	13.8	4
Oderich <i>et al.</i> <sup>144</sup>	2006	Retrospective	43	41	11.6	NA	9	37.2	11.6	9
Brown <i>et al.</i> <sup>176</sup>	2009	Retrospective	18	14	22	44	6	11	0	0
Batt <i>et al.</i> <sup>198</sup>	2011	Retrospective	11	41	45	NA	27	27	27	27
Charlton-ouw <i>et al.</i> <sup>177</sup>	2015	Retrospective	5	72	20	40	0	NA	20	20
Yamanaka <i>et al.</i> <sup>183</sup>	2014	Retrospective	7	27	NA	NA	6.9	NA	13.8	NA

NA = not available.

tissue after incomplete debridement. If the stump is too short, transposition or renal and visceral artery bypass is likely to be necessary and should be performed first to minimise the visceral ischaemic time. Techniques to prevent stump rupture include double suture layers, reinforcement with venous or felt pledgets, prevertebral fascia, or a layer of posterior rectus fascia peritoneum. Most authors recommend covering the stump with omentum or an omental wrap.<sup>144,178,182</sup> Another technique is a pedicled latissimus dorsi flap.<sup>183</sup>

**7.2.4. Systematic reviews and meta-analyses on *in situ* reconstruction, extra-anatomic reconstruction, and graft materials.** Two meta-analyses (37 studies, 1 417 patients;<sup>180</sup> 36 studies, 1 464 patients<sup>17</sup>) showed significantly better outcomes for ISR than EAR with overall lower complication, re-infection, and mortality rates.

There was no significant difference in the re-infection rate between the different grafts (veins 2%; cryopreserved allografts 9%, rifampicin bonded or silver coated prosthesis 11%), but they all demonstrated significantly better results than standard ePTFE and PET grafts for ISR. Veins and silver coated prostheses had significantly lower graft occlusion rates (2% and 7%, respectively) than cryopreserved allografts (13%) or rifampicin bonded prostheses (11%). The amputation rate was significantly lower in cryopreserved allografts (3%), and rifampicin (3%) or silver coated grafts (4%) than veins (9%). Standard ePTFE and PET grafts gave significantly worse results for graft occlusion and amputation. Meta-regression analysis preferred veins for ISR neo-aorto-iliac reconstruction, especially in younger patients, except in the presence of AEnF, while autologous veins provided the best outcomes with virulent infecting organisms.

For abdominal aortic VG/EG without AEnF, the data suggest that ISR with autologous veins, cryopreserved allografts, silver coated grafts, or rifampicin bonded grafts should be considered. Long term follow up is missing for bovine pericardium. Even though there is no ideal graft material, most authors prefer a biological material conduit for ISR. Veins might be preferable in young patients with a longer life expectancy. Rifampicin soaked grafts or silver grafts have been shown effective, especially in low virulence infections. For large perigraft abscesses and MRSA infections, EAR and removal of the infected graft may be considered.<sup>17,146,151,176,177,180</sup>

**7.2.5. Partial or total excision of the material.** Total excision of the infected graft is mandatory to control VGI.<sup>148</sup> There are some inconclusive reports of partial graft resection in high risk patients, when complete graft excision was not possible.<sup>184</sup> In retrospective studies, successful treatments were reported, when infection was limited to the groin and supra-inguinal VGs were incorporated. Retrospective studies reported no re-infection after 2.5 years in 11 patients after interposition of unilateral silver coated grafts,<sup>163</sup> no re-infection after partial interposition with

cryopreserved allografts in 10 patients after three years,<sup>185</sup> and a 9.5% re-infection rate after partial resection with autologous vein interposition in 20 patients after 72 months.<sup>186</sup> Limited resection of only infected material and reconstruction by obturator canal bypass ( $n = 18$ ) or part of a bifurcated graft ( $n = 34$ ) was also proposed with re-infection rates of 6% and 0%, respectively, and no amputation at 36 months.<sup>187</sup> Other series reported a 47% ( $n = 7/15$  patients) infection rate of the contralateral limb after 39 months, when partial resection of an aortobifemoral VGI and EAR was performed.<sup>188</sup> Overall mortality was 40% and similar between patients with or without recurrent graft infections.

As an individual decision, partial resection, and ISR or an extra-anatomic route might be an option. Successful treatment was based on low virulence organisms, especially monomicrobial determination of multidrug sensitive streptococci species and *S. aureus*. If polymicrobial, fungal or Gram negative organisms were present, total excision of the infected graft was recommended.<sup>163,186–188</sup>

**7.2.6. Endograft infection.** Eradication of infection by removal of the infected EG and ISR with biological material has the lowest re-infection rate (< 10%) and is recommended for patients who are fit for surgery.<sup>132</sup> Reported 30 day mortality rates have been 8% – 39% and amputation rates 0% – 2%.<sup>189–191</sup> In the case of EAR, stump management may be more difficult because clearly the neck can be damaged by the extraction owing to the presence of suprarenal hooks promoting ligation very proximal to the renal artery ostia. If the patient is unfit for surgery, conservative treatment with lifelong antibiotics or drainage of infection without removal of the EG must be considered. The mortality of patients managed by conservative treatment with antimicrobial therapy alone is high, reported as 63.3% at 30 days.<sup>132</sup>

### 7.3. Graft enteric fistula

Fistulisation can occur early after bowel injury during the surgical dissection or poor tunnelling, or as a consequence of a suture line pseudo-aneurysm or as a consequence of prior graft infection.<sup>192</sup>

**7.3.1. Specific treatment modalities.** Depending on the location of the AEnF, securing the aortic clamping zone can be obtained more proximally using a supraceliac approach.<sup>140,192</sup> Whenever possible, it is advised to avoid entering the enteric communication during the dissection and to leave a “patch” of the old graft attached to the intestine to avoid enteric content spillage.<sup>140</sup>

**7.3.2. Stent grafts as a temporary or a definitive solution.** In the last decade, several studies have reported the use of stent grafts to treat AEnF. In a retrospective comparative, multicentre study no post-operative mortality in patients treated with EG vs. VG, a mortality of 35% in patients treated with VG was reported.<sup>193</sup> Late sepsis occurs

significantly more often after endovascular surgery than after open surgery (42% vs. 19% at two years). In particular, the presence of pre-operative sepsis was found to be a factor indicative of an unfavourable outcome.<sup>193</sup> As a consequence, some authors have proposed the temporary use of EG as a “bridge technique” followed by EG extraction and *in situ* repair, or even as a definitive treatment in select cases of bleeding without clear sepsis.<sup>194–198</sup>

**7.3.3. *In situ* reconstruction or extra-anatomic reconstruction.** A systematic review based on 1 467 patients concluded that axillobifemoral bypass and abdominal aortic VG removal in a staged procedure was the best therapeutic option, with a mortality of 31% vs. 51% in a non-staged procedure and 47% in the case of ISR.<sup>199</sup> No difference in re-infection rate between EAR and ISR was found.<sup>198</sup> In both cases, PET VGs were used. These findings contrast with other findings that report ISR as an independent factor for survival in a multivariable analysis.<sup>200</sup>

**7.3.4. Total or partial graft excision.** In a series of 54 patients treated for a secondary AEnF, partial graft excision led to a 4% re-infection rate with a mean follow up of 51 months.<sup>140</sup> In several studies, no difference in outcome was seen between patients with partial resection and complete resection.<sup>146,198</sup> The only factor influencing the re-infection rate (47%) was the length of follow up, led to the conclusion that lifetime follow up was mandatory.<sup>198</sup> Mortality after re-infection was 100%.

### 7.3.5. Bowel repair

#### 7.3.5.1. Direct suture vs. complex bowel reconstruction.

The type of the bowel repair depends on the size and the location of the defect.<sup>140,192,201</sup> A tension free duodenorrhaphy with direct suture of the duodenum can be performed if the bowel defect is small, avoiding an extensive approach, but a complex duodenal reconstruction with resection anastomosis and re-routing decreases the risk of recurrent infection.<sup>200</sup>

**7.3.5.2. Omental interposition.** Pedicle omental flap can be transferred in order to cover the reconstruction and separate the new vascular reconstruction from the bowel. It is recommended when feasible as it has been shown to be the strongest predictive factor for survival.<sup>140,192,200,201</sup>

### 7.4. Visceral artery revascularisation infection

Although the nature of the bypass suggests that visceral bypasses are frequently involved with VGEI, a systematic literature search yielded only two case reports that specifically deal with the treatment of an infected mesenteric bypass.<sup>202,203</sup>

Owing to the optimisation of endovascular possibilities, the treatment of mesenteric occlusive disease has evolved towards an endovascular first approach whereas in the recent past this was not the case. In some cases of infected mesenteric bypasses, an initial endovascular recanalisation of the native vessel followed by removal of the infected graft material and closure of the anastomotic site with an autologous vein patch might be possible.<sup>202</sup>

### 7.5. Ureteral fistula

Arterio-ureteral fistulae (AUFs) occur in < 1% of patients after aorto-iliac surgery and are almost entirely related to VGIs. A pseudo- or true common or external iliac artery aneurysm with fever, pain, or swelling due to abscess can be found in 38% of cases.<sup>204</sup> Recurrent urinary tract infections were concomitant findings in 40% and urinary outflow obstruction with hydronephrosis in 70%.<sup>205–207</sup>

For acute haemorrhage, stent graft insertion as a bridge might be proposed.<sup>206</sup> For definitive healing, open surgery with VG or EG explantation and AUF resection is mandatory. VG or EG removal and EAR with femorofemoral crossover bypass and ligation of the iliac artery should be considered.<sup>205–208</sup> In ISR with cryopreserved allografts, silver coated or rifampicin bonded VG were reported, but there are no available data concerning morbidity or mortality rates. Primary ureteric repair, ligation (with or without nephrectomy), re-implantation to a site away from the vessels, or diversion of the urine with a nephrostomy tube may be necessary. Nephrectomy has to be considered if irreversible damage to the renal collecting system has occurred.<sup>205–208</sup> An indwelling ureteral stent should be removed owing to the risk of recurrent fistulisation or re-infection.<sup>207</sup>

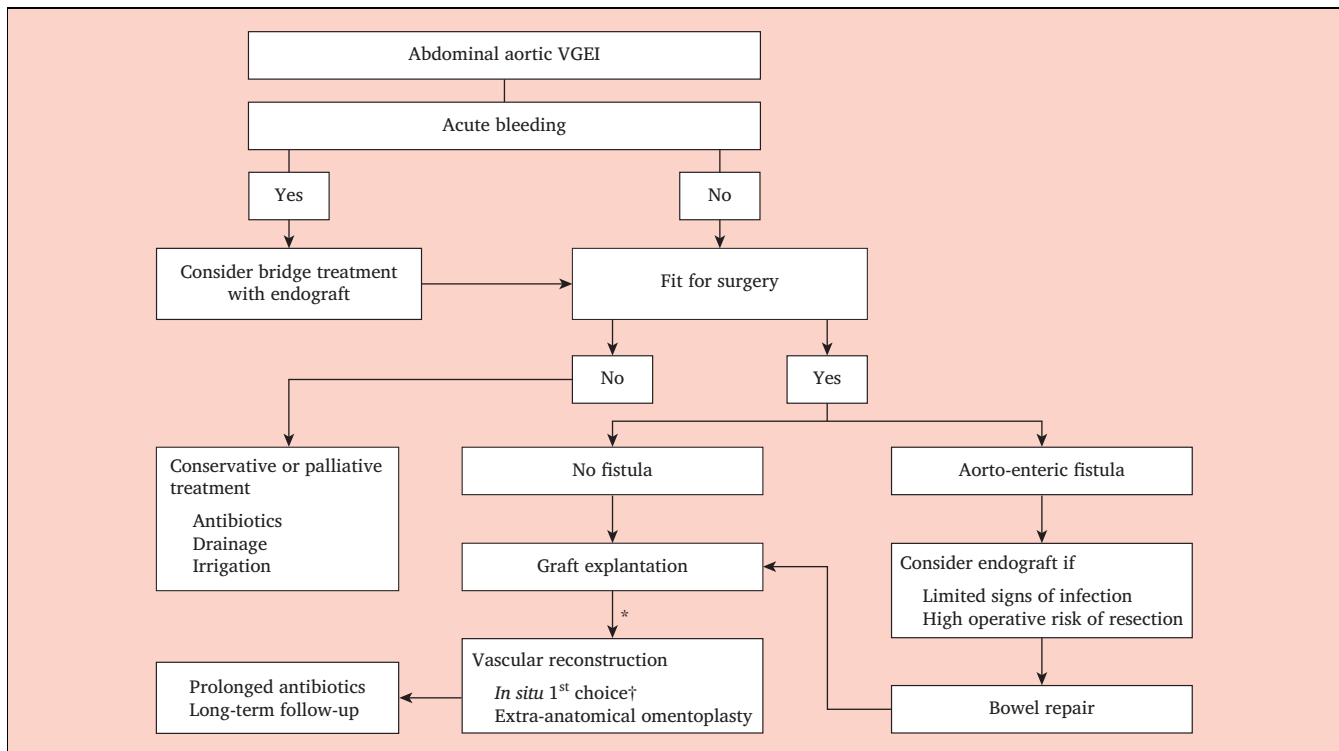
### 7.6. Follow up and prognosis

Abdominal aortic VGEI are some of the most challenging and highly morbid conditions to treat, with an early mortality rate ranging from 16% to 22%, an amputation rate ranging from 3% to 18%, and a re-infection rate of 6% – 20%.<sup>17,137</sup> However, late mortality is not assessable owing to insufficient data, a wide range of follow up, and the use of different types of conduit. Because it is a rare condition, studies include all kind of abdomino-iliac or aortofemoral graft reconstruction. Therefore, there is very limited evidence, with no comparative studies at all and with most published series burdened by selection bias, indicating that individual surgical decisions for treatment are needed (Fig. 6).

Management and treatment choice must be performed within a multidisciplinary team, including vascular surgeons, visceral surgeons, infection disease specialists, radiologists, and anaesthetists.

Mortality rates relate to: (i) the patient’s condition — an American Society of Anaesthesiology score 4 and sepsis are independent risk factors for mortality,<sup>145,154</sup> as well as individual local presentation of infection affect the outcome; (ii) the emergency or elective setting — there is higher 30 day mortality in emergency settings,<sup>146</sup> (iii) the presence of an AEnF — studies that included AEnF resulted in worse outcome;<sup>198</sup> (iv) virulence of the micro-organisms — operative mortality rate was higher in abdominal aortic VGEI caused by virulent micro-organisms.<sup>17,144,145,156,157,180</sup> MRSA and multi-resistant strains are associated with poor outcome.<sup>17,137,144,156,157,180</sup>

Post-operative duration of antibiotics and the variety of bacterial specimens are quite different. The number of studies and wide range of included patients ( $n = 5–220$ ) might not adequately represent diverse patterns of clinical manifestation, specific patient subgroups or the experience



**Figure 6.** Proposed algorithm for the management of aortic vascular graft/endograft infection. \* In a single or staged procedure. † Materials that can be used are deep femoral veins, cryopreserved allografts, silver grafts or rifampicin impregnated grafts. VG/EI = vascular graft/endograft infection.

of each centre because of the low numbers of patients treated annually.

Post-operative follow up is important. Close surveillance, including laboratory test and US is mandatory every three to six months for a minimum of one year, and later lifelong every 6 – 12 months is reasonable. If clinical signs, laboratory tests or US are suspicious, CT is recommended. Special attention should be paid if ISR with allografts was performed.

Recommendation 37		
Percutaneous drainage of peri-graft fluid with or without irrigation may be considered for microbiological identification and to reduce the bacteriological burden, but not as ultimate treatment in abdominal aortic graft/endograft infection.		
Class	Level	References
I Ib	C	Calligaro <i>et al.</i> (2003), <sup>135</sup> Batt <i>et al.</i> (2012), <sup>137</sup> Ohta <i>et al.</i> (2001), <sup>138</sup> Igari <i>et al.</i> (2014) <sup>139</sup>

Recommendation 38		
For fit patients with an abdominal aortic vascular graft/endograft infection, complete excision of all graft material and infected tissue is recommended for definitive treatment.		
Class	Level	References
I	B	Batt <i>et al.</i> (2018), <sup>17</sup> O'Connor <i>et al.</i> (2006) <sup>180</sup>

Recommendation 39		
For patients with an abdominal aortic vascular graft/endograft infection, <i>in situ</i> reconstruction with autologous vein should be considered as the preferred method.		
Class	Level	References
I Ia	C	Batt <i>et al.</i> (2018), <sup>17</sup> Spiliotopoulos <i>et al.</i> (2018), <sup>66</sup> Dorigo <i>et al.</i> (2003), <sup>69</sup> Dorweiler <i>et al.</i> (2014), <sup>142</sup> Heinola <i>et al.</i> (2016), <sup>143</sup> Ali <i>et al.</i> (2009), <sup>145</sup> Harlander-Locke <i>et al.</i> (2014), <sup>148</sup> O'Connor <i>et al.</i> (2006), <sup>180</sup> Rodrigues dos Santos <i>et al.</i> (2014) <sup>200</sup>

Recommendation 40		
For patients with abdominal aortic vascular graft/endograft infection, cryopreserved allografts, silver coated grafts, rifampicin bonded polyester grafts, or bovine pericardium should be considered as alternative solutions.		
Class	Level	References
I Ia	C	Batt <i>et al.</i> (2018), <sup>17</sup> Spiliotopoulos <i>et al.</i> (2018), <sup>66</sup> Dorigo <i>et al.</i> (2003), <sup>69</sup> Dorweiler <i>et al.</i> (2014), <sup>142</sup> Heinola <i>et al.</i> (2016), <sup>143</sup> Ali <i>et al.</i> (2009), <sup>145</sup> Harlander-Locke <i>et al.</i> (2014), <sup>148</sup> O'Connor <i>et al.</i> (2006), <sup>180</sup> Rodrigues dos Santos <i>et al.</i> (2014) <sup>200</sup>

Recommendation 41		
Partial excision of infected an aortic vascular graft/endograft may be considered when infection is documented as limited and the remaining material is well incorporated.		
Class	Level	References
I <b>lb</b>	C	Mirzaie <i>et al.</i> (2007), <sup>163</sup> Simmons <i>et al.</i> (2017), <sup>186</sup> Phang <i>et al.</i> (2019) <sup>187</sup>

Recommendation 42		
For patients with abdominal aortic vascular graft/endograft infection and a large abscess or multiresistant microorganisms, extra-anatomic reconstruction may be considered.		
Class	Level	References
I <b>b</b>	B	Oderich <i>et al.</i> (2006) <sup>144</sup>

Recommendation 43		
Lifelong imaging follow up is recommended after <i>in situ</i> reconstruction with cryopreserved allografts for abdominal aortic vascular graft/endograft infection, in order to detect allograft degeneration.		
Class	Level	References
I	C	Lejay <i>et al.</i> (2017), <sup>147</sup> Harlander-Locke <i>et al.</i> (2014), <sup>148</sup> Touma <i>et al.</i> (2014), <sup>150</sup> Kieffer <i>et al.</i> (2004), <sup>153</sup>

Recommendation 44		
Securing a supraceliac clamp zone or using an aortic occlusion balloon may be considered as the first step before entering the aorto-enteric fistula area.		
Class	Level	References
I <b>b</b>	C	Miyamoto <i>et al.</i> (2016), <sup>141</sup> Schoell <i>et al.</i> (2015) <sup>192</sup>

Recommendation 45		
In the emergency setting of active bleeding complicating abdominal aortic graft/endograft infection with or without aorto-enteric fistula, initial treatment with an endograft should be considered, but only as a temporary measure.		
Class	Level	References
I <b>la</b>	C	Chick <i>et al.</i> (2017), <sup>197</sup> Batt <i>et al.</i> (2011) <sup>198</sup>

Recommendation 46		
In surgical repair of aortic abdominal graft/endograft infection with aorto-enteric fistula, omentoplasty or transfer of autologous vascularised tissue to cover the vascular reconstruction is recommended.		
Class	Level	References
I	B	Rodrigues dos Santos <i>et al.</i> (2014) <sup>200</sup>

Recommendation 47		
In the emergency setting of active bleeding complicating abdominal aortic graft/endograft infection with an arterio-ureteral fistula, initial treatment with an endograft may be considered, but only as a temporary measure.		
Class	Level	References
I <b>b</b>	C	van den Bergh <i>et al.</i> (2009), <sup>204</sup> Das <i>et al.</i> (2016), <sup>205</sup> Malgor <i>et al.</i> (2012), <sup>206</sup> Madoff <i>et al.</i> (2004), <sup>207</sup> Pillai <i>et al.</i> (2015) <sup>208</sup>

Recommendation 48		
For patients with an arterio-ureteral fistula and vascular graft/endograft infection, complete explantation of the graft combined with urological treatment with or without <i>in situ</i> arterial reconstruction should be considered.		
Class	Level	References
I <b>la</b>	C	van den Bergh <i>et al.</i> (2009), <sup>204</sup> Das <i>et al.</i> (2016), <sup>205</sup> Malgor <i>et al.</i> (2012), <sup>206</sup> Madoff <i>et al.</i> (2004), <sup>207</sup> Pillai <i>et al.</i> (2015) <sup>208</sup>

## 8. PERIPHERAL ARTERIES

### 8.1. Specific aspects

**8.1.1. Incidence and risk factors.** VGI has been reported in up to 2.5% in femorofemoral prosthetic bypasses,<sup>209</sup> and in up to 2.8% in femoropopliteal prosthetic bypasses.<sup>210</sup> Higher incidences have been reported in series where 90% of the indication had been critical limb threatening ischaemia. In a retrospective review of 141 grafts involving the femoral artery, VGI occurred in 25 (18%) and occurred most frequently after major amputation (41% vs. 6%) or early re-intervention after initial grafting (70% vs. 16%). Risk of VGI after amputation was highest when amputation was performed less than four weeks after the bypass (70% vs. 32% when amputation was done more than four weeks after the bypass).<sup>211</sup>

The differentiation of deep wound infection and VGI is unclear in many reports. SSI is the strongest risk factor for VGI. Risk factors for SSI must be known, but it should always keep in mind that these are not strictly correlated with VGI (Table 12).

Peripheral arteries are a major site for stent implantation. One systematic review identified 48 bare metal stent infections outside the coronary arteries.<sup>212</sup> Emergency prior procedures with adjunctive thrombolysis represented almost 20% of the infected non-cardiac cases and were considered as risk factors for infection.

**8.1.2. Clinical presentation.** The most common site of VGEI after aorto-iliac or infra-inguinal reconstructions is the groin. Clinical presentation can include fever, pain, mass, or redness of the skin. This can be explained not only by the specific risk of contamination of the groin or by the

poor healing of the wound, but also because this approach is frequently performed in patients with infected distal wounds. Wound complications following vascular procedures involving the groin have been reported in up to 20% of patients.<sup>213</sup>

## 8.2. Treatment options

**8.2.1. Conservative treatment.** Conservative treatment of lower limb VGI without removal of the infected VG is rarely an option because it is associated with a high mortality (up to 45% at five years),<sup>214</sup> persistent infection, anastomotic disruption, or active bleeding. However, if the infected VG is not removed, the risk of persistent infection, anastomotic disruption, or active bleeding must be anticipated.

**8.2.1.1. Negative pressure wound therapy.** NPWT is an option to manage VGI in order to promote wound healing after debridement of the infected tissue.<sup>215</sup> Even though  $-125$  mmHg has been shown to allow faster granulation and faster healing, lower pressure is recommended if the NPWT is in contact with the graft in order to avoid the bleeding when higher pressure is employed.<sup>215</sup> NPWT may lead to serious bleeding complications in up to 10% of patients and eradication of infection is uncertain.<sup>216–220</sup>

In a retrospective series of 68 patients with 72 deep inguinal infections below the inguinal ligament and with a blood culture negative for septicaemia, septic anastomotic involvement, or bleeding, 85% ( $n = 61/72$ ) of the grafts were in place nine months after initiation of treatment.<sup>215</sup> Another retrospective study of 161 patients treated by NPWT showed that major bleeding occurred in 7.1% and re-infection after complete wound healing in 6.4%. The cumulative estimated proportion of completely healed wounds was 70% after 80 days. Independent risk factors for failure of wound treatment were synthetic graft infection (OR 6.1, 95% CI 2.6 – 14.2) and bleeding or pseudoaneurysm as presenting symptom (OR 2.9, 95% CI 1.0 – 8.2).<sup>218</sup>

The EndoVAC technique can be an option for bleeding or high risk of bleeding.<sup>84,85</sup> The principle in this hybrid technique is to use endograft to control or prevent bleeding and NWPT for secondary wound healing, but so far the number of patients treated is too low to give any recommendations on the use of this technique.

**8.2.1.2. Irrigation.** The aim of irrigation is to reduce bacterial colonisation of the infected VG. Irrigation is mostly established in the groin, through drainage provided by a tube placed in the infected cavity after wound debridement. Irrigation may be considered only in patients in whom removal of the infected prosthetic material is not possible.<sup>213</sup>

## 8.2.2. In situ reconstruction

**8.2.2.1. Specific technical aspects.** If the original indication was claudication, immediate revascularisation may not be necessary. In these cases, arteriotomies performed for VG removal must be closed with biological substitutes, such as saphenous vein or bovine pericardial patch. A secondary bypass may be performed later after total eradication of the infection. Conversely if the original indication was chronic limb threatening ischaemia (Rutherford 4 – 6) and if the leg presents with severe ischaemia after VG removal, immediate redo bypass is mandatory to avoid major amputation. Revascularisation is also needed when the arterial disease has progressed significantly or infected graft removal is not possible without sacrificing other crucial vessels.

### 8.2.2.2. Graft materials.

**8.2.2.2.1. Reconstruction with autologous material.** The great saphenous vein (GSV) and other superficial venous materials is preferred when available, as such material is easily harvested.<sup>221,222</sup>

Autologous femoral vein has also been reported to be useful in treating peripheral graft infections with a low rate of recurrent infection, if the diameter of the femoral vein fits the inflow and outflow arteries.<sup>223</sup>

ISR, preferably with autologous vein, has gained popularity as it is less invasive than extra-anatomotic

**Table 12.** Patient related independent risk factors for surgical site infections of the lower limbs

Risk factor	Adjusted risk estimation OR (95% CI)	Reference
Female sex	1.44 (1.28–1.63)	Greenblatt <i>et al.</i> (2011) <sup>278</sup>
Obesity	2.08 (1.78–2.43)	Greenblatt <i>et al.</i> (2011) <sup>278</sup>
Body mass index >25 kg/m <sup>2</sup>	1.78 (1.23–2.57)	Davis <i>et al.</i> (2017) <sup>279</sup>
Chronic obstructive pulmonary disease	4.29 (2.74–6.72)	Davis <i>et al.</i> (2017) <sup>279</sup>
Dialysis	2.10 (1.07–4.09)	Leekha <i>et al.</i> (2016) <sup>280</sup>
	1.51 (1.08–1.44)	Greenblatt <i>et al.</i> (2011) <sup>278</sup>
Critical limb ischaemia	4.35 (3.45–5.47)	Davis <i>et al.</i> (2017) <sup>279</sup>
Re-intervention	2.91 (1.61–5.27)	Leekha <i>et al.</i> (2016) <sup>280</sup>
Blood glucose >11 mmol/L	2.68 (1.38–5.22)	Leekha <i>et al.</i> (2016) <sup>280</sup>
Hyponatraemia <134 g/dL	11.0 (1.9–63)	Brothers <i>et al.</i> (2009) <sup>211</sup>
Post-operative immobilisation	1.20 (1.02–1.42)	Greenblatt <i>et al.</i> (2011) <sup>278</sup>
Major amputation	12 (4.1–34)	Brothers <i>et al.</i> (2009) <sup>211</sup>
Prior revascularisation	2.68 (1.38–5.22)	Leekha <i>et al.</i> (2016) <sup>280</sup>

OR = odds ratio; CI = confidence interval.



bypass.<sup>14,224,225</sup> If autologous vein is not available, there remains controversy over which is the optimal ISR graft following excision of the infected graft.

**8.2.2.2.2. Cryopreserved allografts.** The re-infection rate of ISR with cryopreserved allograft is lower than with prosthetic grafts, and the amputation rate is lower than with the removal of the infected graft without reconstruction.<sup>147,223,226–228</sup> However, graft degeneration may lead to serious complications in the long term. In a retrospective analysis of 53 patients treated for VGI with cryopreserved arterial allograft, the graft related re-intervention rate at five years was 33% in patients who underwent peripheral reconstruction (two allograft ruptures, seven aneurysmal degenerations). Allograft related complications, such as allograft thrombosis, anastomotic pseudo-aneurysm, degenerative aneurysm, and allograft disruption leading to bleeding have been reported in 29% of patients.<sup>229</sup> Cryopreserved GSV has the advantage of a better size match in the infrapopliteal segments and crural vessels and longer segments may be available than arteries; however, patency is limited (around 35% at one year).<sup>230</sup> Primary and secondary patency rates of 56% and 73% have been reported at one year, respectively, and 17% and 38%, respectively, at five years.<sup>231</sup>

**8.2.2.2.3. Prosthetic grafts.** The advantages of prostheses are that they are readily available and operating time is shorter, but the re-infection rate is high vs. non-prosthetic solutions. Silver impregnated or rifampicin soaked PET grafts have been used for ISR following removal of the infected graft, but the level of evidence is low and most of the studies have been on the treatment of aortic infection.<sup>232,233</sup> In a study of 24 femoropopliteal bypasses replaced with silver impregnated PET grafts, the overall re-infection rate was 19%.<sup>234</sup> When rifampicin soaked grafts are used, the results of wound cultures (when available) should be considered, as data have shown that the micro-organism causing the infection was resistant or not susceptible to rifampicin in 31% of cases.<sup>235</sup>

A biosynthetic collagen prosthesis (Omniflow II; LeMaitre, Burlington, MA, USA) has also been tested in the presence of graft infection. In a series of nine consecutive patients who underwent replacement of an infected peripheral graft with a biosynthetic prosthesis, the early morbidity rate was 56% ( $n = 5$ ), with no in hospital death. Four patients had post-operative wound healing problems treated conservatively and one patient had acute early graft occlusion leading to major amputation. Two patients had late graft occlusion six and 12 months after the procedure, respectively. FDG-PET was performed in six patients after a median follow up of 19 months, which excluded graft re-infection in all patients.<sup>236</sup>

**8.2.2.2.4. Xenogenous grafts.** Bovine pericardial patches can also be used to replace an infected patch or close the arterial defect. They are supposed to be more resistant to infection than prosthesis.<sup>237</sup> In a series of 51 bovine

pericardial patches used to close an arteriotomy where the original ePTFE patch had to be removed as a result of infection, one rupture was reported, but no other infection related complication occurred after a median follow up of 25 months.<sup>237</sup>

**8.2.2.3. Adjunctive therapy.** A growing body of research and experience suggests that muscle flap coverage in addition to graft removal with or without vascular reconstruction can be efficacious in managing these complex groin wounds and improve graft and limb salvage and survival. Several retrospective studies support the use of different types of muscle flaps in high risk vascular surgery patients, and report decreased groin wound morbidity.<sup>238–240</sup> However, more data are required to see clearly which type of muscle flap is ideal in which type of wound.

**8.2.2.3.1. Sartorius muscle flap (SMF).** SMF has been considered the standard surgical technique to treat infectious complications in the groin, in addition to a simultaneous vascular procedure.<sup>238</sup> There were concerns about sartorius muscle arterial blood supply in cases with superficial femoral artery occlusion, as sartorius arterial blood supply originates from multiple segmental branches of the superficial femoral and deep femoral artery. When the deep femoral artery is patent, the patency of superficial femoral artery does not affect the viability of the SMF.<sup>241,242</sup> However, SMF viability is compromised when the deep femoral artery is occluded. In such cases, revascularisation of the deep femoral artery is needed, either directly or indirectly (obturator bypass). In a series of 170 SMFs, of which 36 (21%) were done for infection, surgical re-intervention within 30 days was required in seven of 170 patients (4.1%) and any 30 day complications occurred in 47 patients (28%).<sup>243</sup> Another study compared efficacy analysis of the SMF vs. the rectus femoris flap (RFF) in the treatment of wounds following an infra-inguinal vascular procedure in 184 patients and a total of 201 flaps. There were no sentinel bleeding events through the course of graft salvage or peri-operative morbidity beyond local wound complications.<sup>244</sup>

**8.2.2.3.2. Rectus femoris flap (RFF).** A RFF is easy to harvest, has a good blood supply from the lateral circumflex femoral artery, has an excellent arc of rotation, and provides a large bulk to fill larger defects after aggressive debridement for infected and necrotic tissue. With a smaller donor site incision, the morbidity of the procedure can be decreased further.<sup>239</sup> There was no statistically significant difference in complications or graft salvage rates comparing the RFF with the SMF.<sup>244</sup>

**8.2.2.3.3. Gracilis muscle flap (GMF).** The retroflexed GMF has been reported to have a high rate of healing for complex infected groin wounds, even in the presence of a synthetic conduit. It is technically easy to perform and it can be accomplished safely, with a high rate of complete healing.<sup>245</sup> A prospective study reported a 24 month outcome of 22 patients who underwent GMF after complications resulted from arterial bypass surgery: 45% of

patients presented with graft infection, 50% with wound dehiscence, and 5% with graft disruption and bleeding. At one month, 54% of wounds were healed and 100% at three months with adjunctive NPWT and lifelong antibiotics.<sup>246</sup>

**8.2.2.3.4. Rectus abdominis flap (RAF).** When skin closure of the groin wound is desired and impossible following debridement and after infection control, RAF may provide excellent soft tissue coverage with different variations of skin paddle design. This flap has reliable anatomy, with an arc of motion that can address complex defects of the groin. Although flap transfer is highly successful, significant donor site problems, including abdominal hernia, abdominal laxity, and groin hernia have been reported.

**8.2.2.3.5. Musculocutaneous anterolateral thigh flap.** The musculocutaneous anterolateral thigh flap has been reported to have fewer donor site complications and can be used if the flap inflow is not compromised by previous operations.<sup>247,248</sup> In a retrospective study of 39 patients who underwent 30 musculocutaneous anterolateral thigh flaps and 10 RAF procedures, all flap recipient sites healed. Early post-operative complication rates (such as haematomas, surgical site infections, flap dehiscence, or skin graft necrosis) were similar in both groups. Musculocutaneous anterolateral thigh flap patients had a shorter time to healing and fewer post-operative complications than RAF patients.<sup>247</sup>

**8.2.2.3.6. Antibiotic loaded beads.** Antibiotic loaded beads can be implanted adjacent to the infected VG after wound debridement and antibacterial irrigation.<sup>173,249,250</sup> Different types of beads are available, including vancomycin, tobramycin, and gentamicin, or a combination thereof.<sup>250</sup> Conservative treatment can allow complete healing, but reinfection rates following irrigation with antibiotic beads of up to 20% have been reported.<sup>173,250</sup> In a retrospective series of 34 patients (36 limbs) with SSI treated with antibiotic loaded polymethylmethacrylate beads, the lower extremity bypass graft was preserved in 28 limbs and ISR was performed in eight. After a median follow up of 17 months, limb loss was 21.4% and the recurrent infection rate was 19.4%.<sup>173</sup>

**8.2.3. Extra-anatomic reconstruction.** To avoid routing in an infected area or in multi-operated areas, extra-anatomic routing may be mandatory. Extra-anatomic routing is particularly suggested when MRSA, *Pseudomonas*, or multidrug resistant bacteria are present.

**8.2.3.1. Obturator bypass (OB).** OB is used to bypass infection in the groin. The inflow vessel is the intact external iliac artery and the outflow vessel is the distal superficial femoral artery (SFA) or less frequently, the distal deep femoral artery.<sup>251</sup> In a recent retrospective study, 15 patients underwent 18 OBs with a polytetrafluoroethylene (PTFE) prosthesis. Indications for surgery were chronic infection in 10 patients and acute bleeding in five. Midterm

outcomes included five late deaths and one myocardial infarction. Three patients underwent above knee amputation in the 58 months of follow up. Another procedure was required in 11 (61%) limbs. One OB (6%) became infected, requiring removal at 42 months. Primary, primary assisted, and secondary patency rates were 65%, 71%, and 88% at 24 months, respectively.<sup>252</sup> The autologous femoral vein provides an excellent size match and a suitable length for OB.<sup>253</sup>

**8.2.3.2. Lateral retrosartorius bypass (LRSB).** As an alternative route to OB, case reports have been published on LRSB when routing of the graft from the external iliac artery to the distal SFA is needed.<sup>254</sup> The infected area in the groin may affect the approach to the distal anastomosis on the deep femoral artery. A useful technique is to perform the dissection lateral to the sartorius muscle a few centimeters distal to the contaminated wound between healthy tissues.<sup>255</sup> In a recent series of 16 patients with VGI in the groin, 19 lateral femoral bypasses were performed. Three patients were operated on urgently for acute bleeding. The new bypass conduit was tunneled laterally in the clean tissue, medial to the anterior superior iliac spine, and under the inguinal ligament through the psoas canal. The ipsilateral iliac artery was used as an inflow artery and deep femoral artery or SFA as the target distal vessel. Choice of conduit included six (32%) autogenous vein grafts, 10 (53%) allografts, two (11%) rifampicin soaked PET grafts, and one (5.3%) ePTFE graft. Two year primary assisted patency and limb salvage rates were 83% and 93.9%, respectively.<sup>256</sup>

**8.2.3.3. Perigeniculate arteries (PGAs).** PGAs may be useful if the standard exploration of the popliteal artery and the crural vessels is not possible because of infection. If the PGAs have an adequate diameter, they can be used for distal revascularisations.<sup>257</sup> A series of 47 bypasses with the distal anastomosis to the descending genicular artery ( $n = 25$ ) or medial sural artery ( $n = 24$ ) reported peri-operative mortality and amputation rates of 8.5% and 21.3%, respectively. Three year secondary patency, limb salvage, and overall survival rates were respectively, 83%, 74%, and 77%.<sup>257</sup>

**8.2.3.4. Lateral approach to crural arteries (LACA).** Finally, the LACA represents a simple solution to threatened limbs in otherwise difficult situations and LACA may be the ideal approach for vein grafts to the anterior tibial and distal peroneal arteries via a lateral tunnel far away from the infected tissues and with acceptable patency rates.<sup>258</sup> In a series of 21 patients who underwent 23 bypasses for limb salvage (10 due to infection), a LACA approach and subcutaneous graft tunnelling with autologous vein ( $n = 21$ ) and PTFE ( $n = 2$ ) was reported. The distal anastomosis was done to anterior tibial artery ( $n = 16$ ), peroneal artery ( $n = 3$ ), above knee popliteal artery ( $n = 3$ ), and dorsalis pedis ( $n = 1$ ). There were three early (13%) and four late (17%) bypass occlusions. The primary patency at one year was 61% and

the secondary patency 86%. One (4.3%) amputation was required.<sup>258</sup>

**8.2.4. Total or partial graft explantation and need for revascularisation.** For total explantation without revascularisation, arteriotomies performed for VG removal must be closed with biological substitutes, such as saphenous vein or pericardial patch. A secondary bypass can be performed later after total eradication of the infection.

If the VG is well incorporated and does not have any obvious contamination, explantation of the whole graft may not be necessary.<sup>259</sup> The infected part of the VG is usually unattached to the surrounding tissue, allowing for easy removal. The removed part should be replaced with autogenous vein or biological graft material (see 8.2.2.2). Using this approach, elimination of the infection, preservation of limb perfusion, and long term survival are achieved in at most, 70% – 80% of patients presenting with VGI.<sup>225,260,261</sup>

Of the 27 patients who underwent 30 partial PTFE graft explantations, re-infection occurred in 15% during a 27 month follow up.<sup>262</sup> In another series of 86 extracavity VGIs (initial procedure: 24 aortobifemoral bypasses; 19 extra-anatomic bypasses; 31 infra-inguinal bypasses; and 12 combined outflow/inflow reconstructions) the graft was preserved in three patients, graft excision and extra-anatomic bypass was performed in four patients, and graft was removed and replaced with ISR in 79 patients (rifampicin bonded PTFE  $n = 22$ , autologous conduit  $n = 57$ ). Recurrent SSIs occurred in 66% of patients treated initially with graft preservation and 14% of patients receiving rifampicin bonded ISR and in one patient who had an isolated segment of retained PET graft from a previous bypass procedure. One early and five late re-infections (mean interval of 23 months) were reported. Re-infection rates by life table estimate were 2.3% and 8% at one and five years, respectively.<sup>216</sup>

Although several studies have suggested equivalent rates of re-infection and sepsis after partial or complete resection of infected lower extremity bypasses, these patients should be under surveillance until the infection has been eradicated and the wounds are healed owing to the possibility of recurrent infection in the remaining graft.<sup>157,262,263</sup> Consequently, the combination of leaving minimal VG in the surgical field, aggressive irrigation, and antimicrobial therapy may alleviate the risk of further infection.<sup>262</sup> The treatment modality should be tailored to the patient's condition, to the availability of autologous vein, cryopreserved allograft or an alternative vascular conduit, and to the surgeon's experience.<sup>260,264,265</sup>

**8.2.5. Timing of surgery.** Procedures to treat VGI should take place without delay. For any bleeding from an anastomosis, there is a possibility of massive bleeding and the patient should be operated on on an on call basis. Also, abscesses should be drained and devitalised tissue resected within a few hours. Infected graft material should be resected during the same procedure. If there is no critical limb threatening ischaemia after the graft resection, secondary revascularisation may be delayed until the wounds have healed.

**8.3. Follow up and prognosis**

Peripheral VGI is always a serious condition with high risk of amputation and re-infection if all prosthetic material cannot be removed. Surveillance is usually needed not only because of underlying severe lower limb arterial disease, but also to exclude re-infection, especially if resection of the infected material was incomplete. Few reports on surveillance and prognosis after lower limb VGI exist. In a report of 66 cases, 13% had major limb amputation within 30 days post-operatively regardless of location and type of bypass.<sup>266</sup> In another study of 37 cases of femoral VGI, the re-infection rate was 12% and the long term limb salvage rate was 86.5%.<sup>221</sup>

There are no scientific studies on the optimal surveillance protocol. Surveillance after reconstruction should be close until there are no signs of infection. Thereafter, routine follow up visits should be done annually, including laboratory markers of infection and CT. Patients unfit for surgery who are under conservative treatment and lifelong antibiotics should also be under continuous follow up. After the acute situation has settled down, check up every three months during the first year and every 6 – 12 months thereafter if no sign of recurrent infection is seen, can be performed.

Recommendation 49		
For patients with peripheral vascular graft/endograft infection, <i>in situ</i> reconstruction with autologous vein is recommended if removal of the infected graft is likely to lead to limb ischaemia.		
Class	Level	References
I	C	Siracuse <i>et al.</i> (2013) <sup>221</sup>

Recommendation 50		
For patients with peripheral vascular graft/endograft infection limited to only a part of the graft and in patients unfit for surgery, local irrigation and/or negative pressure wound therapy may be considered.		
Class	Level	References
I Ib	C	Thermann and Wollert (2014), <sup>213</sup> Andersson <i>et al.</i> (2018), <sup>218</sup> Monsen <i>et al.</i> (2014) <sup>219</sup>

Recommendation 51		
For patients with a peripheral vascular graft/endograft infection and a large tissue defect, negative pressure wound therapy should be considered in order to promote wound healing following infected graft removal and debridement with or without vascular reconstruction.		
Class	Level	References
I Ia	C	Verma <i>et al.</i> (2015), <sup>215</sup> Armstrong <i>et al.</i> (2007), <sup>216</sup> Cheng <i>et al.</i> (2014) <sup>217</sup> Andersson <i>et al.</i> (2018), <sup>218</sup> Monsen <i>et al.</i> (2014) <sup>219</sup>

Recommendation 52		
For patients with peripheral vascular graft/endograft infection, <i>in situ</i> reconstruction with cryopreserved allografts should be considered as an alternative after infected graft removal if it is likely to lead to limb ischaemia.		
Class	Level	References
Ia	C	Lejay <i>et al.</i> (2017), <sup>147</sup> Ehsan and Gibbons (2009), <sup>223</sup> Zetrenne <i>et al.</i> (2007), <sup>225</sup> Gabriel <i>et al.</i> (2004), <sup>226</sup> Verhelst <i>et al.</i> (2004) <sup>227</sup>

Recommendation 53		
For patients with a peripheral vascular graft/endograft infection and a large tissue defect, muscle or musculocutaneous flaps should be considered to promote groin healing following graft removal and debridement with or without vascular reconstruction.		
Class	Level	References
Ia	B	McMillan <i>et al.</i> (2012), <sup>237</sup> Brewer <i>et al.</i> (2015), <sup>238</sup> Mirzabeigi <i>et al.</i> (2017), <sup>244</sup> Dua <i>et al.</i> (2018) <sup>246</sup>

## 9. PATIENTS' PERSPECTIVES

Whatever the specialty in medicine, the treatment proposal to a patient should be based on a clear, honest and informed consent. The patient should be able to understand the balance between risks and benefits when a surgical procedure is proposed to him/her. As vascular procedures require the use of definitively implanted synthetic devices in the vast majority of the cases, and because infection is a more threatened complication following synthetic material implantation, the risk of VGEI should clearly be explained to the patient.

### 9.1. Specific aspects

The following specifics of vascular procedures must be considered from a patient perspective:

**9.1.1. Pathological presentations.** Vascular procedures are performed either in an emergency setting for life or limb threatening presentations, or for functional impairment or prevention of arterial disease related complications. While the risk of secondary infection is easily accepted in life or limb threatening presentations, this is not the case in the latter presentations.

**9.1.2. Patient age and comorbidities.** Vascular surgery procedures are aimed at a specific population consisting of older patients with a lot of cardiovascular, pulmonary, and renal comorbidities. This particular frailty makes not only secondary interventions more difficult to handle, but also all the management, including imaging procedures with iodine, or antimicrobial therapy.

**9.1.3. The "easy" endovascular surgery.** Currently, most procedures are performed endovascularly in the era of minimally invasive surgery and consequently open surgery

is performed less often. Even if endovascular surgery is a less invasive modality, it must be presented as a treatment option for a severe disease. Moreover, open surgery in the setting of VGEI is more difficult than the initial procedure. This should be explained to patients.

### 9.2. Patient feedback

**9.2.1. Question 1: Did you feel your physician provided enough information about the risk of infection at the time of the initial procedure?** Patients felt that not enough information was provided about the risk of infection: some patients answered that they had not been informed about the risk of infection, while others said that they had been informed but did not understand what a VGEI meant. Some patients had received antibiotic prophylaxis from general physicians, while others had not.

Patients also stated that the the initial procedure was performed in general hospitals, while re-intervention was performed at university hospitals. Later daily care was performed by general physicians lacking experience in advanced knowledge of graft infections, stents, and so on.

**9.2.2. Question 2: What did you think about the management once the diagnosis of VGEI was made?** It seems that the difficulty in obtaining a final diagnosis was generally well understood by patients. They understood the necessity of a complete microbiological and imaging work up. However, it has been pointed out that during the management, the patient moved from one department to another, i.e., vascular surgery, infectious disease, and intensive care unit, which impaired the relationship with a central physician. Patients thought that management was lacking in structure, and that a treatment algorithm was followed.

**9.2.3. Question 3: Did you think your physician provided enough information on the risks related to the VGEI?** Patients thought that they were not aware of the complexity and seriousness of the situation. The majority of patients did not anticipate the difficulties, the pain, or the tiredness induced by the procedures. They mentioned that they were not aware of the close follow up needed after re-intervention.

### 9.3. Ways of improvement

To summarise, the following recommendations from a patient's perspective could be suggested: (i) vascular surgeons must provide more precise information on the risk of VGEI whatever the procedure, even endovascular, and explain precisely what VGEI means in terms of invasiveness; (ii) there is a need to provide more education to general practitioners on antibiotic prophylaxis measures, as well as on when to suspect VGEI to make patients more confident once out of the hospital — precise information about the necessity for post-operative follow up screening is important; (iii) physicians should be more aware of the need for a referral physician to provide information on his/her status, the evolution of the disease, and the next management steps.

## 10. UNRESOLVED ISSUES

The literature review performed to propose these ESVS Guidelines on VGEI demonstrated a lack of robust evidence in many aspects of VGEI management. The literature did not provide enough RCTs, but mostly retrospective studies, literature reviews, and some consensus articles. As a consequence, most recommendations in these guidelines have a low level of evidence, mostly level C. Even the conclusions of papers, including large series, are debatable for the following reasons:

- Populations are difficult to compare because of the multiple clinical presentations, the different microbiology protocols for micro-organism sampling and studies, the different imaging modalities, and the different management options in terms of antimicrobial therapy duration, or choice of vascular substitutes.
- Large series proposing treatment modalities have mostly been published by tertiary centres and most often favour one technique over another. Consequently, there is a high risk of bias related to only publishing positive results while probably not reporting poorer experiences.
- Reviews and meta-analysis, potentially more valid than series, could help in establishing valuable comparisons between different management options. However, they still have to be interpreted with caution because of the previous comments on the potential heterogeneity of the series they pooled.

Consequently, we conclude on the necessity to set up large, multicentre registries that could include patients prospectively with predefined variables allowing for valuable comparisons and conclusions. Such registries could be the way to answer unresolved issues. Accordingly, the WC proposes the following areas for research:

- The evaluation of the risk of brain abscesses in the presentation of VGEI involving the SAT in order to evaluate the potential emergency for management: This major risk is often mentioned, but there are no reliable data available on its incidence (see 5.1).
- The evaluation of the efficacy of EndoVAC therapy: this is mandatory before extensive use, as to date results have only been reported by one team (see 5.2.2).
- The efficacy of conservative treatment of VGEI with drainage and irrigation: it is often presented as a conservative alternative to direct graft explantation, but there are no data reported, as in most series it is only considered as a second line option in unfit patients (see 5.2.1, 6.2.1, 7.2.1, and 8.2.1).
- Evidence on the best antiseptic solutions for irrigation: the literature and expert exchanges demonstrate there is no strong evidence on the different choices in clinical practice (see 4.1).
- Evidence on the efficacy of conservative treatment with implantation of an abdominal or thoracic EG as a bridge: this includes taking into consideration research on the two previous points (see 6.2.2).
- The future role of imaging technologies, including bio-optical imaging, which is a technology allowing evaluation of biomaterials. The wide range of morphological signs corresponding to the different VGEI anatomical locations and clinical presentations requires development of functional imaging. Bio-optical imaging is a technology allowing evaluation of biomaterial associated infections with highly sensitive cameras enabling detection of very few photons from bioluminescent or fluorescent sources inside the body without the need of surgical intervention (see 2.8).
- Antibiotic prophylaxis for invasive manipulation in VGEI carriers (see 3.2.2.2).
- Evidence on the optimal duration of antimicrobial therapies: it is necessary to define the optimal duration and type of antimicrobial treatment depending on the clinical presentation, the anatomical location, and the type of reconstruction, after VGEI according to clinical, biological, and imaging follow up (see 4.1).
- Evidence on the best substitutes for ISR are still needed: this includes clinical evidence of the best coating for an infection resistant VG and evaluation of the risk of microbiological mutation related to the use of a rifampicin soaked VG. The actual risk of re-infection depending on the materials must be evaluated. The growing interest in the effectiveness of xenograft materials for ISR must be evaluated and confirmed (see 6.2.2.2, 7.2.2.2, and 8.2.2.2).
- The best management of duodenal anastomosis, on site or supramesocolic, for AEnF treated by ISR (see 7.3).
- The best management of infected aortic EG constructed with suprarenal bare stents (see 7.2.6).
- The evaluation of secondary endovascular treatment of an occluded superficial femoral artery in infected femoro-popliteal bypass cases (see 8.2).
- The new products that are under evaluation: they include biological extracellular patches such as the one derived from porcine small intestinal mucosa, which provides a biological scaffold for cellular ingrowth and eventual tissue regeneration.
- Vascular tissue engineering is also at the forefront of its translation into practice, as tissue engineered VG have already been successfully implanted in children. There is a high demand in other areas of vascular surgery for ideal graft materials, such as for infection resistant conduits in septic conditions. However, tissue engineered VG are not ready for routine use as the quest for the ideal scaffold materials, cell sources, and *in vitro* culturing conditions continues. Further animal and clinical trials are required.

## APPENDIX AUTHORS' AFFILIATIONS

### Writing Committee

Nabil Chafké (Chair), Department of Vascular Surgery and Kidney Transplantation, University of Strasbourg, University Hospital of Strasbourg, Strasbourg, France; Holger Diener (Co-Chair), Department of Vascular Medicine, University

Heart and Vascular Centre, Hamburg, Germany; Anne Lejay, Department of Vascular Surgery and Kidney Transplantation, University of Strasbourg, University Hospital of Strasbourg, Strasbourg, France; Ojan Assadian, Department for Hospital Epidemiology and Infection Control, Medical University of Vienna, Vienna General Hospital, Vienna, Austria; Xavier Berard, Department of Vascular Surgery, University of Bordeaux, University Hospital of Bordeaux, Bordeaux, France; Jocelyne Caillon, Department of Bacteriology, University Hospital of Nantes, Nantes, France; Inge Fourneau, Department of Vascular Surgery, University Hospitals Leuven, Leuven, Belgium; Andor Glaudemans, Medical Imaging Center, Department of Nuclear Medicine and Molecular Imaging, University of Groningen, University Medical Center Groningen, Groningen, the Netherlands; Igor Koncar, Clinic for Vascular and Endovascular Surgery, Belgrade, Serbia; Jes Lindholt, Department of Cardiovascular and Thoracic Surgery, Odense University Hospital, Odense, Denmark; Germano Melissano, Division of Vascular Surgery, "Vita Salute" University, Scientific Institute H. San Raffaele, Milan, Italy; Ben R. Saleem, Department of Surgery, Division of Vascular Surgery, University Medical Centre Groningen, University of Groningen, Groningen, The Netherlands; Eric Senneville, Department of Infectious Diseases, Gustave Dron Hospital, University of Lille, Tourcoing, France; Riemer H.J.A. Slart, Medical Imaging Center, Department of Nuclear Medicine and Molecular Imaging, University of Groningen, University Medical Center Groningen, Groningen, the Netherlands; Zoltan Szeberin, Department of Vascular Surgery, Semmelweis University, Budapest, Hungary; Omke Teebken, Department of Vascular Surgery, Klinikum Peine, Peine, Germany; Maarit Venermo, Department of Vascular Surgery, University of Helsinki, Helsinki University Hospital, Helsinki, Finland; Frank Vermassen, Department of Thoracic and Vascular Surgery, Ghent University Hospital, Ghent, Belgium; Thomas R. Wyss, Department of Cardiovascular Surgery, Inselspital, Bern University Hospital, University of Bern, Bern, Switzerland.

#### ESVS Guidelines Committee

Gert J. de Borst (Chair), Department of Vascular Surgery, University Medical Centre Utrecht, The Netherlands; Frederico Bastos Gonçalves, University Hospital of Lisboa, NOVA Medical School, Lisbon, Portugal; Stavros K. Kakkos, University of Patras Medical School, Patras, Greece; Philippe Kolh, Department of Biomedical and Preclinical and Sciences, University of Liège, Liège, Belgium; Riikka Tulamo, Department of Vascular Surgery, University of Helsinki, Helsinki University Hospital, Helsinki, Finland; Melina Vega de Ceniga (Review coordinator), Hospital de Galdakao-Usansolo, Bizkaia, Spain.

#### Document Reviewers

Regula S. von Allmen, Clinic for Vascular Surgery, Kantonsspital St Gallen, St. Gallen, Switzerland; Jos C. van den Berg, University Hospital of Bern, Bern, Switzerland; E. Sebastian Debus, Department for Vascular Medicine,

Vascular Surgery, Angiology and Endovascular Interventions, University Heart and Vascular Centre, Hamburg-Eppendorf, Germany; Mark J.W. Koelemay, Department of Surgery, Amsterdam Cardiovascular Sciences, University of Amsterdam, Amsterdam, The Netherlands; Jose P. Linares-Palmino, Department of Vascular Surgery, University Hospital Virgen de las Nieves, Granada University, Granada, Spain; Gregory L.L. Moneta, Division of Vascular Surgery, Knight Cardiovascular Institute, Oregon Health & Science University, Portland, OR, USA; Jean-Baptiste Ricco, Department of Vascular Surgery, University Hospital of Poitiers, Poitiers, France; Anders Wanhainen, Department of Surgical Sciences, Section of Vascular Surgery, Uppsala University, Uppsala, Sweden.

#### REFERENCES

- 1 Lyons OT, Baguneid M, Barwick TD, Bell RE, Foster N, Homer-Vanniasinkam S, et al. Diagnosis of aortic graft infection: a case definition by the management of aortic graft infection collaboration (MAGIC). *Eur J Vasc Endovasc Surg* 2016;**52**:758–63.
- 2 Horan TC, Andrus M, Dudeck MA. CDC/NHSN surveillance definition of health care-associated infection and criteria for specific types of infections in the acute care setting. *Am J Infect Control* 2008;**36**:309–32.
- 3 Szilagyi DE, Smith RF, Elliott JP, Vrandecic MP. Infection in arterial reconstruction with synthetic grafts. *Ann Surg* 1972;**176**:321–33.
- 4 Bunt TJ. Synthetic vascular graft infections. *Graft infections. Surgery* 1983;**93**:733–46.
- 5 Samson RH, Veith FJ, Janko GS, Gupta SK, Scher LA. A modified classification and approach to the management of infections involving peripheral arterial prosthetic grafts. *J Vasc Surg* 1988;**8**:147–53.
- 6 Back MR. Local complications: graft infection. In: Cronenwett JL, Johnston KW, editors. *Rutherford's vascular surgery*; 2014. p. 654–62.
- 7 Tatterson MR, Homer-Vanniasinkam S. Infections in vascular surgery. *Injury* 2011;**42**:35–41.
- 8 Laohapensang K, Arworn S, Orrapin S, Reanpang T, Orrapin S. Management of the infected aortic endograft. *Semin Vasc Surg* 2017;**30**:91–4.
- 9 Hance KA, Hsu J, Eskew T, Hermreck AS. Secondary aorto-esophageal fistula after endoluminal exclusion because of thoracic aortic transection. *J Vasc Surg* 2003;**37**:886–8.
- 10 Porcu P, Chavanon O, Sessa C, Thony F, Aubert A, Blin D. Esophageal fistula after endovascular treatment in a type B aortic dissection of the descending thoracic aorta. *J Vasc Surg* 2005;**41**:708–11.
- 11 Lejay A, Georg Y, Dieval F, Heim F, Tartaglia E, Thaveau F, et al. Properties and challenges in materials used as vascular and endovascular devices. *J Cardiovasc Surg* 2013;**54**:167–82.
- 12 Teebken OE, Bisdas T, Assadian O, Ricco JB. Recommendations for reporting treatment of aortic graft infections. *Eur J Vasc Endovasc Surg* 2012;**43**:174–81.
- 13 Corfield L, Chan J, Chance T, Wilson N. Early pyrexia after endovascular aneurysm repair: are cultures needed? *Ann R Coll Surg Engl* 2011;**93**:111–3.
- 14 Legout L, D'Elia PV, Sarraz-Bournet B, Haulon S, Meybeck A, Senneville E, et al. Diagnosis and management of prosthetic vascular graft infections. *Med Mal Infect* 2012;**42**:102–9.
- 15 Erb S, Sidler JA, Elzi L, Gurke L, Battagay M, Widmer AF, et al. Surgical and antimicrobial treatment of prosthetic vascular graft infections at different surgical sites: a retrospective study of treatment outcomes. *PLoS One* 2014;**9**:e112947.
- 16 Antonios VS, Noel AA, Steckelberg JM, Wilson WR, Mandrekar JN, Harmsen WS, et al. Prosthetic vascular graft

- infection: a risk factor analysis using a case-control study. *J Infect* 2006;**53**:49–55.
- 17 Batt M, Feugier P, Camou F, Coffy A, Senneville E, Caillon J, et al. A meta-analysis of outcomes after in situ reconstructions for aortic graft infection. *Angiology* 2018;**69**:370–9.
- 18 Zimmerli W, Widmer AF, Blatter M, Frei R, Ochsner PE. Role of rifampin for treatment of orthopedic implant-related staphylococcal infections: a randomized controlled trial. Foreign-Body Infection (FBI) Study Group. *JAMA* 1998;**279**:1537–41.
- 19 Widmer AF, Gaechter A, Ochsner PE, Zimmerli W. Antimicrobial treatment of orthopedic implant-related infections with rifampin combinations. *Clin Infect Dis* 1992;**14**:1251–3.
- 20 Senneville E, Joulie D, Legout L, Valette M, Dezèque H, Bertrand E, et al. Outcome and predictors of treatment failure in total hip/knee prosthetic joint infections due to *Staphylococcus aureus*. *Clin Infect Dis* 2011;**53**:334–40.
- 21 Baron EJ, Miller JM, Weinstein MP, Richter SS, Gilligan PH, Thomson Jr RB, et al. A guide to utilization of the microbiology laboratory for diagnosis of infectious diseases: 2013 Recommendations by the Infectious Diseases Society of America (IDSA) and the American Society for Microbiology (ASM). *Clin Infect Dis* 2013;**57**:22–121.
- 22 Osmon DR, Berbari EF, Berendt AR, Lew D, Zimmerli W, Steckelberg JM, et al. Diagnosis and management of prosthetic joint infection: clinical practice guidelines by the infectious diseases society of America. *Clin Infect Dis* 2013;**56**:e1–25.
- 23 Padberg Jr FT, Smith SM, Eng RH. Accuracy of disincorporation for identification of vascular graft infection. *Arch Surg* 1995;**130**:183–7.
- 24 Roelofsen E, van Leeuwen M, Meijer-Severs GJ, Wilkinson MH, Degener JE. Evaluation of the effects of storage in two different swab fabrics and under three different transport conditions on recovery of aerobic and anaerobic bacteria. *J Clin Microbiol* 1999;**37**:3041–3.
- 25 Calori GM, Colombo M, Navone P, Nobile M, Auxilia F, Toscano M, et al. Comparative evaluation of MicroDTTect device and flocked swabs in the diagnosis of prosthetic and orthopaedic infections. *Injury* 2016;**47**:17–21.
- 26 FitzGerald SF, Kelly C, Humphreys H. Diagnosis and treatment of prosthetic aortic graft infections: confusion and inconsistency in the absence of evidence or consensus. *J Antimicrob Chemother* 2005;**56**:996–9.
- 27 Scherrer AU, Bloemberg G, Zbinden R, Zinkernagel AS, Fuchs C, Frauenfelder S, et al. Prosthetic vascular graft infections: bacterial cultures from negative-pressure-wound-therapy foams do not improve diagnostics. *J Clin Microbiol* 2016;**54**:2190–3.
- 28 Bergamini TM, Bandyk DF, Govostis D, Vetsch R, Towne JB. Identification of *Staphylococcus epidermidis* vascular graft infections: a comparison of culture techniques. *J Vasc Surg* 1989;**9**:665–70.
- 29 Tollefson DF, Bandyk DF, Kaebnick HW, Seabrook GR, Towne JB. Surface biofilm disruption. Enhanced recovery of microorganisms from vascular prostheses. *Arch Surg* 1987;**122**:38–43.
- 30 Wengrowitz M, Spangler S, Martin LF. Sonication provides maximal recovery of *Staphylococcus epidermidis* from slime-coated vascular prosthetics. *Am Surg* 1991;**57**:161–4.
- 31 Padberg Jr FT, Smith SM, Eng RH. Optimal method for culturing vascular prosthetic grafts. *J Surg Res* 1992;**53**:384–90.
- 32 Kokosar Ulcar B, Lalic N, Jeverica S, Pecavar B, Logar M, Cerar TK, et al. Contribution of sonicate-fluid cultures and broad-range PCR to microbiological diagnosis in vascular graft infections. *Infect Dis (Lond)* 2017;**20**:1–7.
- 33 Orton DF, LeVeen RF, Saigh JA, Culp WC, Fidler JL, Lynch TJ, et al. Aortic prosthetic graft infections: radiologic manifestations and implications for management. *Radiographics* 2000;**20**:977–93.
- 34 Bruggink JLM, Slart RHJA, Pol JA, Reijnen MMPJ, Zeebregts CJ. Current role of imaging in diagnosing aortic graft infections. *Semin Vasc Surg* 2011;**24**:182–90.
- 35 Spartera C, Morettini G, Petrassi C, Marino G, Minuti U, Pavone P, et al. Role of magnetic resonance imaging in the evaluation of aortic graft healing, perigraft fluid collection, and graft infection. *Eur J Vasc Surg* 1990;**4**:69–73.
- 36 Bruggink JLM, Glaudemans AWJM, Saleem BR, Meerwaldt R, Alkefaji H, Prins TR, et al. Accuracy of FDG-PET/CT in the diagnostic work-up of vascular prosthetic graft infection. *Eur J Vasc Endovasc Surg* 2010;**40**:348–54.
- 37 Reinders Folmer EI, Von Meijenfeldt GCI, Van der Laan MJ, Glaudemans AWJM, Slart RHJA, Saleem BR, et al. Diagnosis imaging in vascular graft infection: a systematic review and meta-analysis. *Eur J Vasc Endovasc Surg* 2018;**56**:719–29.
- 38 Shahidi S, Eskil A, Lundof E, Klaerke A, Jensen BS. Detection of abdominal aortic graft infection: comparison of magnetic resonance imaging and indium-labeled white blood cell scanning. *Ann Vasc Surg* 2007;**21**:586–92.
- 39 Keidar Z, Engel A, Hoffman A, Israel O, Nitecki S. Prosthetic vascular graft infection: the role of 18F-FDG PET/CT. *J Nucl Med* 2007;**48**:1230–6.
- 40 Signore A, Jamar F, Israel O, Buscombe J, Martin-Comin J, Lazzeri E. Clinical indications, image acquisition and data interpretation for white blood cells and anti-granulocyte monoclonal antibody scintigraphy: an EANM procedural guideline. *Eur J Nucl Med Mol Imaging* 2018;**45**:1816–31.
- 41 Jamar F, Buscombe J, Chiti A, Christian PE, Delbeke D, Donohoe LJ, et al. EANM/SNMMI Guideline for 18F-FDG use in inflammation and infection. *J Nucl Med* 2013;**54**:647–58.
- 42 Boellaard R, Delgado-Bolton R, Oyen WJ, Giammarile F, Tatsch K, Eschner W, et al. FDG PET/CT: EANM procedure guidelines for tumour imaging. *Eur J Nucl Med Mol Imaging* 2015;**42**:328–54.
- 43 Sah BR, Husmann L, Mayer D, Scherrer A, Rancic Z, Puipe G, et al. Diagnostic performance of 18F-FDG-PET/CT in vascular graft infections. *Eur J Vasc Endovasc Surg* 2015;**49**:455–64.
- 44 Rabkin Z, Israel O, Keidar Z. Do hyperglycemia and diabetes affect the incidence of false-negative 18F-FDG PET/CT studies in patients evaluated for infection or inflammation and cancer? A comparative analysis. *J Nucl Med* 2010;**51**:1015–20.
- 45 Kagna O, Kurash M, Ghanem-Zoubi N, Keidar Z, Israel O. Does antibiotic treatment affect the diagnostic accuracy of <sup>18</sup>F-FDG PET/CT studies in patients with suspected infectious processes? *J Nucl Med* 2017;**58**:1827–30.
- 46 Moore WS, Malone JM, Keown K. Prosthetic arterial graft material. Influence on neointimal healing and bacteremic infectibility. *Arch Surg* 1980;**115**:1379–83.
- 47 Randall Jr RD, Walley BD, Meredith JH. Comparison of polytetrafluoroethylene (PTFE) and dacron as long, small-diameter arterial grafts in dogs. *Am Surg* 1982;**48**:622–7.
- 48 Haefner TA, Lewis C, Baluh G, Clemens M, Propper B, Arthurs ZM. Initial Inoculation Concentration Does Not Affect Final Bacterial Colonization of In vitro Vascular Conduits. *Surg Infect* 2018;**19**:352–7.
- 49 Rosenman JE, Pearce WH, Kempczinski RF. Bacterial adherence to vascular grafts after in vitro bacteremia. *J Surg Res* 1985;**38**:648–55.
- 50 Schmitt DD, Bandyk DF, Pequet AJ, Towne JB. Bacterial adherence to vascular prostheses. A determinant of graft infectivity. *J Vasc Surg* 1986;**3**:732–40.
- 51 Johnson JJ, Alex Jacobs M, Gauthier SC, Irwin DA, Wolf RF, Garwe T, et al. Establishing a swine model to compare vascular prostheses in a contaminated field. *J Surg Res* 2013;**181**:355–8.
- 52 Zdanowski Z, Ribbe E, Schalén C. Influence of some plasma proteins on in vitro bacterial adherence to PTFE and Dacron vascular prostheses. *APMIS* 1993;**101**:926–32.
- 53 Vogel TR, Symons R, Flum DR. The incidence and factors associated with graft infection after aortic aneurysm repair. *J Vasc Surg* 2008;**47**:264–9.
- 54 Donker JMW, van der Laan L, Hendriks YJAM, Kluytmans JAJW. Evaluation of *Staphylococcus aureus* nasal carriage screening before vascular surgery. *PLoS ONE* 2012;**7**:e38127.

- 55 Langenberg JCM, Kluytmans JAJW, Mulder PGH, Romme J, Ho GH, Van Der Laan L. Peri-operative nasal eradication therapy prevents *Staphylococcus aureus* surgical site infections in aortoiliac surgery. *Surg Infect* 2018;**19**:510–5.
- 56 Stewart AH, Eyers PS, Earnshaw JJ. Prevention of infection in peripheral arterial reconstruction: a systematic review and meta-analysis. *J Vasc Surg* 2007;**46**:148–55.
- 57 van der Slegt J, van der Laan L, Veen EJ, Hendriks Y, Romme J, Kluytmans J. Implementation of a bundle of care to reduce surgical site infections in patients undergoing vascular surgery. *PLoS ONE* 2013;**8**:e71566.
- 58 Wanhainen A, Verzini F, Van Herzele I, Allaire E, Bown M, Cohnert T, et al. European Society for Vascular Surgery (ESVS) 2019 clinical practice guidelines on the management of abdominal aortoiliac aneurysms. *Eur J Vasc Endovasc Surg* 2018;**57**:8–93.
- 59 Stone P, Campbell J, AbuRahma A, Hass SM, Mousa AY, Nanjudappa A, et al. Vascular Surgical Antibiotics Prophylaxis Study (VSAPS). *Vasc Endovasc Surg* 2010;**44**:521–8.
- 60 Stone P, AbuRahma A, Campbull J, Hass SM, Mousa AY, Nanjudappa A, et al. Prospective randomized double-blinded trial comparing 2 anti-MRSA agents with supplemental coverage of cefazolin before lower extremity revascularization. *Ann Surg* 2015;**262**:492–501.
- 61 Zdanowski Z, Danielsson G, Jonung T, Norgren L, Ribbe E, Thorne J, et al. Intraoperative contamination of synthetic vascular grafts. Effect of glove change before graft implantation. A prospective randomised study. *Eur J Vasc Endovasc Surg* 2000;**19**:283–7.
- 62 Parizh D, Ascher E, Raza Rizvi SA, Hingorani A, Amaturro M, Johnson E. Quality improvement initiative: preventative surgical site infection protocol in vascular surgery. *Vascular* 2018;**26**:47–53.
- 63 Habib G, Lancellotti P, Antunes MJ, Bongiorno MG, Casalta JP, Del Zotti F, et al. 2015 ESC Guidelines for the management of infective endocarditis. *Eur Heart J* 2015;**36**:3075–123.
- 64 Kahlberg A, Melissano G, Mascia D, Loschi D, Grandi A, Chiesa R. How to best treat infectious complications of open and endovascular thoracic aortic repairs. *Semin Vasc Surg* 2017;**30**:95–102.
- 65 Darouiche RO. Treatment of infections associated with surgical implants. *N Engl J Med* 2004;**350**:1422–9.
- 66 Spiliotopoulos K, Preventza O, Green SY, Price MD, Amarasekara HS, Davis BM, et al. Open descending thoracic or thoracoabdominal aortic approaches for complications of endovascular aortic procedures: 19-year experience. *J Thorac Cardiovasc Surg* 2018;**155**:10–8.
- 67 Revest M, Camou F, Senneville E, Caillon J, Laurent F, Calvet B, et al. Medical treatment of prosthetic vascular graft infections: review of the literature and proposals of a working group. *Int J Antimicrob Agents* 2015;**46**:254–65.
- 68 Tacconelli E, Cataldo MA, Dancer SJ, De Angelis G, Falcone M, Frank U, et al. ESCMID guidelines for the management of the infection control measures to reduce transmission of multidrug-resistant Gram-negative bacteria in hospitalized patients. *Clin Microbiol Infect* 2014;**20**:1–55.
- 69 Dorigo W, Pulli R, Azas L, Pratesi G, Innocenti AA, Pratesi C. Early and long-term results of conventional surgical treatment of secondary aorto-enteric fistula. *Eur J Vasc Endovasc Surg* 2003;**26**:512–8.
- 70 Jamieson RW, Burns PJ, Dawson AR, Fraser SC. Aortic graft preservation by debridement and omental wrapping. *Ann Vasc Surg* 2012;**26**:423.
- 71 Lejay A, Koncar I, Diener H, Vega De Ceniga M, Chakfé N. Postoperative infection of prosthetic grafts or stents involving the supra aortic trunks: a comprehensive review. *Eur J Vasc Endovasc Surg* 2018;**56**:885–900.
- 72 Knight BC, Tait WF. Dacron patch infection following carotid endarterectomy: a systematic review of the literature. *Eur J Vasc Endovasc Surg* 2009;**37**:140–8.
- 73 Ascitutto G, Geier B, Marpe B, Hummel T, Mumme A. Dacron patch infection after carotid angioplasty. A report of 6 cases. *Eur J Vasc Endovasc Surg* 2007;**33**:55–7.
- 74 Naylor AR, Payne D, London NJ, Thompson MM, Dennis MS, Sayers RD, et al. Prosthetic patch infection after carotid endarterectomy. *Eur J Vasc Endovasc Surg* 2002;**23**:11–6.
- 75 Myles O, Thomas WJ, Daniels JT, Aronson N. Infected endovascular stents managed with medical therapy alone. *Catheter Cardiovasc Interv* 2000;**51**:471–6.
- 76 Oweis Y, Gemmete JJ, Chaudhary N, Pandey A, Ansari S. Delayed development of brain abscesses following stent-graft placement in a head and neck cancer patient presenting with carotid blowout syndrome. *Cardiovasc Intervent Radiol* 2011;**34**:31–5.
- 77 Simental A, Johnson JT, Horowitz M. Delayed complications of endovascular stenting for carotid blowout. *Am J Otolaryngol* 2003;**24**:417–9.
- 78 Rizzo A, Hertzner NR, O'Hara PJ, Krajewski LP, Beven EG. Dacron carotid patch infection: a report of eight cases. *J Vasc Surg* 2000;**32**:602–6.
- 79 Son S, Choi NC, Choi DS, Cho OH. Carotid stent infection: a rare but potentially fatal complication of carotid artery stenting. *BMJ Case Rep* 2014;**27**:2014.
- 80 Lazaris A, Sayers RD, Thompson M, Bell PR, Naylor AR. Patch corrugation on duplex ultrasonography may be an early warning of prosthetic patch infection. *Eur J Vasc Endovasc Surg* 2005;**29**:91–2.
- 81 Pruitt A, Dodson TF, Najibi S, Thourani V, Sherman A, Cloft H, et al. Distal septic emboli and fatal brachiocephalic artery mycotic pseudoaneurysm as a complication of stenting. *J Vasc Surg* 2002;**36**:625–8.
- 82 Younis G, Reul GJ, Krajcerc Z. Combined endovascular and surgical treatment of infected carotid-carotid bypass graft. *J Endovasc Ther* 2006;**13**:687–92.
- 83 Bond KM, Brinjukii W, Murad MH, Cloft HJ, Lanzino G. Endovascular treatment of carotid blowout syndrome. *J Vasc Surg* 2017;**65**:883–8.
- 84 Kragsterman B, Björck M, Wanhainen A. EndoVAC, a novel hybrid technique to treat infected vascular reconstructions with an endograft and vacuum-assisted wound closure. *J Endovasc Ther* 2011;**18**:666–73.
- 85 Thorbjørnsen K, Djavani Gidlund K, Björck M, Kragsterman B, Wanhainen A. Long-term outcome after endoVAC hybrid repair of infected vascular reconstructions. *Eur J Vasc Endovasc Surg* 2016;**51**:724–32.
- 86 Chang F, Lirng JF, Tai SK, Luo CB, Teng MM, Chang CY. Brain abscess formation: a delayed complication of carotid blowout syndrome treated by self-expandable stent-graft. *Am J Neuro-radiol* 2006;**27**:1543–5.
- 87 Grazziotin MU, Stroher CM, Turnipseed WD. Mycotic carotid artery pseudoaneurysm following stenting, a case report and lessons learned. *Vasc Endovasc Surg* 2002;**36**:397–401.
- 88 Kaviani A, Ouriel K, Kashyap VS. Infected carotid pseudoaneurysm and carotid-cutaneous fistula as a late complication of carotid artery stenting. *J Vasc Surg* 2006;**43**:379–82.
- 89 Fields CE, Bower TC. Use of superficial femoral artery to treat an infected great vessel prosthetic graft. *J Vasc Surg* 2004;**40**:559–63.
- 90 Illuminati G, Calio FG, D'Urso A, Ceccanei G, Pacile MA. Management of carotid Dacron patch infection: a case report using median sternotomy for proximal common carotid artery control and in situ polytetrafluoroethylene grafting. *Ann Vasc Surg* 2009;**23**:786.
- 91 El-Sabroun R, Reul G, Cooley DA. Infected postcarotid endarterectomy pseudoaneurysms: retrospective review of a series. *Ann Vasc Surg* 2000;**14**:239–47.
- 92 Bates MC, Almekhmi A. Fatal subclavian stent infection remote from implantation. *Catheter Cardiovasc Interv* 2005;**65**:535–9.
- 93 Zacharoulis DC, Gupta SK, Seymour P, Landa RA. Use of muscle flap to cover infections of the carotid artery after carotid endarterectomy. *J Vasc Surg* 1997;**25**:769–73.



- 94 Litwinski RA, Wright K, Pons P. Pseudoaneurysm formation following carotid endarterectomy: two case reports and literature review. *Ann Vasc Surg* 2006;**20**:678–80.
- 95 Naughton PA, Garcia Toca M, Rodriguez HE, Pearce WH, Eskandari MK, Morasch MD. Carotid artery reconstruction for infected carotid patches. *Eur J Vasc Endovasc Surg* 2010;**40**:492–8.
- 96 Alawy M, Elkassaby M, Shalaby A, Zaki M, Hynes N, Sultan S. Late dacron patch inflammatory reaction after carotid endarterectomy. *Eur J Vasc Endovasc Surg* 2017;**54**:423–9.
- 97 Czerny M, Eggebrecht H, Sodeck G, Weigang E, Livi U, Verzini F, et al. New insights regarding the incidence, presentation and treatment options of aorto-oesophageal fistulation after thoracic endovascular aortic repair: the European Registry of Endovascular Aortic Repair Complications. *Eur J Cardiothorac Surg* 2014;**45**:452–7.
- 98 Czerny M, Reser D, Eggebrecht H, Janata K, Sodeck G, Etz C, et al. Aorto-bronchial and aorto-pulmonary fistulation after thoracic endovascular aortic repair: an analysis from the European Registry of Endovascular Aortic Repair Complications. *Eur J Cardiothorac Surg* 2015;**48**:252–7.
- 99 Chiesa R, Melissano G, Marone EM, Marrocco-Trischitta MM, Kahlberg A. Aorto-oesophageal and aortobronchial fistulae following thoracic endovascular aortic repair: a national survey. *Eur J Vasc Endovasc Surg* 2010;**39**:273–9.
- 100 Kahlberg A, Grandi A, Loschi D, Vermassen F, Moreels N, Chakfe N, et al. Infection of descending thoracic aortic graft and endograft: a systematic review. *J Vasc Surg* 2019;**69**:1941–51.
- 101 Roselli E, Abdel-Halim M, Johnston D, Soltesz E, Greenberg R, Svensson L, et al. Open aortic repair after prior thoracic endovascular aortic repair. *Ann Thorac Surg* 2014;**97**:750–6.
- 102 Kieffer E, Chiche L, Gomes D. Aortoesophageal fistula value of in situ aortic allograft replacement. *Ann Surg* 2003;**238**:283–90.
- 103 Eggebrecht H, Mehta RH, Dechene A, Tsagakis K, Kühl H, Huptas S, et al. Aortoesophageal fistula after thoracic aortic stent-graft placement. A rare but catastrophic complication of a novel emerging technique. *JACC Cardiovasc Interv* 2009;**2**:570–6.
- 104 OTA Lyons, Patel AS, Saha P, Clough RE, Price N, Taylor PR. A 14-year experience with aortic endograft infection: management and results. *Eur J Vasc Endovasc Surg* 2013;**46**:306–13.
- 105 Luehr M, Etz CD, Nozdrzykowski M, Garbade J, Lehmkühl L, Schmidt A, et al. Emergency open surgery for aorto-oesophageal and aorto-bronchial fistulae after thoracic endovascular aortic repair: a single-centre experience. *Eur J Cardiothorac Surg* 2014;**47**:374–83.
- 106 Kahlberg A, Melissano G, Tshomba Y, Leopardi M, Chiesa R. Strategies to treat thoracic aortitis and infected aortic grafts. *J Cardiovasc Surg (Torino)* 2015;**56**:269–80.
- 107 Lemaire SA, Green SY, Kim JH, Sameri A, Parenti JL, Lin PH, et al. Thoracic or thoracoabdominal approaches to endovascular device removal and open aortic repair. *Ann Thorac Surg* 2012;**93**:726–33.
- 108 Vogt P, Pfammater T, Schlupf R, Genoni M, Künzli A, Candidas D, et al. In situ repair of aortobronchial, aortoesophageal and aortoenteric fistulae with cryopreserved aortic homografts. *J Vasc Surg* 1997;**26**:11–7.
- 109 Coselli J, Spiliotopoulos K, Preventza O, de la Cruz K, Amarasekara H, Green S. Open aortic surgery after thoracic endovascular aortic repair. *Gen Thorac Cardiovasc Surg* 2016;**64**:441–9.
- 110 Smeds MR, Duncan AA, Harlander-Locke MP, Lawrence PF, Lyden S, Fatima J, et al. Treatment and outcomes of aortic endograft infection. *J Vasc Surg* 2016;**63**:332–40.
- 111 Chiesa R, Tshomba A, Kahlberg A, Civilini E, Coppi G, Psacharopoulou D, et al. Management of thoracic endograft infection. *J Cardiovasc Surg* 2010;**51**:15–31.
- 112 Girdauskas E, Falk V, Kuntze T, Borger M, Schmidt A, Scheinert D, et al. Secondary surgical procedures after endovascular stent grafting of the thoracic aorta: successful approaches to a challenging clinical problem. *J Thorac Cardiovasc Surg* 2008;**136**:1289–94.
- 113 Lutz B, Reeps C, Biro G, Knappich C, Zimmermann A, Eckstein HH. Bovine pericardium as new technical option for in situ reconstruction of aortic graft infection. *Ann Vasc Surg* 2017;**41**:118–26.
- 114 Weiss S, Tobler EL, von Tengg-Kobligk H, Malaloski V, Becker D, Carrel TP, et al. Self made xeno-pericardial aortic tubes to treat native and aortic graft infections. *Eur J Vasc Endovasc Surg* 2017;**54**:646–52.
- 115 Kreibich M, Siepe M, Morlock J, Beyersdorf F, Kondov S, Scheumann J, et al. Surgical treatment of native and prosthetic aortic infection with xenopericardial tube grafts. *Ann Thorac Surg* 2018;**106**:498–504.
- 116 Riesenman PJ, Farber MA. Management of a thoracic endograft infection through an ascending to descending extra-anatomic aortic bypass and endograft explantation. *J Vasc Surg* 2010;**51**:207–9.
- 117 Moulakakis KG, Mylonas SN, Antonopoulos CN, Kakisis JD, Sfyroeras GS, Mantas G, et al. Comparison of treatment strategies for thoracic endograft infection. *J Vasc Surg* 2013;**60**:1061–71.
- 118 Kasai K, Ushio A, Tamura Y, Sawara K, Kasai Y, Oikawa K, et al. Conservative treatment of an aortoesophageal fistula after endovascular stent grafting for a thoracic aortic aneurysm. *Med Sci Monit* 2011;**17**:39–42.
- 119 Jonker F, Heijmen R, Trimarchi S, Verhagen H, Moll F, Muhs B. Acute management of aortobronchial and aortoesophageal fistulas using thoracic endovascular aortic repair. *J Vasc Surg* 2009;**50**:999–1004.
- 120 Civilini E, Bertoglio L, Melissano G, Chiesa R. Aortic and esophageal endografting for secondary aortoenteric fistula. *Eur J Vasc Endovasc Surg* 2008;**36**:297–9.
- 121 Uno K, Koike T, Takahashi S, Komazawa D, Shomosegawa T. Management of aorto-esophageal fistula secondary after thoracic endovascular repair: a review of the literature. *Clin J Gastroenterol* 2017;**10**:392–402.
- 122 Kahlberg A, Tshomba Y, Marone E, Castellano R, Melissano G, Chiesa R. Current results of a combined endovascular and open approach for the treatment of aortoesophageal and aortobronchial fistulae. *Ann Vasc Surg* 2014;**28**:1782–8.
- 123 Canaud L, Ozdemir BA, Bahia S, Hinchliffe R, Loftus I, Thompson M. Thoracic endovascular aortic repair for aortobronchial fistula. *Ann Thorac Surg* 2013;**96**:1117–22.
- 124 Riesenman P, Brooks J, Farber M. Thoracic endovascular aortic repair of aortobronchial fistulas. *J Vasc Surg* 2009;**50**:992–8.
- 125 Canaud L, D'Annoville T, Ozdemir B, Marty-Ané C, Alric P. Combined endovascular and surgical approach for aortobronchial fistula. *J Thorac Cardiovasc Surg* 2014;**148**:2108–11.
- 126 Canaud L, Alric P, Gandet T, Ozdemir BA, Albat B, Marty-Ané C. Open surgical secondary procedures after thoracic endovascular aortic repair. *Eur J Vasc Endovasc Surg* 2013;**46**:667–74.
- 127 Jonker FHW, Schlösser FJV, Moll FL, van Herwaarden JA, Indes JE, Verhagen HJM, et al. Outcomes of thoracic endovascular aortic repair for aortobronchial and aortoesophageal fistulas. *J Endovasc Ther* 2009;**16**:428–40.
- 128 Picichè M, De Paulis R, Fabbri A, Chiariello L. Postoperative aortic fistulas into the airways: etiology, pathogenesis, presentation, diagnosis, and management. *Ann Thorac Surg* 2003;**75**:1998–2006.
- 129 De Rango P, Estrera A, Azizzadeh A, Keyhani K, Safi H. Two stage repair of aortobronchial fistula. *Ann Thorac Surg* 2010;**89**:275–7.
- 130 Canaud L, Ozdemir BA, Bee WW, Bahia S, Holt P, Thompson M, et al. Thoracic endovascular aortic repair in management of aortoesophageal fistulas. *J Vasc Surg* 2014;**59**:248–54.

- 131 Berger P, De Borst GJ, Moll FL. Current opinions about diagnosis and treatment strategy for aortic graft infections in The Netherlands. *J Cardiovasc Surg (Torino)* 2015;**56**:867–76.
- 132 Argyriou C, Georgiadis GS, Lazarides MK, Georgakarakos E, Antoniou GA. Endograft infection after endovascular abdominal aortic aneurysm repair: a systematic review and meta-analysis. *J Endovasc Ther* 2017;**24**:688–97.
- 133 Kahlberg A, Rinaldi E, Piffaretti G, Speziale F, Trimarchi S, Bonardelli S, et al. Results from the Multicenter Study on Aortoenteric Fistulization After Stent Grafting of the Abdominal Aorta (MAEFISTO). *J Vasc Surg* 2016;**64**:313–20.
- 134 Kakkos SK, Bicknell CD, Tsolakis IA, Bergqvist D. Hellenic Cooperative Group on Aortic Surgery. Editor's Choice – Management of secondary aorto-enteric and other abdominal arterioenteric fistulas: a review and pooled data analysis. *Eur J Vasc Endovasc Surg* 2016;**52**:770–86.
- 135 Calligaro KD, Veith FJ, Yuan JG, Gargiulo NJ, Dougherty MJ. Intra-abdominal aortic graft infection: complete or partial graft preservation in patients at very high risk. *J Vasc Surg* 2003;**38**:1199–205.
- 136 Sharif MA, Lee B, Lau LL, Ellis PK, Collins AJ, Blair PH, et al. Prosthetic stent graft infection after endovascular abdominal aortic aneurysm repair. *J Vasc Surg* 2007;**46**:442–8.
- 137 Batt M, Jean-Baptiste E, O'Connor S, Feugier P, Haulon S. Contemporary management of infrarenal aortic graft infection: early and late results in 82 patients. *Vascular* 2012;**20**:129–37.
- 138 Ohta T, Hosaka M, Ishibashi H, Sugimoto I, Takeuchi N, Kazui H, et al. Treatment for aortic graft infection. *Surg Today* 2001;**31**:18–26.
- 139 Igari K, Kudo T, Toyofuku T, Jibiki M, Suagano N, Inoue Y. Treatment strategies for aortic and peripheral prosthetic graft infections. *Surg Today* 2014;**44**:466–71.
- 140 Oderich GS, Bower TC, Hofer J, Kalra M, Duncan AA, Wilson JW, et al. In situ rifampin-soaked grafts with omental coverage and antibiotic suppression are durable with low reinfection rates in patients with aortic graft enteric erosion or fistula. *J Vasc Surg* 2011;**53**:99–106.
- 141 Miyamoto K, Inaba M, Kojima T, Niguma T, Mimura T. Intra-Aortic Balloon Occlusion (IABO) may be useful for the management of secondary aortoduodenal fistula (SADF): a case report. *Int J Surg Case Rep* 2016;**25**:234–7.
- 142 Dorweiler B, Neufang A, Chaban R, Reinstadler J, Duenschede F, Vahl CF. Use and durability of femoral vein for autologous reconstruction with infection of the aortoiliac axis. *J Vasc Surg* 2014;**59**:675–83.
- 143 Heinola I, Kantonen I, Jaroma M, Albäck A, Vikatmaa P, Aho P, et al. Editor's Choice – treatment of aortic prosthesis infections by graft removal and in situ replacement with autologous femoral veins and fascial strengthening. *Eur J Vasc Endovasc Surg* 2016;**51**:232–9.
- 144 Oderich GS, Bower TC, Cherry Jr KJ, Panneton JM, Sullivan TM, Noel AA, et al. Evolution from axillofemoral to in situ prosthetic reconstruction for the treatment of aortic graft infections at a single center. *J Vasc Surg* 2006;**43**:1166–74.
- 145 Ali AT, Modrall JG, Hocking J, Valentine RJ, Spencer H, Eidt JF, et al. Long-term results of the treatment of aortic graft infection by in situ replacement with femoral popliteal vein grafts. *J Vasc Surg* 2009;**50**:30–9.
- 146 Bíró G, Szabó G, Fehérvári M, Münch Z, Szeberin Z, Acsády G. Late outcome following open surgical management of secondary aortoenteric fistula. *Langenbecks Arch Surg* 2011;**396**:1221–9.
- 147 Lejay A, Delay C, Girsowicz E, Chenesseau B, Bonnin E, Ghariani MZ, et al. Cryopreserved cadaveric arterial allograft for arterial reconstruction in patients with prosthetic infection. *Eur J Vasc Endovasc Surg* 2017;**54**:636–44.
- 148 Harlander-Locke MP, Harmon LK, Lawrence PF, Oderich GS, McCready RA, Morasch MD, et al. The use of cryopreserved aortoiliac allograft for aortic reconstruction in the United States. *J Vasc Surg* 2014;**59**:669–74.
- 149 Heo SH, Kim YW, Woo SY, Park YJ, Kim DK, Chung DR. recent results of in situ abdominal aortic reconstruction with cryopreserved arterial allograft. *Eur J Vasc Endovasc Surg* 2017;**53**:158–67.
- 150 Touma J, Cochenec F, Parisot J, Fialaire Legendre A, Becquemin JP, Desgranges P. In situ reconstruction in native and prosthetic aortic infections using cryopreserved arterial allografts. *Eur J Vasc Endovasc Surg* 2014;**48**:292–9.
- 151 Bisdas T, Bredt M, Pichlmaier M, Aper T, Wilhelmi M, Bisdas S, et al. Eight-year experience with cryopreserved arterial homografts for the in situ reconstruction of abdominal aortic infections. *J Vasc Surg* 2010;**52**:323–30.
- 152 Garot M, Delannoy PY, Meybeck A, Sarraz-Bournet B, d'Elia P, d'Escrivan T, et al. Intra-abdominal aortic graft infection: prognostic factors associated with in-hospital mortality. *BMC Infect Dis* 2014;**14**:215.
- 153 Kieffer E, Gomes D, Chiche L, Fléron MH, Koskas F, Bahnini A. Allograft replacement for infrarenal aortic graft infection: early and late results in 179 patients. *J Vasc Surg* 2004;**39**:1009–17.
- 154 Ben Ahmed S, Louvancourt A, Daniel G, Combe P, Duprey A, Albertini JN, et al. Cryopreserved arterial allografts for in situ reconstruction of abdominal aortic native or secondary graft infection. *J Vasc Surg* 2018;**67**:468–77.
- 155 Young RM, Cherry Jr KJ, Davis PM, Gloviczki P, Bower TC, Panneton JM, et al. The results of in situ prosthetic replacement for infected aortic grafts. *Am J Surg* 1999;**178**:136–40.
- 156 Hayes PD, Nasim A, London NJ, Sayers RD, Barrie WW, Bell PR, et al. In situ replacement of infected aortic grafts with rifampicin-bonded prostheses: the Leicester experience. *J Vasc Surg* 1999;**30**:92–8.
- 157 Bandyk DF, Navotney ML, Back MR, Johnson BL, Schmacht DC. Expanded application of in situ replacement for prosthetic graft infection. *J Vasc Surg* 2001;**34**:411–9.
- 158 Torsello G, Sandmann W. Use of antibiotic-bonded grafts in vascular graft infection. *Eur J Vasc Endovasc Surg* 1997;**14**:84–7.
- 159 Koshiko S, Sasajima T, Muraki S, Azuma N, Yamazaki K, Chiba K, et al. Limitations in the use of rifampicin-gelatin grafts against virulent organisms. *J Vasc Surg* 2002;**35**:779–85.
- 160 Vicaretti M, Hawthorne W, Ao PY, Fletcher JP. Does in situ replacement of a staphylococcal infected vascular graft with a rifampicin impregnated gelatin sealed Dacron graft reduce the incidence of subsequent infection? *Int Angiol* 2000;**19**:158–65.
- 161 Ueberrueck T, Zippel R, Tautenhahn J, Gastinger I, Lippert H, Wahlers T. Vascular graft infections: in vitro and in vivo investigations of a new vascular graft with long-term protection. *J Biomed Mater Res B Appl Biomater* 2005;**74**:601–7.
- 162 Ricco JB, Assadian A, Schneider F, Assadian O. In vitro evaluation of the antimicrobial efficacy of a new silver-triclosan vs a silver collagen-coated polyester vascular graft against methicillin-resistant *Staphylococcus aureus*. *J Vasc Surg* 2012;**55**:823–9.
- 163 Mirzaie M, Schmitto JD, Tirilomis T, Fatehpur S, Liakopoulos OJ, Teucher N, et al. Surgical management of vascular graft infection in severely ill patients by partial resection of the infected prosthesis. *Eur J Vasc Endovasc Surg* 2007;**33**:610–3.
- 164 Zegelman M, Guenther G, Waliszewski M, Pukacki F, Stanisic MG, Piquet P, et al. Results from the International Silver Graft Registry for high-risk patients treated with a metallic-silver impregnated vascular graft. *Vascular* 2013;**21**:137–47.
- 165 Kubota H, Endo H, Noma M, Ishii H, Tsuchiya H, Yoshimoto A, et al. Xenopericardial roll graft replacement for infectious pseudoaneurysms and graft infections of the aorta. *J Cardiothorac Surg* 2015;**10**:133.
- 166 Anibueze C, Sankaran V, Sadat U, Tan K, Wilson YG, Brightwell RE, et al. Neoaortic xenoprosthetic grafts for

- treatment of mycotic aneurysms and infected aortic grafts. *Ann Vasc Surg* 2017;44:419.
- 167 Czerny M, von Allmen R, Opfermann P, Sodeck G, Dick F, Stellmes A, et al. Self-made pericardial tube graft: a new surgical concept for treatment of graft infections after thoracic and abdominal aortic procedures. *Ann Thorac Surg* 2011;92:1657–62.
- 168 Rahman IA, Angelini GD, Hamilton M, Bryan AJ. Pericardial neo-aorta to bridge long segment defects after infected aortic reconstructions. *J Card Surg* 2013;28:295–7.
- 169 Krasznai AG, Snoeijis M, Siroen MP, Sigterman T, Korsten A, Moll FL, et al. Treatment of aortic graft infection by in situ reconstruction with Omniflow II biosynthetic prosthesis. *Vascular* 2016;24:561–6.
- 170 Stather PW, Howard AQ. A novel technique for bifurcated bovine plus Omniflow aortic graft reconstruction. *Eur J Vasc Endovasc Surg* 2017;53:104.
- 171 Inoue T, Imura M, Kaneda T, Saga T. Long-term survival after coverage with prevertebral fascia for abdominal aortic stump closure. *Vasc Endovascular Surg* 2017;51:43–6.
- 172 Genovese EA, Avgerinos ED, Baril DT, Makaroun MS, Chaer RA. Bioabsorbable antibiotic impregnated beads for the treatment of prosthetic vascular graft infections. *Vascular* 2016;24:590–7.
- 173 Stone PA, Mousa AY, Hass SM, Dearing DD, Campbell 2nd JR, Parker A, et al. Antibiotic-loaded polymethylmetacrylate beads for the treatment of extracavity vascular surgical site infections. *J Vasc Surg* 2012;55:1706–11.
- 174 Mayer D, Hasse B, Koelliker J, Enzler M, Veith FJ, Rancic Z, et al. Long-term results of vascular graft and artery preserving treatment with negative pressure wound therapy in Szilagyí grade III infections justify a paradigm shift. *Ann Surg* 2011;254:754–9.
- 175 Seeger JM, Pretus HA, Welborn MB, Ozaki CK, Flynn TC, Huber TS. Long-term outcome after treatment of aortic graft infection with staged extra-anatomic bypass grafting and aortic graft removal. *J Vasc Surg* 2000;32:451–9.
- 176 Brown KE, Heyer K, Rodriguez H, Eskandari MK, Pearce WH, Morasch MD. Arterial reconstruction with cryopreserved human allografts in the setting of infection: a single-center experience with midterm follow-up. *J Vasc Surg* 2009;49:660–6.
- 177 Charlton-Ouw KM, Kubrusly F, Sandhu HK, Swick MC, Leake SS, Gulbis BE, et al. In vitro efficacy of antibiotic beads in treating abdominal vascular graft infections. *J Vasc Surg* 2015;62:1048–53.
- 178 Jausseran JM, Stella N, Courbier R, Bergeron P, Ferdani M, Houel H, et al. Total prosthetic graft excision and extra-anatomic bypass. *Eur J Vasc Endovasc Surg* 1997;14:59–65.
- 179 Yeager RA, Taylor Jr LM, Moneta GL, Edwards JM, Nicoloff AD, McConnell DB, et al. Improved results with conventional management of infrarenal aortic infection. *J Vasc Surg* 1999;30:76–83.
- 180 O'Connor S, Andrew P, Batt M, Becquemin JP. A systematic review and meta-analysis of treatments for aortic graft infection. *J Vasc Surg* 2006;44:38–45.
- 181 Reilly LM, Stoney RJ, Goldstone J, Ehrenfeld WK. Improved management of aortic graft infection: the influence of operation sequence and staging. *J Vasc Surg* 1987;5:421–31.
- 182 Sarac TP, Augustinos P, Lyden S, Ouriel K. Use of fascia-peritoneum patch as a pledget for an infected aortic stump. *J Vasc Surg* 2003;38:1404–6.
- 183 Yamanaka K, Omura A, Nomura Y, Miyahara S, Shirasaka T, Sakamoto T, et al. Surgical strategy for aorta-related infection. *Eur J Cardiothorac Surg* 2014;46:974–80.
- 184 Hart JP, Eginton MT, Brown KR, Seabrook GR, Lewis BD, Edmiston Jr CE, et al. Operative strategies in aortic graft infections: is complete graft excision always necessary? *Ann Vasc Surg* 2005;19:154–60.
- 185 Lesèche G, Castier Y, Petit MD, Bertrand P, Kitzis M, Mussot S, et al. Long-term results of cryopreserved arterial allograft reconstruction in infected prosthetic grafts and mycotic aneurysms of the abdominal aorta. *Vasc Surg* 2001;34:616–22.
- 186 Simmons CD, Ali AT, Foteh K, Abate MR, Smeds MR, Spencer HJ, et al. Unilateral inline replacement of infected aortofemoral graft limb with femoral vein. *J Vasc Surg* 2017;65:1121–9.
- 187 Phang D, Smeds MR, Abate M, Ali A, Long B, Rahimi M, et al. Revascularization with obturator or hemi-neoortoiliac system for partial aortic graft infections. *Ann Vasc Surg* 2019;54:166–75.
- 188 Crawford JD, Landry GJ, Moneta GL, Mitchell EL. Outcomes of unilateral graft limb excision for infected aortobifemoral graft limb. *J Vasc Surg* 2016;63:407–13.
- 189 Fatima J, Duncan AA, de Grandis E, Oderich GS, Kalra M, Gloviczki P, et al. treatment strategies and outcomes in patients with infected aortic endografts. *J Vasc Surg* 2013;58:371–9.
- 190 Davila VJ, Stone W, Duncan AA, Wood E, Jordan Jr WD, Zea N, et al. A multicenter experience with the surgical treatment of infected abdominal aortic endografts. *J Vasc Surg* 2015;62:877–83.
- 191 Chaufour X, Gaudric J, Goueffic Y, Khodja RH, Feugier P, Malikov S, et al. A multicenter experience with infected abdominal aortic endograft explantation. *J Vasc Surg* 2017;65:372–80.
- 192 Schoell T, Manceau G, Chiche L, Gaudric J, Gibert H, Tresallet C, et al. Surgery for secondary aorto-enteric fistula or erosion (SAEFE) complicating aortic graft replacement: a retrospective analysis of 32 patients with particular focus on digestive management. *World J Surg* 2015;39:283–91.
- 193 Kakkos SK, Antoniadis PN, Klonaris CN, Papazoglou KO, Giannoukas AD, Matsagkas MI, et al. Open or endovascular repair of aortoenteric fistulas? A multicentre comparative study. *Eur J Vasc Endovasc Surg* 2011;41:625–34.
- 194 Burks Jr JA, Faries PL, Gravereaux EC, Hollier LH, Marin ML. Endovascular repair of bleeding aortoenteric fistulas: a 5-year experience. *J Vasc Surg* 2001;34:1055–9.
- 195 Biancari F, Romsis P, Perälä J, Koivukangas V, Cresti R, Juvonen T. Staged endovascular stent-grafting and surgical treatment of a secondary aortoduodenal fistula. *Eur J Vasc Endovasc Surg* 2006;31:42–3.
- 196 Franchin M, Tozzi M, Piffaretti G, Carrafiello G, Castelli P. Emergency endovascular 'bridge' treatment for iliac-enteric fistula. *Cardiovasc Intervent Radiol* 2011;34:1106–8.
- 197 Chick JFB, Castle JC, Cooper KJ, Srinivasa RN, Eliason JL, Osborne NH, et al. Aortoenteric fistulae temporization and treatment: lessons learned from a multidisciplinary approach to 3 patients. *Radiol Case Rep* 2017;12:331–4.
- 198 Batt M, Jean-Baptiste E, O'Connor S, Saint-Lebes B, Feugier P, Patra P, et al. Early and late results of contemporary management of 37 secondary aortoenteric fistulae. *Eur J Vasc Endovasc Surg* 2011;41:748–57.
- 199 Bergqvist Björck M. Secondary arterioenteric fistulation – a systematic literature analysis. *Eur J Vasc Endovasc Surg* 2009;37:31–42.
- 200 Rodrigues dos Santos C, Casaca R, Mendes de Almeida JC, Mendes-Pedro L. Enteric repair in aortoduodenal fistulas: a forgotten but often lethal player. *Ann Vasc Surg* 2014;28:756–62.
- 201 Delva JC, Déglise S, Bérard X, Dubuisson V, Delva F, Stecken L, et al. In-situ revascularisation for secondary aorto-enteric fistulae: the success of silver-coated Dacron is closely linked to a suitable bowel repair. *Eur J Vasc Endovasc Surg* 2012;44:417–24.
- 202 Johnston PC, Guercio AF, Johnson SP, Hollis Jr HW, Pratt CF, Rehling TF. Endovascular recanalization of the superior mesenteric artery in the context of mesenteric bypass graft infection. *J Vasc Surg* 2013;57:1398–400.
- 203 Mufty H, Fourneau I. Gastric erosion by abscess 15 years after mesenteric bypass surgery. *Eur J Vasc Endovasc Surg* 2017;54:93.
- 204 van den Bergh RC, Moll FL, de Vries JP, Lock TM. Arterioureteral fistulas: unusual suspects-systematic review of 139 cases. *Urology* 2009;74:251–5.

- 205 Das A, Lewandoski P, Laganosky D, Walton J, Shenot P. Ureteroarterial fistula: a review of the literature. *Vascular* 2016;**24**:203–7.
- 206 Malgor RD, Oderich GS, Andrews JC, McKusick M, Kalra M, Misra S, et al. Evolution from open surgical to endovascular treatment of ureteral-iliac artery fistula. *J Vasc Surg* 2012;**55**:1072–80.
- 207 Madoff DC, Gupta S, Toombs BD, Skolkin MD, Charnsangavej C, Morello Jr FA, et al. Arterioureteral fistulas: a clinical, diagnostic, and therapeutic dilemma. *AJR Am J Roentgenol* 2004;**182**:1241–50.
- 208 Pillai AK, Anderson ME, Reddick MA, Sutphin PD, Kalva SP. Ureteroarterial fistula: diagnosis and management. *AJR Am J Roentgenol* 2015;**204**:592–8.
- 209 Eiberg JP, Røder O, Stahl-Madsen M, Eldrup N, Qvarfordt P, Laursen A, et al. Fluoropolymer-coated dacron versus PTFE grafts for femorofemoral crossover bypass: randomised trial. *Eur J Vasc Endovasc Surg* 2006;**32**:431–8.
- 210 Exton RJ, Galland RB. Major groin complications following the use of synthetic grafts. *Eur J Vasc Endovasc Surg* 2007;**34**:188–90.
- 211 Brothers TE, Robison JG, Elliott BM. Predictors of prosthetic graft infection after infrainguinal bypass. *J Am Coll Surg* 2009;**208**:557–61.
- 212 Bosman WM, Borger van der Burg BL, Schuttevaer HM, Thoma S, Hedeman Joosten PP. Infections of intravascular bare metal stents: a case report and review of the literature. *Eur J Vasc Endovasc Surg* 2014;**47**:87–9.
- 213 Thermann F, Wollert U. Continuous irrigation as a therapeutic option for graft infections of the groin. *World J Surg* 2014;**38**:2589–96.
- 214 Saleem BR, Meerwaldt R, Tielliu IF, Verhoeven EL, van den Dungen JJ, Zeebregts CJ. Conservative treatment of vascular prosthetic graft infection is associated with high mortality. *Am J Surg* 2010;**200**:47–52.
- 215 Verma H, Ktenidis K, George RK, Tripathi R. Vacuum-assisted closure therapy for vascular graft infection (Szilagy grade III) in the groin—a 10-year multi-center experience. *Int Wound J* 2015;**12**:317–21.
- 216 Armstrong PA, Back MR, Bandyk DF, Johnson BL, Shames ML. Selective application of sartorius muscle flaps and aggressive staged surgical debridement can influence long-term outcomes of complex prosthetic graft infections. *J Vasc Surg* 2007;**46**:71–8.
- 217 Cheng HT, Hsu YC, Wu CI. Efficacy and safety of negative pressure wound therapy for Szilagy grade III peripheral vascular graft infection. *Interact Cardiovasc Thorac Surg* 2014;**19**:1048–52.
- 218 Andersson S, Monsen C, Acosta S. Outcome and complications using negative pressure wound therapy in the groin for perivascular surgical site infections after vascular surgery. *Ann Vasc Surg* 2018;**48**:104–10.
- 219 Monsen C, Wann-Hansson C, Wictorsson C, Acosta S. Vacuum-assisted wound closure versus alginate for the treatment of deep perivascular wound infections in the groin after vascular surgery. *J Vasc Surg* 2014;**59**:145–51.
- 220 Chatterjee A, Macarios D, Griffin L, Kosowski T, Pyfer BJ, Offodile 2nd AC, et al. Cost-utility analysis: sartorius flap versus negative pressure therapy for infected vascular groin graft management. *Plast Reconstr Surg Glob Open* 2015;**3**:11–9.
- 221 Siracuse JJ, Nandivada P, Giles KA, Hamdan AD, Wyers MC, Chaikof EL, et al. Prosthetic graft infections involving the femoral artery. *J Vasc Surg* 2013;**57**:700–5.
- 222 Gassel HJ, Klein I, Steger U, Kellersmann R, Hamelmann W, Franke S, et al. Surgical management of prosthetic vascular graft infection: comparative retrospective analysis of 30 consecutive cases. *Vasa* 2002;**3**:48–55.
- 223 Ehsan O, Gibbons CP. A 10-year experience of using femoropopliteal vein for re-vascularisation in graft and arterial infections. *Eur J Vasc Endovasc Surg* 2009;**38**:172–9.
- 224 Teebken OE, Pichlmaier MA, Brand S, Haverich A. Cryopreserved arterial allografts for in situ reconstruction of infected arterial vessels. *Eur J Vasc Endovasc Surg* 2004;**27**:597–602.
- 225 Zetrenne E, McIntosh BC, McRae MH, Gusberg R, Evans GR, Narayan D. Prosthetic vascular graft infection: a multicenter review of surgical management. *Yale J Biol Med* 2007;**80**:113–21.
- 226 Gabriel M, Pukacki F, Ł Dzieciuchowicz, Oszkini G, Checiński P. Cryopreserved arterial allografts in the treatment of prosthetic graft infections. *Eur J Vasc Endovasc Surg* 2004;**27**:590–6.
- 227 Verhelst R, Lacroix V, Vraux H, Lavigne JP, Vandamme H, Limet R, et al. Use of cryopreserved arterial homografts for management of infected prosthetic grafts: a multicentric study. *Ann Vasc Surg* 2000;**14**:602–7.
- 228 McCready RA, Bryant MA, Fehrenbacher JW, Beckman DJ, Coffey AC, Corvera JS, et al. Long-term results with cryopreserved arterial allografts (CPAs) in the treatment of graft or primary arterial infections. *J Surg Res* 2011;**168**:149–53.
- 229 Minga Lowampa E, Holemans C, Stiennon L, Van Damme H, Defraigne JO. Late fate of cryopreserved arterial allografts. *Eur J Vasc Endovasc Surg* 2016;**52**:696–702.
- 230 O'Banion LA, Wu B, Eichler CM, Reilly LM, Conte MS, Hiramoto JS. Cryopreserved saphenous vein as a last-ditch conduit for limb salvage. *J Vasc Surg* 2017;**66**:844–9.
- 231 Randon C, Jacobs B, De Ryck F, Beele H, Vermassen F. Fifteen years of infrapopliteal arterial reconstructions with cryopreserved venous allografts for limb salvage. *J Vasc Surg* 2010;**51**:869–77.
- 232 Earnshaw JJ. The current role of rifampicin-impregnated grafts: pragmatism versus science. *Eur J Vasc Endovasc Surg* 2000;**20**:409–12.
- 233 Berard X, Stecken L, Pinaquy JB, Cazanave C, Puges M, Pereyre S, et al. Comparison of the antimicrobial properties of silver impregnated vascular grafts with and without triclosan. *Eur J Vasc Endovasc Surg* 2016;**51**:285–92.
- 234 Matic P, Tanaskovic S, Babic S, Gajin P, Jovic D, Nenezic D, et al. In situ revascularization for femoropopliteal graft infection: ten years experience with silver grafts. *Vascular* 2014;**22**:323–7.
- 235 Töpel I, Audebert F, Betz T, Steinbauer MG. Microbial spectrum and primary resistance to rifampicin in infectious complications in vascular surgery: limits to the use of rifampicin-bonded prosthetic grafts. *Angiology* 2010;**61**:423–6.
- 236 Wiltberger G, Matia I, Schmelzle M, Krenzien F, Hau HM, Freitas B, Jonas S, et al. Mid- and long-term results after replacement of infected peripheral vascular prosthetic grafts with biosynthetic collagen prosthesis. *J Cardiovasc Surg (Torino)* 2014;**55**:693–8 <https://www.ncbi.nlm.nih.gov/pubmed/24699511>.
- 237 McMillan WD, Leville CD, Hile CN. Bovine pericardial patch repair in infected fields. *J Vasc Surg* 2012;**55**:1712–5.
- 238 Brewer MB, Ochoa CJ, Woo K, Wartman SM, Nikolian V, Han S, et al. Sartorius muscle flaps for vascular groin wound complications. *Am Surg* 2015;**81**:1163–9.
- 239 Fischer JP, Mirzabeigi MN, Sieber BA, Nelson JA, Wu LC, Kovach SJ, et al. Outcome analysis of 244 consecutive flaps for managing complex groin wounds. *J Plast Reconstr Aesthet Surg* 2013;**66**:1396–404.
- 240 Schutzer R, Hingorani A, Ascher E, Markevich N, Kallakuri S, Jacob T. Early transposition of the sartorius muscle for exposed patent infrainguinal bypass grafts. *Vasc Endovascular Surg* 2005;**39**:159–62.
- 241 Tanaka C, Ide MR, Junior AJ. Anatomical contribution to the surgical construction of the sartorius muscle flap. *Surg Radiol Anat* 2006;**28**:277–83.
- 242 Töpel I, Betz T, Uhl C, Steinbauer MG. The impact of superficial femoral artery (SFA) occlusion on the outcome of proximal sartorius muscle transposition flaps in vascular surgery patients. *J Vasc Surg* 2011;**53**:1014–9.
- 243 Obeid T, Locham S, Arhuidese I, Nejim B, Aridi HD, Malas M. Sartorius muscle flaps: perioperative outcomes based on surgical speciality. *Ann Vasc Surg* 2017;**43**:226–31.

- 244 Mirzabeigi MN, Fischer JP, Basta MN, Fracol M, Kovach SJ, Wu LC, et al. Managing groin wounds after infrainguinal vascular procedures: examining the reoperative events and complication profile of muscle flap reconstruction. *Ann Vasc Surg* 2017;**43**:232–41.
- 245 Ali AT, Rueda M, Desikan S, Moursi MM, An R, Spencer H, et al. Outcomes after retroflexed gracilis muscle flap for vascular infections in the groin. *J Vasc Surg* 2016;**64**:452–7.
- 246 Dua A, Rothenberg KA, Lavingia K, Ho VT, Rao C, Desai SS. Outcomes of gracilis muscle flaps in the management of groin complications after arterial bypass with prosthetic graft. *Ann Vasc Surg* 2018;**51**:113–8.
- 247 LoGiudice JA, Haberman K, Sanger JR. The anterolateral thigh flap for groin and lower abdominal defects: a better alternative to the rectus abdominis flap. *Plast Reconstr Surg* 2014;**133**:162–8.
- 248 De Santis F, Chaves Brait CM, Caravelli G, Pompei S, Di Cintio V. Salvage of infected vascular graft via 'perivascular venous banding' technique coupled with rectus abdominis myocutaneous muscle flap transposition. *Vascular* 2013;**21**:17–22.
- 249 Stone PA, Armstrong PA, Bandyk DF, Brumberg RS, Flaherty SK, Back MR, et al. Use of antibiotic-loaded polymethylmethacrylate beads for the treatment of extracavity prosthetic vascular graft infections. *J Vasc Surg* 2006;**44**:757–61.
- 250 Poi MJ, Pisimisi G, Barshes NR, Darouiche RO, Lin PH, Koungias P, et al. Evaluating effectiveness of antibiotic polymethylmethacrylate beads in achieving wound sterilization and graft preservation in patients with early and late vascular graft infections. *Surgery* 2013;**153**:673–82.
- 251 Chalmers RT, Wolfe JH, Cheshire NJ, Stansby G, Nicolaidis AN, Mansfield AO, et al. Improved management of infrainguinal bypass graft infection with methicillin-resistant *Staphylococcus aureus*. *Br J Surg* 1999;**86**:1433–6.
- 252 Bath J, Rahimi M, Long B, Avgerinos E, Giglia J. Clinical outcomes of obturator canal bypass. *J Vasc Surg* 2017;**66**:160–6.
- 253 Busch A, Lorenz U, Tiurbe GC, Bühler C, Kellersmann R. Femoral vein obturator bypass revascularization in groin infectious bleeding: two case reports and review of the literature. *J Med Case Rep* 2013;**18**:75.
- 254 Sugawara Y, Sueda T, Orihashi K, Okada K, Wada H, Imai K, et al. Retro-sartorius bypass in the treatment of graft infection after peripheral vascular surgery. *J Vasc Surg* 2003;**37**:892–4.
- 255 Naraynsingh V, Karmody AM, Leather RP, Corson JD. Lateral approach to the profunda femoris artery. *Am J Surg* 1984;**147**:813–4.
- 256 Madden NJ, Calligaro KD, Dougherty MJ, Zheng H, Troutman DA. Lateral femoral bypass for prosthetic arterial graft infections in the groin. *J Vasc Surg* 2019;**69**:1129–36.
- 257 De Luccia N, Sasaki P, Durazzo A, Sandri G, Kikuchi M, Hirata C, et al. Limb salvage using bypass to the perigeniculate arteries. *Eur J Vasc Endovasc Surg* 2011;**42**:374–8.
- 258 Hoballah JJ, Chalmers RTA, Sharp WJ, Kresowik TF, Martinasevic MM, Corson JD. Lateral approach to the popliteal and crural vessels for limb salvage. *Cardiovasc Surg* 1996;**4**:165–8.
- 259 Calligaro KD, Veith FJ, Schwartz ML, Goldsmith J, Savarese RP, Dougherty MJ, et al. Selective preservation of infected prosthetic arterial grafts. Analysis of a 20-year experience with 120 extracavity-infected grafts. *Ann Surg* 1994;**220**:461–9.
- 260 Zetrenne E, Wirth GA, McIntosh BC, Evans GR, Narayan D. Managing extracavity prosthetic vascular graft infections: a pathway to success. *Ann Plast Surg* 2006;**57**:677–82.
- 261 Herrera FA, Kohanzadeh S, Nasserri Y, Kansal N, Owens EL, Bodor R. Management of vascular graft infections with soft tissue flap coverage: improving limb salvage rates – a veterans affairs experience. *Am Surg* 2009;**75**:877–81.
- 262 Sgroi MD, Kirkpatrick VE, Resnick KA, Williams RA, Wilson SE, Gordon IL. Less than total excision of infected prosthetic PTFE graft does not increase the risk of reinfection. *Vasc Endovasc Surg* 2015;**49**:12–5.
- 263 Shenouda M, Molena E, Maftai N, Ali T. Remnant prosthetic graft in revision or limb-salvage surgery: routine complete excision? *Ann Vasc Surg* 2014;**28**:1566.
- 264 Albers M, Romiti M, Pereira CA, Antonini M, Wulkan M. Meta-analysis of allograft bypass grafting to infrapopliteal arteries. *Eur J Vasc Endovasc Surg* 2004;**28**:462–72.
- 265 Nagpal A, Sohail MR. Prosthetic vascular graft infections: a contemporary approach to diagnosis and management. *Curr Infect Dis Rep* 2011;**13**:317–23.
- 266 Oberhuber A, Lohr B, Orend KH, Schelzig H, Muehling B. Outcome of infrainguinal prosthetic graft infections depending on surgical management. *Surg Infect* 2014;**15**:606–12.
- 267 Cardozo MA, Frankini AD, Bonamigo TP. Use of superficial femoral vein in the treatment of infected aortoiliac prosthetic grafts. *Cardiovasc Surg* 2002;**10**:304–10.
- 268 Daenens K, Fourneau I, Nevelsteen A. Ten-year experience in autogenous reconstruction with the femoral vein in the treatment of aortofemoral prosthetic infection. *Eur J Vasc Endovasc Surg* 2003;**25**(3):240–5.
- 269 Beck AW, Murphy EH, Hocking JA, Timaran CH, Arko FR, Clagett GP. Aortic reconstruction with femoral-popliteal vein: graft stenosis incidence, risk and reintervention. *J Vasc Surg* 2008;**47**:36–43.
- 270 Aavik A, Lieberg J, Kals J, Pulges A, Kals M, Lepner U. Ten years experience of treating aorto-femoral bypass graft infection with venous allografts. *Eur J Vasc Endovasc Surg* 2008;**36**:432–7.
- 271 Nevelsteen A, Feryn T, Lacroix H, Suy R, Goffin Y. Experience with cryopreserved arterial allografts in the treatment of prosthetic graft infections. *Cardiovasc Surg* 1998;**6**:378–83.
- 272 Vogt PR, Brunner-LaRocca HP, Lachat M, Ruef C, Turina MI. Technical details with the use of cryopreserved arterial allografts for aortic infection : influence on early and midterm mortality. *J Vasc Surg* 2002;**35**:80–6.
- 273 Noel AA, Gloviczki P, Cherry Jr KJ, Safi H, Goldstone J, Morasch MD, et al. Abdominal aortic reconstruction in infected fields: early results of the United States cryopreserved aortic allograft registry. *J Vasc Surg* 2002;**35**:847–52.
- 274 Schaeffers JF, Donas KP, Panuccio G, Kasprzak B, Heine B, Torsello GB, et al. Outcomes of surgical explantation off infected aortic grafts after endovascular abdominal aneurysm repair. *Eur J Vasc Endovasc Surg* 2019;**57**:130–6.
- 275 Batt M, Magne JL, Alric P, Muzj A, Ruotolo C, Ljungstrom KG, et al. In situ revascularization with silver-coated polyester grafts to treat aortic infection: early and midterm results. *J Vasc Surg* 2003;**38**:983–9.
- 276 Batt M, Jean-Baptiste E, O'Connor S, Bouillanne PJ, Haudebourg P, Hassen-Khodja R, et al. In-situ revascularisation for patients with aortic graft infection : a single centre experience with silver coated polyester grafts. *Eur J Vasc Endovasc Surg* 2008;**36**:182–8.
- 277 Pupka A, Skora J, Janczak D, Plonek T, Marczak J, Szydelko T. In situ revascularization with silver-coated polyester prostheses and arterial homografts in patients with aortic graft infection – a prospective, comparative, single-centre study. *Eur J Vasc Endovasc Surg* 2011;**41**:61–7.
- 278 Greenblatt DY, Rajamanickam V, Mell MW. Predictors of surgical site infection after open lower extremity revascularization. *J Vasc Surg* 2011;**54**:433–9.
- 279 Davis FM, Sutzko DC, Grey SF, Mansour MA, Jain KM, Nypaver TJ, et al. Predictors of surgical site infection after open lower extremity revascularization. *J Vasc Surg* 2017;**65**:1769–78.
- 280 Leekha S, Lahr BD, Thompson RL, Sampathkumar P, Duncan AA, Orenstein R. Preoperative risk prediction of surgical site infection requiring hospitalization or reoperation in patients undergoing vascular surgery. *J Vasc Surg* 2016;**64**:177–84.

**FURTHER READING**

- 281 Fukuchi K, Ishida Y, Higashi M, Tsunekawa T, Ogino H, Minatoya K, et al. Detection of aortic graft infection by fluorodeoxyglucose positron emission tomography : comparison with computed tomographic findings. *J Vasc Surg* 2005;**42**:919–25.
- 282 Khaja MS, Sildiroglu O, Hagspiel K, Rehm PK, Cherry KJ, Turba UC. Prosthetic vascular graft infection imaging. *Clin Imaging* 2013;**37**:239–44.
- 283 Erba PA, Leo G, Sollini M, Tascini C, Boni R, Berchilli RN, et al. Radiolabelled leucocyte scintigraphy versus conventional radiological imaging for the management of late, low-grade vascular prosthesis infections. *Eur J Nucl Med Mol Imaging* 2014;**41**:357–68.
- 284 Spacek M, Belohlavek O, Votrubova J, Sebesta P, Stadler P. Diagnostics of ‘non-acute’ vascular prosthesis infection usgin 18F-FDG PET/CT: our experience with 96 prostheses. *Eur J Nucl Med Mol Imaging* 2009;**36**:350–8.
- 285 Karaca S, Rager O, Ratib O, Kalangos A. Long-term results confirmed that 18F-FDG-PET/CT was an excellent diagnostic modality for early detection of vascular grafts infection. *Q J Nucl Med Mol Imaging* 2018;**62**:200–8.
- 286 Liberatore M, Iurilli AP, Ponzio F, Prospero D, Santini C, Baiocchi P, et al. Clinical usefulness of technetium-99m-HMPAO-labeled leukocyte scan in prosthetic vascular graft infection. *J Nucl Med* 1998;**39**:875–9.
- 287 Lou L, Alibhai KN, Winkelaar GB, Turnbull RG, Hoskinson ME, Warshawski R, et al. 99mTc-WBC scintigraphy with SPECT/CT in the evaluation of arterial graft infection. *Nucl Med Commun* 2010;**31**:411–6.