

## Editor's Choice — Management of Chronic Venous Disease

### *Clinical Practice Guidelines of the European Society for Vascular Surgery (ESVS)*

C. Wittens,<sup>a</sup> A.H. Davies,<sup>a</sup> N. Bækgaard,<sup>a</sup> R. Broholm,<sup>a</sup> A. Cavezzi,<sup>a</sup> S. Chastanet,<sup>a</sup>  
M. de Wolf,<sup>a</sup> C. Eggen,<sup>a</sup> A. Giannoukas,<sup>a</sup> M. Gohel,<sup>a</sup> S. Kakkos,<sup>a</sup> J. Lawson,<sup>a</sup> T. Noppeney,<sup>a</sup> S. Onida,<sup>a</sup> P. Pittaluga,<sup>a</sup>  
S. Thomis,<sup>a</sup> I. Toonder,<sup>a</sup> M. Vuylsteke,<sup>a</sup>  
ESVS Guidelines Committee<sup>b</sup> P. Kolh, G.J. de Borst, N. Chakfé, S. Debus, R. Hinchliffe, I. Koncar, J. Lindholt,  
M.V. de Ceniga, F. Vermassen, F. Verzini,  
Document Reviewers<sup>c</sup> M.G. De Maeseneer, L. Blomgren, O. Hartung, E. Kalodiki, E. Korten, M. Lugli,  
R. Naylor, P. Nicolini, A. Rosales

**Keywords:** Chronic venous disease, Venous disease, Varicose veins, CEAP, VCSS, Villalta, AVVQ, Vein QoL Sym, Duplex ultrasound, Plethysmography, Phlebography, MRV, CTV, Wound dressings, Compression, Ambulatory compression, Sclerotherapy, Thermal ablation, Non-thermal ablation, Laser, Radiofrequency ablation, Stripping, High ligation, Phlebectomy, Stenting, Endophlebectomy, AV fistula, Recurrent varicose veins, Venous malformation

#### TABLE OF CONTENTS

Abbreviations	680
Introduction	681
Chapter 1: General Considerations	682
1.1. History	682
1.1.1. Pathophysiology	682
1.1.2. Treatment	682
1.1.3. Development in the last 50 years	683
1.2. Epidemiology	683
1.2.1. Risk factors	683
1.2.1.1. Age	683
1.2.1.2. Gender	683
1.2.1.3. Obesity	683
1.2.1.4. Family history	683
1.2.1.5. Ethnicity	683
1.2.2. Prevalence of reflux	683
1.2.3. Progression of varicose veins	684
1.3. Anatomy	684
1.3.1. The superficial veins of the lower extremity	684
1.3.2. The deep veins of the lower extremity	684
1.4. Physiology	684
1.4.1. The relationship of capacitance/volume to pressure	685
1.4.2. The hydrostatic and dynamic pressure	685
1.4.3. The vein valves	685
1.4.4. The calf muscle and the foot pump	685
1.4.5. Venous tone	685
1.4.6. The venous pump: main transport system in the non-supine position	685

<sup>a</sup> **Writing Committee:** Cees Wittens (Netherlands), Chair; Alun Davies (United Kingdom), Co-Chair; Niels Bækgaard (Denmark); Rikke Broholm (Denmark); Attilio Cavezzi (Italy); Sylvain Chastanet (France); Mark de Wolf (Netherlands); Céline Eggen (Netherlands); Athanasios Giannoukas (Greece); Manjit Gohel (United Kingdom); Stavros Kakkos (Greece/United Kingdom); James Lawson (Netherlands); Thomas Noppeney (Germany); Sarah Onida (United Kingdom); Paul Pittaluga (France); Sarah Thomis (Belgium); Irwin Toonder (Netherlands); Marc Vuylsteke (Belgium).

<sup>b</sup> **ESVS Guidelines Committee:** Philippe Kolh (Chair) (Belgium), Gert Jan de Borst (Co-Chair) (Netherlands), Nabil Chakfé (France), Sebastian Debus (Germany), Rob Hinchliffe (United Kingdom), Igor Koncar (Serbia), Jes Lindholt (Denmark), Melina Vega de Ceniga (Spain), Frank Vermassen (Belgium), Fabio Verzini (Italy).

<sup>c</sup> **Document Reviewers:** Marianne De Maeseneer (Review Coordinator) (Belgium), Lena Blomgren (Sweden), Olivier Hartung (France), Evi Kalodiki (United Kingdom), Eunice Korten (Netherlands), Marzia Lugli (Italy), Ross Naylor (United Kingdom), Philippe Nicolini (France), Antonio Rosales (Norway). DOI of original article: <http://dx.doi.org/10.1016/j.ejvs.2015.02.014>

1078-5884/© 2015 European Society for Vascular Surgery. Published by Elsevier Ltd. All rights reserved.

<http://dx.doi.org/10.1016/j.ejvs.2015.02.007>

1.5.	Pathophysiology	685
1.5.1.	Venous reflux and obstruction	686
Chapter 2: Clinical Presentation of CVD		686
2.1.	Clinical presentations	686
2.2.	Classification of chronic venous disease	686
2.2.1.	Clinical Etiological Anatomical Pathophysiological (CEAP) classification	687
2.2.1.1.	Clinical classification: C0–C6	687
2.2.1.2.	Etiological classification: Ec, Ep, Es, En	687
2.2.1.3.	Anatomical classification: As, Ap, Ad, An	687
2.2.1.4.	Pathophysiological classification: Pr, Po, Pr/o, Pn	687
2.2.1.5.	Level of investigation	688
2.2.1.6.	Applying the CEAP	688
2.2.2.	Venous Clinical Severity Score, Venous Segmental Disease Score, and Venous Disability Score	688
2.2.2.1.	Venous Clinical Severity Score: measure of severity	688
2.2.2.2.	Venous Segmental Disease Score: pathophysiology and anatomy	688
2.2.2.3.	Venous Disability Score: functional impact	689
2.2.3.	Villalta-Prandoni Scale	689
2.3.	Quality of life measures in venous disease	689
2.3.1.	Health related generic tools	690
2.3.1.1.	SF-36, Medical Outcomes Study 36 Item Short Form	690
2.3.1.2.	EuroQoL, 5D	690
2.3.2.	Disease specific tools	690
2.3.2.1.	Aberdeen Varicose Veins Questionnaire	690
2.3.2.2.	Chronic Venous Insufficiency Questionnaire	691
2.3.2.3.	Venous Insufficiency Epidemiological and Economic study	691
Chapter 3: Diagnostics		691
3.1.	Clinical examination	691
3.1.1.	History	691
3.1.2.	Physical examination	692
3.2.	Diagnostic tools	692
3.2.1.	Definition of reflux	692
3.2.2.	Handheld continuous wave Doppler	693
3.2.3.	Duplex ultrasound examination	693
3.2.3.1.	Efficacy	693
3.2.3.2.	Technique	695
3.2.3.3.	Imaging recurrent disease	695
3.2.4.	Plethysmography and venous pressure measurements	695
3.2.4.1.	Strain-gauge plethysmography	695
3.2.4.2.	Photoplethysmography	695
3.2.4.3.	Air-plethysmography	696
3.2.4.4.	Foot volumetry	696
3.2.5.	Phlebography	696
3.2.6.	Other imaging methods	696
3.2.6.1.	Scientific evidence	696
Chapter 4: Treatment Options in Chronic Venous Disease		697
4.1.	Dressings for venous ulcers	697
4.2.	Compression therapy	698
4.2.1.	Chronic venous disease without ulceration (C0–C4)	698
4.2.2.	Venous ulceration (C5–C6)	698
4.2.2.1.	Venous ulcer healing	698
4.2.2.2.	Venous ulcer recurrence	699
4.2.3.	Intermittent pneumatic compression for venous ulceration	699
4.2.4.	Compression after venous intervention	699
4.3.	Physiotherapy, leg elevation, and leg massage	700
4.3.1.	Physiotherapy for leg ulceration	700
4.3.2.	Leg elevation	700
4.3.3.	Leg massage	701
4.4.	Medical treatment	701
4.4.1.	Chronic venous disease without ulceration (C0–C4)	701
4.4.2.	Venous ulceration (C5–C6)	702
4.5.	Sclerotherapy	702
4.6.	Transcutaneous laser	703
4.7.	Endovenous treatments	704
4.7.1.	Endovenous thermal ablation	704
4.7.1.1.	Great saphenous vein	704
4.7.1.2.	Small saphenous vein	706
4.7.2.	Mechanochemical endovenous ablation	706
4.8.	Surgery of the superficial veins	706
4.8.1.	High ligation with/without stripping	706
4.8.2.	Phlebectomy	708
4.8.3.	Ambulatory Selective Varices Ablation under Local anaesthesia	708

4.8.4.	Cure conservatrice et Hémodynamique de l'Insuffisance Veineuse en Ambulatoire (CHIVA)	709
4.8.5.	Powered phlebectomy	709
4.9.	Treatment of deep vein pathology	709
4.9.1.	Treatment of chronic deep venous obstruction	710
4.9.1.1.	Percutaneous transluminal angioplasty and stenting	710
4.9.1.2.	Open bypass procedures	711
4.9.2.	Treatment of deep venous incompetence	711
Chapter 5: Recurrent Varicose Veins		712
5.1.	Etiology	713
5.2.	Risk factors	714
5.3.	Diagnosis of recurrent varicose veins	714
5.4.	Treatment of recurrent varicose veins	714
Chapter 6: Congenital Venous Malformations		715
6.1.	Pathophysiology	715
6.2.	Classification	715
6.2.1.	International Society for the Study of Vascular Anomalies classification	715
6.2.2.	Hamburg classification	715
6.2.3.	Puig classification	715
6.3.	Venous malformations	715
6.4.	Syndromes	717
6.4.1.	Klippel-Trenaunay syndrome	717
6.4.1.1.	Etiology	717
6.4.1.2.	Clinical characteristics	718
6.4.1.3.	Diagnosis	718
6.4.1.4.	Management	718
6.4.2.	Parkes-Weber syndrome	719
6.4.2.1.	Etiology	719
6.4.2.2.	Clinical characteristics	719
6.4.2.3.	Diagnosis	719
6.4.2.4.	Management	719
References		721

## ABBREVIATIONS

AASV	Anterior Accessory Saphenous Vein
AC	AntiCoagulation
AP	Ambulatory Phlebectomy
APG	Air-PlethysmoGraphy
ASVAL	Ambulatory Selective Varices Ablation under Local anaesthesia
AVMs	ArterioVenous Malformations
AVP	Ambulatory Venous Pressure
AVVQ	Aberdeen Varicose Veins Questionnaire
BMI	Body Mass Index
CEAP	Clinical Etiologic Anatomic Pathophysiological
CHIVA	Conservatrice et Hémodynamique de l'Insuffisance Veineuse en Ambulatoire
CIVIQ	Chronic Venous Insufficiency Questionnaire
CT	Computed Tomography
CTV	Computed Tomography Venography
CVD	Chronic Venous Disease
CVI	Chronic Venous Insufficiency
CVMs	Congenital Vascular Malformations
CW	Continuous Wave
DUS	Duplex UltraSound
DVT	Deep Venous Thrombosis
EBM	Evidence Based Medicine
ESVS	European Society for Vascular Surgery
EVLA	EndoVenous Laser Ablation
EVTA	EndoVenous Thermal Ablation
GSV	Great Saphenous Vein
GWC	Guideline Writing Committee
HCSE	Horse CheStnut Extract

HL	High Ligation
HL/S	High Ligation/Stripping
IPC	Intermittent Pneumatic Compression
ISSVA	International Society for the Study of Vascular Anomalies
IVC	Inferior Vena Cava
IVUS	IntraVascular UltraSound
KTS	Klippel-Trenaunay Syndrome
LMWH	Low Molecular Weight Heparin
MOCA	Mechanochemical ablation
MPFF	Micronized Purified Flavonoid Fraction
MR	Magnetic Resonance
MRV	Magnetic Resonance Venography
NIVL	Non-thrombotic Iliac Vein Lesions
OR	Odds Ratio
PASV	Posterior Accessory Saphenous Vein
PTA	Percutaneous Transluminal Angioplasty
PTS	Post Thrombotic Syndrome
PWS	Parkes-Weber Syndrome
QALYs	Quality-Adjusted Life Years
QoL	Quality of Life
RCT(s)	Randomized Controlled Trial(s)
REVAS	REcurrent Varices After Surgery
RFA	RadioFrequency Ablation
SEPS	Subfascial Endoscopic Perforator Surgery
SFJ	SaphenoFemoral Junction
SPJ	SaphenoPopliteal Junction
SSV	Small Saphenous Vein
STS	Sodium Tetradecyl Sulphate
TCL	TransCutaneous Laser

TIPP	Transilluminated Powered Phlebectomy
UGFS	Ultrasound Guided Foam Sclerotherapy
VCSS	Venous Clinical Severity Score
VDS	Venous Disability Score

VEINES	Venous Insufficiency Epidemiological and Economic Study
VMs	Venous Malformations
VSDS	Venous Segmental Disease Score

## INTRODUCTION

Members of this Guideline Writing Committee (GWC) were selected by the European Society for Vascular Surgery (ESVS) to represent physicians involved in management of patients with chronic venous disease (CVD). The members of the GWC have provided disclosure statements of all relationships that might be perceived as real or potential sources of conflicts of interest. These disclosure forms are kept on file at the headquarters of the ESVS. The GWC report received neither financial support nor support from the ESVS or any pharmaceutical, device, or surgical industry.

The ESVS guideline committee was responsible for the endorsement process of this guideline. All experts involved in the GWC have approved the final document. The guideline document was reviewed and approved by the EJVES editorial board and ESVS guideline committee.

## THE PURPOSE OF THESE GUIDELINES

The ESVS has developed clinical practice guidelines for the care of patients with CVD in the lower extremities.

The aim of this document is to assist physicians in selecting the best management strategy for patients with CVD. This guideline, established by members of the GWC, who are members of the ESVS or non-members with specific expertise in the field, is based on scientific evidence completed with expert opinion on the matter. By summarizing and evaluating all available evidence in the field, recommendations for the evaluation and treatment of patients with CVD have been formulated.

Guidelines have the purpose of promoting a standard of care according to specialists in the field, in this case represented by members of the ESVS. However, under no circumstance should this guideline be seen as the legal standard of care in all patients. As the word guideline states in itself, the document is a guiding principle, but the care given to a single patient is always dependent on the individual patient (symptom variability, comorbidities, age, level of activity, etc.), treatment setting (techniques available), and other factors.

The recommendations are valid only at the time of publication, as technology and disease knowledge in this field changes rapidly and expanding recommendations can become outdated. It is an aim of the ESVS to revise the guidelines when important new insights in the evaluation and management of CVD become available.

## METHODOLOGY

### Strategy

The GWC was convened in 2011 at the annual ESVS meeting in Athens. At that meeting the tasks in creating the guideline were evaluated and distributed among the committee members. The final version of the guideline was submitted on December 22, 2014.

### Literature search and selection

A clinical librarian performed the literature search for this guideline systematically in PubMed, Embase, Cinahl, and the Cochrane Library up to January 1, 2013. Reference checking and handsearch by the guideline committee members added other relevant literature.

The members of the GWC performed the literature selection based on information provided in the title and abstract of the retrieved studies.

Criteria for search and selection were:

<u>Language:</u>	English, German, and French
<u>Level of evidence:</u>	Selection of the literature was performed following the pyramid of evidence, with aggregated evidence in the top of the pyramid (systematic reviews, meta-analysis), then randomized controlled trials, then observational studies. Single case reports, animal studies, and in vitro studies in the bottom of the pyramid were excluded, leaving expert opinions at the bottom of the pyramid. The level of evidence per section in the guideline is dependent on the level of evidence available on the specific subject.
<u>Sample size:</u>	If there were large studies available, with a minimum of 15 subjects per research group, only these were included. If not available, smaller studies were also included.

Several relevant articles published after the search date or in another foreign language were included, but only if they were of paramount importance to this guideline.

### Weighing the evidence

To define the current guidelines, members of the GWC reviewed and summarized the selected literature. Conclusions were drawn based on the scientific evidence.

The guidelines in this document are based on the European Society of Cardiology grading system. For each recommendation, the letter A, B, or C marks the level of

**Table 1.** Levels of evidence.

Level of evidence A	Data derived from multiple randomized clinical trials or meta-analyses.
Level of evidence B	Data derived from a single randomized clinical trial or large non-randomized studies.
Level of evidence C	Consensus of opinion of the experts and/or small studies, retrospective studies, registries.

**Table 2.** Classes of recommendations.

Classes of recommendations	Definition
Class I	Evidence and/or general agreement that a given treatment or procedure is beneficial, useful, effective.
Class II	Conflicting evidence and/or a divergence of opinion about the usefulness/efficacy of the given treatment or procedure.
Class IIa	<i>Weight of evidence/opinion is in favour of usefulness/efficacy.</i>
Class IIb	<i>Usefulness/efficacy is less well established by evidence/opinion.</i>
Class III	Evidence or general agreement that the given treatment or procedure is not useful/effective, and in some cases may be harmful.

current evidence (Table 1). Weighing the level of evidence and expert opinion, every recommendation is subsequently marked as either class I, IIa, IIb, or III (Table 2). The lower the class number, the more proven is the efficacy and safety of a certain procedure.

## CHAPTER 1: GENERAL CONSIDERATIONS

The term CVD has been used to describe both visual and functional manifestations of abnormalities in the peripheral venous system. It can be defined as “(any) morphological and functional abnormalities of the venous system of long duration manifest either by symptoms and/or signs indicating the need for investigation and/or care.”<sup>1</sup>

The prevalence of CVD in the adult population has been reported to be as high as 60%, particularly affecting populations in the developed world.<sup>2,3</sup> It has become clear that CVD is an important cause of patient distress and significantly impacts on healthcare resources.<sup>4,5</sup>

Although a complete understanding of the pathophysiology of CVD remains elusive, chronic venous hypertension is widely accepted as the predominant cause of advanced venous skin changes and ulceration. A sound understanding of the disease process and its clinical presentations is paramount in assessment and management of the patient with CVD.

### 1.1. History

#### 1.1.1. Pathophysiology

In ancient times, venous problems were described occasionally. Hippocrates (460–377 before Christ) stated that an upright position was inappropriate for a leg with ulceration, assumingly not knowing the real background at that time. In 1544, a Spanish anatomist, Vassaseus, gave a description of venous valves and their function.<sup>6</sup> At the beginning of the seventeenth century, Harvey published his contribution to the understanding of the physiology of the venous circulation, and Malpighi demonstrated the existence of capillaries and thereby clarified the final connection in the circulatory system.<sup>7</sup> At the same time, Brodie described symptoms and signs of chronic venous insufficiency (CVI).<sup>8</sup> In 1670, Lower described venous return as a result of the arterial propagating pulsation (“vis a tergo”), and also described the muscle pump.<sup>7</sup> The pressure changes caused by thoracoabdominal respiration, enhancing the venous return — “vis a fronte” — to the heart, were described in 1710 by Valsalva.<sup>7</sup>

In 1891, the classical test was invented to differentiate between superficial and deep reflux/retrograde flow by Trendelenburg, and 5 years later a test to verify patency of the deep veins was proposed by Perthes, both tests using compression of the limb.<sup>7</sup> Homans pointed out that ulceration was different in behaviour dependent on whether it was a result of superficial or deep disease.<sup>9</sup> Linton introduced the concept of ambulatory venous hypertension as the fundamental pathophysiological theory for terminal and distinct CVD.<sup>10</sup>

#### 1.1.2. Treatment

Hippocrates recommended puncture of varicose veins followed by compression.<sup>8</sup> Four-hundred years later, Celsus performed an avulsion technique with hooks of varicose veins. The French surgeon Pravaz has been given credit for the design of the syringe and needle technique for vascular injection in 1831, and later Pétrequin introduced the method of sclerotherapy for varicose veins. After unsatisfactory results by Smith in 1939, the technique was discredited for many years.<sup>11</sup> In 1944, Orbach introduced the so called “air-block” technique to avoid dilution of the injected sclerosant and, at the same time, create close contact with the endothelium, which indeed was a step forward and also a precursor towards foam sclerotherapy.<sup>12</sup> Trendelenburg proposed great saphenous vein (GSV) ligation at mid-thigh in 1891 as being a step to control distal varicosities.<sup>13</sup> The most used methods have been the external stripping by Mayo and the Babcock method with the intraluminal technique, both at the beginning of the twentieth century, and later pin-stripping by Oesch in 1963.<sup>14</sup> Muller revisited the accompanying hook phlebectomy in 1956 through minimal incisions.<sup>15</sup>

Elastic stockings were invented in 1930 as a result of the personal experience of Jobst, an engineer, who himself suffered from a venous ulceration. While bathing in his pool, he noticed that his symptoms were less pronounced, coming to the conclusion that the increasing depth of the water was the secret of the “healing” component. Thus, graduated compression stockings were invented.<sup>16</sup>

### 1.1.3. Development in the last 50 years

Bypass procedures were popularized as the May-Husni operation at the femoral level,<sup>17</sup> and the Palma operation for iliac occlusion.<sup>18</sup> Gloviczki presented experimental work on abdominal bypass surgery with prosthetic grafts and arteriovenous fistulae some years later.<sup>19</sup> Eklöf suggested the benefit of using an arteriovenous fistula after iliac thrombectomy.<sup>20</sup> At the same time, the pioneers Kistner and Raju performed valve reconstructions and valve transfer.<sup>21,22</sup> Hauer introduced subfascial endoscopic perforator surgery (SEPS) in 1985.<sup>23</sup> Balloon dilatation and implantation of stents in the venous system was published for the first time in 1991 by Okrent using ballooning and in 1994 by Semba, who used the more durable stenting technique. Both procedures were used as additional treatments to catheter directed thrombolysis at the ilio-femoral level.<sup>24,25</sup> Stenting of iliac obstruction in patients with CVI was popularized by Néglen in 2000 in a large scale study.<sup>26</sup>

The endovenous procedures for varicose veins were developed in the 1990s as thermal, chemical, and mechanochemical vein ablation for truncal varicose disease but were based on the initial work of electro puncture and cauterizations of varicose veins dating back to the 1960s.

## 1.2. Epidemiology

Clinical reporting, usually indicated as the C of the CEAP classification (from C0 to C6, see further 2.2.1) makes it possible to report prevalence numbers for each clinical class as well as progression rates through the clinical classes over time and relationship to gender, age, obesity, and other risk factors. The prevalences of CVD differ according to these risk factors. The newest and most comprehensive epidemiologic studies from this century will be presented here. Telangiectasiae (also known as spider veins) (C1) have been reported to affect up to 80% of the population.<sup>2</sup> Varicose veins (C2) are also extremely common, with a variable reported incidence ranging from 20% to 64%.<sup>2,27–29</sup> The more advanced stages of venous disease, CVI (C3–C6), appear to affect about 5% of the population, with the prevalence of the end stages of CVI (active and healed venous ulcers, C5+C6) estimated at 1–2%.<sup>30</sup>

### 1.2.1. Risk factors

**1.2.1.1. Age.** Several studies have revealed older age as the most important risk factor for varicose veins and CVI. In the San Diego study, older age showed a significant odds ratio (OR) up to 2.42 for varicose veins and up to 4.85 for CVI.<sup>31</sup> In the Bonn Vein study, the most important risk factor for varicose veins and CVI was older age (OR in the age 70–79 years were 15.9 for varicose veins and 23.3 for CVI).<sup>32</sup>

**1.2.1.2. Gender.** C2 disease is more common in female adults than male adults: 13.9–46.3% females and 11.4–29.3% males based on 50,974 persons with most between 16 and 90 years in the five classical studies from Europe and the USA.<sup>31–35</sup> In the same studies, C3 varied from 4.5% to 13.6% and the prevalence of C4–C6 varied from 3.6% to 12%.<sup>31–33,35</sup> A similar prevalence of C2 was found in women who had never been pregnant, and in men.<sup>36</sup> In the same studies, the influence of gender on C0–C1 is inconclusive.

However, it has to be mentioned that in the Edinburgh Vein study, varicose veins (C2) were more common among male subjects in the general population.<sup>29</sup>

The incidence of varicose veins per year is 2.6% in women and 1.9% in men.<sup>37</sup> The gender influence diminishes with age.<sup>38</sup> No obvious gender difference is shown concerning CVI.<sup>32,34,35</sup>

Oral hormone replacement and contraceptives do not increase the risk of varicose veins.<sup>32,39</sup> The number of pregnancies increased the OR from 1.3 to 2.2 for development of varicose veins.<sup>32</sup> Another recent large scale study could not demonstrate change in GSV reflux following pregnancies.<sup>40</sup>

Half of the general population in the Bonn Vein study reported venous symptoms, 49.1% of the males and 62.1% of the females, and the prevalence increased with age.<sup>41</sup> Symptoms were more frequently reported in limbs with deep venous involvement compared with superficial, and were also more frequent in women.<sup>31</sup>

In a recent global collection of prospective epidemiologic data on chronic venous disorder in 91,545 subjects including areas outside Europe and the USA, almost the same observations were made, but on a larger scale. Symptomatic C0 was more frequent in men and C2–C3 more frequent in women, but C4–C6 did not differ between men and women.<sup>27</sup>

**1.2.1.3. Obesity.** A body mass index (BMI) greater than 30 increases the risk for CVI significantly, with ORs for men and women of 6.5 and 3.1, respectively.<sup>41</sup> Another study found a positive correlation between a BMI of more than 30 and varicose veins (OR 5.8) in postmenopausal women.<sup>42</sup> Other authors found an association between severe obesity (BMI 40 or more) and increasing limb symptoms without anatomic evidence of venous disease, suggesting that the obesity itself contributed to the venous insufficiency.<sup>43</sup> Similar findings were published in a larger scale investigation with a threshold of BMI of 25.<sup>44</sup>

**1.2.1.4. Family history.** Many studies have shown a correlation between a positive family history for varicose veins or venous disease and the risk of varicose veins.<sup>32</sup> A cohort study revealed that a family history of hospital treatment for varicose veins was associated with an increased risk of similar treatment among relatives.<sup>45</sup> Responsible genetic disturbances have not been found to explain the obvious heredity. Genome-wide association studies should be considered to further unravel the genetic basis of venous disease.<sup>46</sup>

**1.2.1.5. Ethnicity.** For many years, prevalence studies have been based on figures and numbers from the western world. Data from Europe, Latin America, the Middle East, and the Far East are now available in the large scale Vein Consult Program with 91,545 subjects over 18 years of age. C1–C6 involved 63.9% of the subjects. The incidence of C2 was significantly lower in the Middle East, whereas C1 was significantly higher. C5 and C6 were unequally distributed in the regions.<sup>27</sup>

### 1.2.2. Prevalence of reflux

In the Edinburgh Vein study with 1,566 subjects, the aim was to correlate venous reflux with clinical features. Reflux was defined as reversed flow longer than 0.5 seconds. No reflux was found in 36.5% of the patients. One third of the

subjects had incompetence limited to the superficial system. The frequency of reflux in both superficial and deep segments increased with the clinical severity of disease. CVI increased with age. Symptoms were strongly related to the severity of CVI.<sup>47</sup> Pattern of reflux has also been examined in the Bonn Vein study with 3,072 subjects.<sup>48</sup> Pathological reflux was defined as longer than 0.5 seconds. The prevalence of superficial reflux was significantly higher in women, whereas deep venous reflux was significantly higher in men. Both types correlated with progression in C stages, but only superficial reflux showed a marked increase with age.<sup>48</sup>

### 1.2.3. Progression of varicose veins

The prevalence of C6 disease varies from 0.1 to 0.5%.<sup>32,33</sup> However, this does not reveal the rate of progression from lower to higher C classes. A study including 116 limbs with varicose veins used a second duplex scan a median 19 months after the initial examination in the period waiting for surgery. Approximately one-third of the patients had progression, and in 95% of the patients the changes were noted after 6 months or more.<sup>49</sup> In the large scale Bonn Vein study, the progression rate from varicose veins to CVI was 4% per year.<sup>50</sup>

## 1.3. Anatomy

### 1.3.1. The superficial veins of the lower extremity

The full length of the GSV is covered by a connective tissue lamina called the “saphenous fascia,” and typically lies in the saphenous compartment.<sup>51</sup> On B-mode ultrasound it resembles an “Egyptian eye” in transverse scan with the saphenous fascia easily being identified.<sup>52</sup> In the GSV compartment there is usually only one truncal vein. Very rarely (in 1% of patients) the GSV is duplicated, which means two veins are situated in the same saphenous compartment.<sup>53</sup>

A few millimetres distal to the saphenofemoral junction (SFJ), the GSV has a terminal valve, and a few centimetres distal to that valve there is often another valve, called the pre-terminal valve.<sup>54,55</sup> Important tributaries (i.e. superficial circumflex iliac, superficial epigastric, and superficial external pudendal veins) join the GSV between these valves. The anterior accessory saphenous vein (AASV) and the posterior accessory saphenous vein (PASV) are frequently present and run parallel to the GSV in the thigh in their own saphenous compartment.

The SSV ascends upwards on the posterior aspect of the calf between the two heads of the gastrocnemius muscle. In the popliteal fossa, the main trunk of the SSV frequently drains into the popliteal vein. Often, a cranial extension of the SSV, called the “thigh extension,” continues upwards and uncommonly the SSV does not drain into the popliteal fossa but instead continues cranially and eventually empties into the femoral vein or the GSV. Veins connecting the GSV and SSV are called “intersaphenous veins.” A particular intersaphenous vein is the Giacomini vein running from the SSV in the popliteal fossa to the GSV.<sup>55</sup> The SSV lies in its own saphenous compartment, delineated by the superficial fascia and the muscular fascia.<sup>56,57</sup>

Perforating veins are variable in arrangement and distribution, and are numerous (more than 100 in each limb). The medial perforating veins are most significant but their role in CVI and venous ulcers is not well defined.<sup>58–61</sup>

### 1.3.2. The deep veins of the lower extremity

Venous blood from the foot drains through the deep plantar venous arch, which at the medial malleolus becomes the posterior tibial veins.<sup>62</sup> On the dorsum of the foot the deep dorsal digital veins drain into the dorsal metatarsal veins. The dorsalis pedis vein located on the dorsum of the foot becomes the anterior tibial veins at the ankle. The tibioperoneal trunk and the anterior tibial veins join and form the popliteal vein in the popliteal fossa.

The main tributaries of the popliteal vein are the gastrocnemius veins, the tibial veins, and the SSV, although the gastrocnemius veins may join the SSV before joining the popliteal vein. The saphenopopliteal junction (SPJ) is often located within 5 cm of the popliteal skin crease, but this level varies.

The popliteal vein continues in a cephalad direction, and ascends in the adductor canal becoming the femoral vein (the previously used term “superficial femoral vein” has been abandoned).<sup>63</sup> Approximately 10 cm below the inguinal ligament, the femoral vein joins with the deep femoral vein to form the common femoral vein. The common femoral vein is situated medially to the corresponding artery and it ends at the inguinal ligament. The vein receives the GSV at the SFJ. Both the popliteal and the femoral vein may be duplicated in segments of various lengths.<sup>64,65</sup> Above the inguinal ligament the common femoral vein continues as the external iliac vein, and at the junction of the internal and external iliac veins anterior to the sacroiliac joint they form the common iliac vein.

As well as the superficial veins, the deep veins contain valves. The frequency of valves increases from the more proximal veins to the more distal. The calf veins contain numerous valves, whereas the femoral and popliteal veins have only one or two valves.<sup>66,67</sup> Additional valves are seen, however, in the femoral vein near the junction with the deep femoral vein. The common femoral vein usually contains only one valve. Cranial to the SFJ, there is only one or no valve. In the common iliac vein, valves are practically absent or rudimentary, and valves are absent in the inferior vena cava (IVC).<sup>66</sup>

## 1.4. Physiology

The venous circulation is a low pressure, low velocity, large volume, low resistance vascular system. The primary function of the venous system is to return blood to the heart. Venous return is influenced by the interaction between a central pump (the heart), pressure gradients, the peripheral venous pump, and competent valves in patent veins. In an upright position these factors work together to overcome the hydrostatic pressure induced by gravity, which is quite different in the supine position. Furthermore, the system is characterized by its capacitance, which allows pronounced fluid variations. Finally, the system has an impact on the regulation of body temperature.

In steady state, the venous return equals the cardiac output. The venous system contains at least 60% of total resting blood volume, with half of this being in the post-capillary venules in the lower extremity. About 25% resides in the splanchnic circulation.<sup>68,69</sup>

#### 1.4.1. The relationship of capacitance/volume to pressure

Variations in venous blood volume of up to 10–20% are tolerated.<sup>68,70</sup> A simple shift from a supine to an upright position can be responsible for a 10% volume change in the lower extremity.<sup>69</sup> An increase in capacitance is normal late in the day after standing or sitting, and almost 20% of normal volunteers will demonstrate valvular dysfunction.<sup>71</sup>

The system has a unique function based on the vein compliance. To maintain an acceptable low positive pressure of 5 mmHg, the veins become flaccid, and the pressure can even be negative with minimal volume. In contrast, a considerable increase in volume will result in only a relatively modest change in pressure. A change in vein shape from elliptic to circular indicates high volume and high pressure. In other words: over a normal pressure range of 5–25 mmHg, volume can change remarkably without affecting either flow or pressure.<sup>70</sup>

#### 1.4.2. The hydrostatic and dynamic pressure

In the non-supine situation, gravity exercises a hydrostatic influence on the venous system. The hydrostatic pressure at a given anatomical point is determined by measuring the vertical distance between the heart and the point of interest.<sup>72</sup> In the upright position, the hydrostatic pressure, measured in a dorsal foot vein, is determined by the blood column between the right atrium and the foot. For example in a person 175 cm tall, the venous pressure at the foot may reach approximately 95 mmHg, with the pressure at the groin being 30–35 mmHg, dependent on the anthropometric shape of the body.

The dynamic pressure is basically caused by propagation of arterial pulsation from the pumping heart. Through pre-capillary arterial vasoconstriction - among other factors - most of the dynamic pressure is decreased, resulting in a pressure of 12–18 mmHg in the venous side of the capillary. The atrial pressure of 4–7 mmHg causes the resulting dynamic pressure gradient to facilitate return of blood to the heart in the supine position. The respiratory influence is positive for venous return. Inspiration creates a negative pressure in the thoracic cavity, creating a kind of “suction” of blood, while increased abdominal pressure during inspiration reduces flow in the abdomen. During expiration the opposite flow pattern is seen. This mechanism is mostly seen in the supine position.<sup>73</sup>

#### 1.4.3. The vein valves

The valves divide the column of blood into segments and prevent retrograde flow.<sup>74</sup> The greater number of valves in the infrapopliteal segment suggests their greater functional importance at this level.<sup>75</sup> A normal valve can resist a pressure above 300 mmHg, but reflux will occur at a higher pressure. In patients with superficial or deep vein valvular incompetence reflux develops at a much lower pressure because of valve disease and/or vein dilatation.<sup>73</sup> In the presence of normal valve function the blood is conducted from the superficial

veins to the deep veins through the perforating system. An exception is the perforating veins in the foot, where bidirectional flow is normal.<sup>75</sup> One study has described the valves creating jet streams in the venous system.<sup>76</sup> This flow pattern is later described as helical, especially at venous junctions.<sup>77</sup>

#### 1.4.4. The calf muscle and the foot pump

These pumps act together during walking. Intramuscular pressure can increase up to 200–300 mmHg, creating a pressure three times higher in the muscle veins than in the superficial veins, thus creating a pressure gradient cranially and from the calf.<sup>78</sup> During relaxation the blood is directed from the superficial veins to the deep veins, with the lowest pressure at this stage. The foot pump is quite different in function with elongation of the plantar veins during walking, thus squeezing the blood antegradely.<sup>79</sup> The compression of the plantar venous plexus during walking is a primer of the calf pump.<sup>62</sup> Half of the blood can be ejected upwards in one single contraction.<sup>80,81</sup> The contribution of thigh muscle contraction is minimal compared with the above mentioned pumps.<sup>81</sup>

#### 1.4.5. Venous tone

Venous tone is managed by the muscle layer in the vein wall. Several mechanisms, such as sympathetic-adrenergic nerve activity, circulating vasoactive substances, and local metabolites will stimulate it.<sup>73</sup>

#### 1.4.6. The venous pump: main transport system in the non-supine position

In an upright position venous return is still influenced by the dynamic effect from the heart. The increase in hydrostatic pressure is the same in both the arteries and veins. Fortunately the potent veno-arterial reflex, activated by the venous dilatation, involves an arteriolar constriction restricting the arterial blood flow by 50%.<sup>73,82</sup> Even in a so called relaxed standing position there will be muscle contractions, which will diminish the capillary pressure distally in the extremity. With use of the muscle pumps and the valves, together called the venous pump, the pressure distally will be decreased to approximately 30 mmHg during walking or tiptoe/heel raising manoeuvres. This pressure is called the ambulatory venous pressure (AVP), which can be monitored through a needle in a foot vein. Measuring AVP is potentially meaningful. It has been shown that no ulceration was observed in limbs with AVP less than 30 mmHg, but there was 100% incidence with AVP above 90 mmHg.<sup>83</sup>

### 1.5. Pathophysiology

The pathophysiology of CVD is characterized by reflux, obstruction, or a combination of both. This results in reduced ability to empty the leg veins efficiently during exercise, which means the AVP remains high and this eventually leads to all the clinical features of venous hypertension. Apart from reflux and obstruction, other underlying factors may compromise adequate venous emptying, such as failure of the calf and foot muscle pump (decreased mobility of the ankle joint and other neuromuscular problems).<sup>80,83,84</sup> Whereas most patients with uncomplicated varicose veins (C2) still have normal venous



pressures during ambulation, all those with more advanced stages of CVD progressively develop venous hypertension, characterized by symptoms and signs of CVI (C3–C6). The clinical manifestations of CVI are oedema and skin changes, from hyperpigmentation, eczema, atrophie blanche and lipodermatosclerosis to venous ulcers.

Deep vein valve incompetence will result in minor or no reduction in AVP, and venous obstruction will even elevate the pressure during calf contractions, both representing ambulatory venous hypertension.<sup>85,86</sup> Outflow obstruction at ilio-femoral level with or without valvular incompetence in the femoral and/or popliteal vein can lead to venous claudication described as a “bursting” pain while walking, only relieved by rest or even better by elevation. In multi-level post-thrombotic obstruction, the iliac vein lesions are the key pathology as infrainguinal obstructions are better tolerated because of adequate collateralization.<sup>87</sup> The pathophysiological combination of reflux and obstruction is significantly more common in patients with venous ulceration than in those with less advanced stages of CVD.<sup>88</sup>

### 1.5.1. Venous reflux and obstruction

In incompetent superficial veins, reflux is primarily caused by vein wall abnormalities.<sup>89,90</sup> Varicose veins contain an increased amount of collagen and decreased number of smooth muscle cells and elastin leading to disorganization of muscle components, disruption of elastic fibres, and fibrosis.<sup>91–93</sup> The weakness of the vein wall results in dilatation and enlargement of the valve ring, making the valve unable to work sufficiently, with reflux as the consequence.<sup>94</sup> The reflux can be axial or segmental. For many years, it has been accepted that this process starts cranially, mainly at the level of the SFJ or SPJ, and from there extends to the main trunks and further to the superficial tributaries. This is the so called “descending” pathophysiological theory. More recent research has proposed a rather multifocal origin of varicose veins, which states that, first, tributaries become dilated and incompetent, and only thereafter the main trunks, and eventually the junctions. This corresponds with the “ascending” theory of varicose vein development.<sup>95</sup>

The pathology in the deep veins is more complex. Acute obstruction occurs in the case of deep vein thrombosis. This is not discussed further in the present guideline. Chronic obstruction, resulting in increase of resistance to blood flow, is mainly caused by post-thrombotic changes consisting of stenosis, occlusion, intraluminal synechia, and increased rigidity of the vein wall, or any combination of these abnormalities.<sup>96</sup> Valves may be damaged and collaterals will develop at any place parallel to a deep obstruction, and even these can be incompetent. Chronic deep venous incompetence occurs in 80% of cases because of post-thrombotic valvular changes, and in 20% because of primary valvular incompetence.<sup>75</sup>

Ilio-femoral venous occlusion is less likely to recanalize compared with other venous segments. Almost two thirds will remain more or less obstructed with variable collateralization.<sup>97</sup> Obstruction in combination with reflux occurs in 55% of symptomatic patients.<sup>97,98</sup> In patients with ulceration, the cause is distributed almost equally between superficial and

deep venous incompetence.<sup>99</sup> Perforator incompetence has proven to be a significant factor in the determination of CVD severity.<sup>100</sup>

## CHAPTER 2: CLINICAL PRESENTATION OF CVD

### 2.1. Clinical presentation

The symptoms of CVD are extremely variable and cause significant morbidity to patients, negatively impacting on quality of life (QoL).<sup>101,102</sup> Self reported symptoms are worse in women.<sup>5,35</sup> Patients present with heaviness, tiredness, itching of the skin, nocturnal cramps, and throbbing and aching of the legs, which is exacerbated by prolonged standing.<sup>16</sup> These symptoms can interfere with day to day activities and work, particularly in patients who need to stand for prolonged periods of time. Symptoms are worse at the end of the day, and symptomatic relief may be achieved by leg elevation, mobilization, and exercise.

In patients with chronic outflow obstruction, venous claudication may typically occur during walking or climbing stairs.

Superficial veins can thrombose, resulting in painful thrombophlebitis and localized cellulitis. Deep venous thrombosis, particularly if found in the ilio-femoral segment, may lead to the development of venous claudication, a bursting pain affecting the buttocks, thighs, or legs when walking, requiring rest and leg elevation to achieve symptomatic relief.

Uncommonly, bleeding can be a presentation of CVD. This is commonly associated with a traumatized superficial varicosity, but significant bleeding can also arise from an area of ulceration. The resulting blood loss may be profound and even life threatening.<sup>103</sup>

Studies have demonstrated that clinical signs correlate with patterns of venous reflux as identified by duplex ultrasound (DUS) examination. This is true for the superficial venous system (including both great and small saphenous)<sup>104</sup> and the deep venous system.<sup>47</sup> There is evidence suggesting that clinical signs of disease also correlate with GSV vein diameter, with increasing diameter being associated with greater disease severity.<sup>105</sup>

QoL scores also correlate with disease severity. Patients with more severe signs and symptoms report worse QoL scores.<sup>106</sup>

Clinical recurrence of varicose veins may present in a similar fashion to primary superficial venous disease. A multicentre study was performed to assess the presence of recurrence in patients who had undergone previous varicose vein surgery.<sup>107</sup> Following the CEAP classification,<sup>123</sup> the vast majority had recurrence associated with oedema (C3) (70.9%), while 29.1% had skin changes (C4). Varicose veins were present in 24.6% (C2), in 43% two clinical classes were present, and in 24% four classes were present. There was a mixture of C0–C6 classes, from reticular veins and telangiectasiae, to varicose veins, oedema, hyperpigmentation, and ulceration.

### 2.2. Classification of chronic venous disease

The diverse nature of presenting signs and symptoms of patients with CVD means that objective classification of disease severity presents a significant challenge.

Classification of CVD may be performed using clinical, anatomical, haemodynamic, or patient reported criteria. A comprehensive classification system would ideally take into consideration all of these factors.

Dramatic variations and inconsistencies in the assessment of disease severity have made it difficult to interpret and compare published reports in the literature. The challenge of inconsistent reporting and the recognition that there was a need for a uniform, applicable and standardized classification system for venous disease, was the main motivation for the development of classifications, particularly the CEAP classification.

### 2.2.1. Clinical Etiological Anatomical Pathophysiological (CEAP) classification

The CEAP classification was published in 1994 by an international ad hoc committee of the American Venous Forum and endorsed by the Society for Vascular Surgery.<sup>108</sup> Following the meeting, it was published in 26 journals and books and in nine languages, making it a truly universal document in the field of CVD. It was revised in 2004 and is a widely endorsed classification system for clinical papers reporting on CVD (Table 3).<sup>109</sup>

The CEAP classification system was developed to take into account not only clinical (C) aspects of venous disease, but also etiological (E), anatomical (A), and pathophysiological (P) components, enabling a more comprehensive assessment of the severity of venous disease. The CEAP classification system has largely replaced the previous severity tools, allowing a standardized approach to the signs and symptoms of CVD and enabling correlation between different studies and reports. Nonetheless, CEAP has been

**Table 3.** CEAP Classification.

#### C: Clinical Classification

- C0: no visible or palpable signs of venous disease
- C1: telangiectasia or reticular veins
- C2: varicose veins
- C3: oedema
- C4a: hyperpigmentation or eczema
- C4b: lipodermatosclerosis or atrophie blanche
- C5: healed venous ulcer
- C6: active venous ulcer

s: symptomatic, including ache, pain, tightness, skin irritation, heaviness, muscle cramps

a: asymptomatic

#### E: Etiological Classification

- Ec: congenital
- Ep: primary (undeterminate cause)
- Es: secondary (e.g. post thrombotic)
- En: no venous cause identified

#### A: Anatomical Classification

- As: superficial veins
- Ap: perforator veins
- Ad: deep veins
- An: no venous location identified

#### P: Pathophysiological Classification

- Pr: reflux
- Po: obstruction
- Pr,o: reflux and obstruction
- Pn: no venous pathophysiology identifiable

reported as having moderate inter-observer reproducibility when deciding medical indication for treatment.<sup>110</sup>

**2.2.1.1. Clinical classification: C0–C6.** Clinical signs form the basis of the clinical component of CEAP, which is scored from 0 (no evidence of venous disease) to 6 (active ulceration). Although increasing C classification is generally considered to represent increasing disease severity, this should not be considered a linear progression or severity score. Unlike the Widmer and Porter classifications, the CEAP classification allows more detail to be recorded. Symptoms of CVD, including aching, pain, tightness, skin irritation, heaviness, and muscle cramps are denoted by the letter S in subscript, for example C2<sub>S</sub> (symptomatic) or C2<sub>A</sub> (asymptomatic). Even if skin changes have occurred, a patient may be asymptomatic, for example C5<sub>A</sub>.

**2.2.1.2. Etiological classification: Ec, Ep, Es, En.** Assessment and management of CVD varies depending on the underlying etiological process. The CEAP classification recognizes and records three different causative factors: congenital (Ec), primary (Ep), and secondary or post-thrombotic (Es). In cases where no etiology is found, (En) is used.

Congenital factors are present from birth, and are related to disorders in the development of the venous system. Klippel-Trenaunay syndrome (KTS), Parkes-Weber syndrome (PWS), and vascular malformations are examples of congenital anomalies.

Primary venous disease commonly results in superficial venous incompetence, particularly located at the connecting points between deep and superficial veins, SFJ, SPJ, or perforating veins. Incompetence (or reflux) of the superficial venous system may result in venous hypertension and the development of signs and symptoms of CVD.

Secondary venous disease usually occurs as a result of previous deep venous thrombosis, although trauma and intra-abdominal masses may also result in impaired venous drainage and the development of CVD.

**2.2.1.3. Anatomical classification: As, Ap, Ad, An.** The anatomical classification allows accurate description of the location of venous disease. The classification recognizes superficial (As), perforating (Ap), and deep (Ad) venous systems as the site of venous incompetence.

This can be inferred with the aid of clinical tests and the handheld Doppler probe, but determined much more reliably with DUS examination. Where examination cannot identify the location of venous incompetence, the patient is classified as (An). Superficial disease may affect either the great or small saphenous systems. Clinical examination and DUS imaging can provide detailed information to enable targeted assessment and management planning.

**2.2.1.4. Pathophysiological classification: Pr, Po, Pr/o, Pn.** The pathophysiological mechanism for CVD has been defined as reflux (Pr), obstruction (Po), both (Pr/o), or not identified (Pn). In the advanced CEAP classification, the venous system has been described as 18 named (and numbered) venous segments, which could be included in the classification to provide a detailed description of CVD in each leg, in an individual patient. Although the detailed elaboration in the advanced CEAP may seem unnecessarily complex or

intimidating, it is the only classification to provide a widely accepted and understandable description of all aspects of CVD.

**2.2.1.5. Level of investigation.** The diagnostic evaluation of venous disease can be classified as<sup>111</sup>:

- Level 1: history and examination, with or without handheld Doppler assessment
- Level 2: non-invasive imaging with colour venous duplex and plethysmography, if available
- Level 3: invasive or complex imaging, including venography, computerized tomography, or MR imaging.

**2.2.1.6. Applying the CEAP.** The CEAP classification is widely accepted as the best available (and most widely used) classification system, and should be used by investigators reporting on CVD.<sup>112</sup> It is important to realize that this is a measure that can be repeated to classify changes in patient's clinical presentation. It should be initialized at the first patient encounter and revised on follow up. Many of the limitations of CEAP have been addressed during revisions, resulting in updated terminology and amended definitions.<sup>109</sup> However, there are aspects that are not taken into account by this classification system, including mixed arterial/venous disease, venous neuropathy, venous claudication, corona phlebectatica, and obesity.<sup>16</sup> Furthermore, it has been acknowledged that CEAP cannot be used as a reliable technique to rationalize patient treatment.<sup>113,114</sup> Nevertheless, the CEAP classification is currently the most commonly used assessment tool for venous disease.<sup>105,106</sup>

### 2.2.2. Venous Clinical Severity Score, Venous Segmental Disease Score, and Venous Disability Score

Although the CEAP classification provides a descriptive classification tool for patients with CVD, there have been criticisms that it lacks responsiveness in the long term and with repeated evaluation of patients. Three other clinical

tools have been described to address some of these criticisms.

#### 2.2.2.1. Venous Clinical Severity Score: measure of severity.

The Venous Clinical Severity Score (VCSS) was developed to supplement (rather than replace) the CEAP classification. VCSS offers a broad quantification of the severity of venous disease and is not a detailed descriptive tool for CVD in an individual patient. It takes into account the disease severity, and the degree to which patients are affected by it (Table 4). A total of 10 clinical characteristics are evaluated by a healthcare worker and graded from absent (score 0) to severe (score 3), with a total of 30 points attributable. It was developed to assess the progression of CVD and also to give additional weight to more severe clinical disease (C4–C6).<sup>115,116</sup>

The VCSS provides a more accurate measure of the severity of disease and the effect on the patients' day to day activities. Although it is used as a severity score, it has also been found to be a useful screening tool because of its correlation with severity on imaging.<sup>117,118</sup> It has been used and evaluated in different studies, and appears to be appropriate for measuring changes after surgery, although it may not be appropriate in studies investigating the use of stockings, as the scoring system takes this into account.<sup>119</sup>

The VCSS has been employed minus the stocking component (VCSS-S) for example, in the assessment of mechanical suppression of angiogenesis in varicose vein surgery.<sup>120</sup>

#### 2.2.2.2. Venous Segmental Disease Score: pathophysiology and anatomy.

The Venous Segmental Disease Score (VSDS) takes into account the anatomical and pathophysiological mechanisms involved in the presentation of CVD (Table 5).<sup>115,121</sup> VSDS accounts for anatomical location and nature (reflux or obstruction) of venous disease, providing a global assessment of pathophysiological disease severity. It relies on duplex scan assessment of the superficial and deep venous systems and provides a score out of 10 for reflux or obstruction. Although the pathophysiology and abnormal

**Table 4.** Venous Clinical Severity Score (VCSS).

Attribute	Absent (0)	Mild (1)	Moderate (2)	Severe (3)
Pain or other discomfort (ie aching, heaviness, fatigue, soreness, burning Presumes venous origin)	None	Occasional	Daily, interfering with, but not preventing regular daily activities	Daily limiting most regular daily activities
Varicose Veins	None	Few, scattered Also includes corona phlebectatica	Confined to calf <u>or</u> thigh	Involve calf <u>and</u> thigh
Venous oedema (presumes venous origin)	None	Limited to foot or ankle	Extends above ankle but below knee	Extends to knee or above
Skin Pigmentation	None or focal	Limited to perimalleolar area	Diffuse over lower third of calf	Wider distribution (above lower third of calf)
Inflammation	None	Limited to perimalleolar area	Diffuse over lower third of calf	Wider distribution (above lower third of calf)
Induration	None	Limited to perimalleolar area	Involving lower third of calf	Involving more than lower third of calf
Number of active ulcers	None	1	2	>2
Active ulcer duration	None	<3 months	>3 months but <1 year	>1year
Active ulcer size	None	Diameter <2 cm	Diameter 2–6 cm	Diameter >6 cm
Compression Therapy	Not used	Intermittent use of stockings	Uses stockings most days	Full compliance with stockings

**Table 5.** Venous Segmental Disease Score (VSDS).

Reflux		Obstruction	
½	Small saphenous		
1	Great saphenous	1	Great saphenous (if thrombosed from groin to below knee)
½	Thigh perforators		
1	Calf perforators		
2	Calf veins, multiple (Posterior Tibial only = 1)	1	Calf veins, multiple
2	Popliteal vein	2	Popliteal vein
1	Femoral vein	1	Femoral vein
1	Profunda femoris vein	1	Profunda femoris vein
1	Common femoral vein and above	2	Common femoral vein
		1	Iliac vein
		1	Inferior Vena Cava
10	Maximum reflux score	10	Maximum obstruction score

venous segments can be described accurately using the advanced CEAP classification, VSDS attributes different scores to different venous segments to indicate the level of overall impact on venous function.

Reflux describes all valves in a specific segment as incompetent. Obstruction describes a total occlusion at a point in the investigated segment or a >50% stenosis in at least half the segment. Importantly, traumatic obstruction, ligation, or excision of deep venous segments count as thrombosis. However, the same is not true for superficial veins. Perforator interruption and saphenous ligation/ablation count as a reduction of the reflux score, not as an obstruction score.

VSDS was found to correlate with clinical scores, with the magnitude of reflux correlating with symptom severity.<sup>119</sup>

**2.2.2.3. Venous Disability Score: functional impact.** The Venous Disability Score (VDS) provides a simple measure of the functional impact of CVD, using a 4 point scale (0–3; Table 6).<sup>115</sup> This evaluates the effect of CVD on daily activities. VDS has been validated against the CEAP as a measure of disease severity, and has been used as a

measure of change following venous surgery.<sup>119</sup> As with VCSS, VDS is designed to complement the CEAP classification by providing greater detail on the level of disability experienced by the patient.

**2.2.3. Villalta-Prandoni Scale**

The Villalta-Prandoni Scale was described in the 1990s to classify the severity of post-thrombotic syndrome (PTS), a complication of deep venous thrombosis.<sup>122</sup> Essentially, the scale consists of five symptoms (patient rated) and six physical signs (clinician rated), with each of the 11 factors scored out of 3 (total score out of 33; Table 7). A score of >14, or the presence of venous ulceration, indicates severe PTS.

The Villalta-Prandoni Scale is specific to the post-thrombotic limb and is a reliable, valid measure of PTS in patients with confirmed deep venous thrombosis (DVT).<sup>123</sup> It also correlates well with patient perceived health burden and QoL scores. A drawback of this scale is that it does not take into account venous claudication or venous ulcer severity, as the presence of a venous ulcer is given a fixed score irrespective of severity.

Recommendation 1	Class	Level	References
Use of the Clinical Etiological Anatomical Pathophysiological (CEAP) classification is recommended as a standardized, descriptive classification tool to assess disease severity in patients with chronic venous disease for research and audit.	I	B	108, 109, 112
<b>Recommendation 2</b>			
Use of one or more of the following scoring systems should be considered for chronic venous disease: Venous Clinical Severity Score to assess clinical severity, Venous Segmental Disease Score for pathophysiological and anatomical evaluation, Venous Disability Score for functional evaluation, and the Villalta-Prandoni Scale to assess severity of post-thrombotic syndrome.	Ila	B	115, 119, 122, 123

**Table 6.** Venous Disability Score (VDS).

- 0 – Asymptomatic
  - 1 – Symptomatic but able to carry out usual activities without compressive therapy
  - 2 – Able to carry out usual activities only with compression and/or limb elevation
  - 3 – Unable to carry out usual activities even with compression and/or limb elevation
- Usual activities: defined as patient activities before the onset of disability from venous disease

**2.3. Quality of life measures in venous disease**

The burden of CVD lies with the patients, with up to 30% displaying symptoms suggestive of a depressive illness.<sup>124</sup> Assessment of QoL in patients with CVD is integral to a complete and thorough evaluation of their disease status. Evidence shows that increasing clinical severity correlates strongly with deterioration in QoL measures, both general and disease specific.<sup>113</sup> Similarly, clinical improvement correlates with progression in QoL measures.<sup>125</sup> Clinical classification systems

**Table 7.** Villalta-Prandoni Scale.

[severity scoring: *none (0), mild (1), moderate (2), severe (3)*]. Each sign/symptom is scored 0–3; scores are added to obtain the final result (maximum of 33).

5 Venous symptoms	- Pain - Cramping - Heaviness - Pruritus - Paraesthesia
6 Clinical signs	- Oedema - Induration - Hyperpigmentation - Venous ectasia - Redness - Calf tenderness
Severity of post thrombotic syndrome (PTS)	- No PTS <5 - Mild PTS 5-9 - Moderate PTS 10-14 - Severe PTS >14 or venous ulceration - Total points range 0–33

are in place to assess the severity of CVD. QoL tools are available to assess patient reported outcomes. The ideal QoL tool should be generally applicable to any disease process, irrespective of severity, outcome measures, or geographic location.<sup>16</sup> The tool should be valid (i.e. measure what is intended), reliable (i.e. provide the same measurements for a single individual despite different conditions), and responsive (i.e. sensitive to assess change e.g. after treatment). Ideally, it should also assess all aspects of QoL, including physical, mental and social wellbeing. A number of global QoL instruments exist; however, they lack sensitivity to changing clinical conditions. Health related measures are used instead. A large number of tools have been developed and are in widespread use. There have been greater efforts to standardize the use of QoL assessments in recent years.

Generic and disease specific instruments measuring health related QoL in patients with CVD are discussed below.

### 2.3.1. Health related generic tools

**2.3.1.1. SF-36, Medical Outcomes Study 36 Item Short Form.** The SF-36 form is a widely used, generic QoL assessment tool with both physical and mental domains, providing a global assessment of patient wellbeing (Table 8).<sup>126</sup> The physical component of this patient completed questionnaire has been shown to correlate with venous disease severity. Studies have shown that all sub-domains of the physical component (*physical role, pain, physical functioning, and general health perception*) correlate significantly with disease severity as measured by the CEAP classification. This is not true for the mental component, as correlations with vitality<sup>127</sup> and mental health<sup>128</sup> are weak and inconsistent.

**Table 8.** SF-36.

- Physical function	Physical component
- Role physical	
- Bodily pain	
- General health	
- Mental health	Mental component
- Role emotional	
- Social function	
- Vitality	

**2.3.1.2. EuroQoL, 5D.** The EuroQoL group is a multinational, multicentre, and multidisciplinary network of researchers dedicated to the measurement of health status. The EuroQoL questionnaire was devised in the 1990s with the aim of developing a standardized, simple, and generic measure of health for clinical and economic appraisal.<sup>129</sup> It consists of a descriptive part, evaluating five dimensions (EuroQoL – 5D), and a vertical, visual analogue scale (VAS), recording the respondent's self-rated health (EuroQoL – VAS).

Together, the EuroQoL, 5D and EuroQoL-VAS, provide a comprehensive measure of health state. This tool is particularly useful for measuring utility or quality-adjusted life years (QALYs; a measure of disease burden), and has been used as a QoL measure in the assessment of patients with symptomatic varicose veins (Table 9).<sup>124</sup>

### 2.3.2. Disease specific tools

**2.3.2.1. Aberdeen Varicose Veins Questionnaire.** The Aberdeen Varicose Veins Questionnaire (AVVQ), is a patient completed QoL assessment tool comprising 13 questions with domains including physical symptoms, social effect, and cosmesis (Table 10).<sup>130</sup> Each question is graded in

**Table 9.** EuroQoL – 5D.

1. Mobility	- No problems - Some problems - Bed bound
2. Self care	- No problems - Some problems washing or dressing - Unable to wash or dress
3. Usual activities	- No problems - Some problems - Unable to perform
4. Pain/discomfort	- None - Moderate - Extreme
5. Anxiety/depression	- None - Moderately - Extremely

Euro – QoL VAS  
Perceived health

Visual analogue scale  
0 (worst state)–100 (best state)

terms of severity/presence or absence, and the results are collated into the Aberdeen Varicose Veins Symptom Severity Score from 0 to 100, where the higher the score, the worse the QoL.

The AVVQ has been validated as a measure of health outcome in patients with varicose veins against the SF-36 questionnaire.<sup>131</sup> It was found to be reliable, with significant association with patient symptoms. Many consider the responsiveness and sensitivity of the AVVQ to be greater than generic QoL questionnaires. However, generic QoL tools allow simpler calculation of health utility (QALYs), which is a necessity for meaningful health economy comparisons.

**2.3.2.2. Chronic Venous Insufficiency Questionnaire.** Developed in 1996 in France, the Chronic Venous Insufficiency Questionnaire (CIVIQ) is a 20-item self reporting QoL tool covering four dimensions: physical, psychological, social functioning, and pain (Table 11).<sup>132</sup> The items are graded on a 5 point Likert scale.<sup>133</sup> The questionnaire has been vali-

consistency, reliability, and value in assessing changes in QoL after treatment.<sup>136</sup>

**2.3.2.3. Venous Insufficiency Epidemiological and Economic study.** The Venous Insufficiency Epidemiological and Economic study (VEINES) was an international, prospective cohort study evaluating the epidemiology and outcomes of CVD.<sup>137</sup> As part of this project, a validated venous disease specific QoL and symptom measure was developed (VEINES QoL/Sym; Table 12).<sup>138</sup> The aim of this tool was to provide an assessment of QoL and symptoms across the range of conditions in CVD (including telangiectasia, varicose veins, oedema, skin changes, and leg ulcers). Psychometric testing revealed the questionnaire to be acceptable, reliable, and valid in four different language versions, as well as demonstrating correlation with both SF-36 and C class. The VEINES QoL/Sym was also found to be reliable and valid as a measure of QoL and symptoms in patients with acute DVT.<sup>139</sup>

Recommendation 3	Class	Level	References
Use of both generic and disease specific assessment tools should be considered to provide a complete evaluation of a patient with chronic venous disease.	IIa	B	124, 127, 128, 130, 131, 136, 139
<b>Recommendation 4</b>			
Disease severity and burden of disease should be reliably assessed by generic tools in the form of the physical component of the SF-36 and the EuroQoL-5D, respectively.	IIa	B	127-130
<b>Recommendation 5</b>			
The use of disease specific tools in the form of the Aberdeen Varicose Veins Questionnaire, Chronic Venous Insufficiency Questionnaire, or Venous Insufficiency Epidemiological and Economic study questionnaire should be considered to assess responsiveness to treatment.	IIa	B	131, 135-137, 139

dated in its French version, as well as in a number of other languages.<sup>134,135</sup>

In 2010 psychometric validation was carried out, revalidating the questionnaire and providing evidence for its

**Table 10.** AVVQ.

1. Distribution of veins
2. Duration of pain
3. Duration of analgesia
4. Degree of ankle swelling
5. Use of support stockings
6. Extent of itching
7. Presence of discolouration
8. Presence of rash or eczema
9. Presence of skin ulcer
10. Degree of concern at appearance
11. Influence on choice of clothes
12. Interference with work/household jobs
13. Interference with leisure

(score 0–100; 0 best, 100 worst)

## CHAPTER 3: DIAGNOSTICS

### Introduction

This chapter describes the value of available diagnostic tools used in patients with CVD. It describes the physical examination and additional tests including continuous wave [CW] Doppler, duplex ultrasound [DUS], phlebography, plethysmography, venous pressure measurement, and modern imaging techniques such as magnetic resonance venography [MRV] and computed tomography venography [CTV], as well as describing clinical and radiological diagnostic criteria of recurrent disease.

In the diagnostic work up the nature of the problem and the severity of the disease should be determined.

### 3.1. Clinical examination

#### 3.1.1. History

**Scientific evidence.** Patients with varicose veins and/or signs of CVD should be asked, prior to any clinical or

diagnostic investigation, about symptoms suggestive of venous pathology.<sup>140</sup> This applies also to patients with recurrent varicose veins following intervention, who may present with characteristic symptoms of CVD. Possible thromboembolic antecedents should be investigated, together with any allergy, medication (oral contraceptives primarily), and concomitant relevant diseases including heart and renal failure, which may influence CVD.<sup>140</sup> Finally, the number and timing of pregnancies should be noted.<sup>141</sup>

A differential diagnosis is very important. Even in the presence of trunk varices, many lower limb symptoms could have a non-venous cause.<sup>5,142</sup>

examined.<sup>146</sup> Distinctions were made between the iliac veins, the femoro-popliteal axis, deep veins in the calf, and superficial and perforating veins. Both normal subjects and patients with known CVD were studied and compared, including the differences between supine and upright examination by DUS.

When the duration of retrograde flow in patients with CVD was compared with healthy subjects, there was a significant ( $p < .0001$ ) difference for all segments in the affected leg. The cut off values defining venous incompetence (reflux) during ultrasound examination are set at retrograde flow longer than 0.5 s in the superficial venous

Recommendation 6	Class	Level	References
History taking from the patient with chronic venous disease is recommended before further investigation, targeting especially specific symptoms, any thromboembolic antecedent and relevant drug intake.	I	C	5, 140, 142

### 3.1.2. Physical examination

**Scientific evidence.** Patients with CVD are examined in a physiological upright standing position. Both legs should be examined completely. When signs of severe CVD or secondary (e.g. post-thrombotic) varices are present, the abdominal region should be inspected for the possible presence of venous collaterals. Venous collaterals on the lower abdomen, flanks, and pubic region are pathognomonic of iliac or ilio-caval outflow obstruction.

Corona phlebectatica paraplantaris should be noted as this may indicate advanced venous stasis.<sup>143</sup>

In recurrent disease, it is important to bear in mind the patient's pre-operative state and assess any amelioration or worsening in signs such as skin changes or ulceration.

During physical examination, it is important to consider alternative pathology such as signs of arterial insufficiency, orthopaedic, rheumatological, or neurological pathology (muscle pump function). The main circumferences of both legs should be measured when indicated (e.g. phlebolymphedema, suspicion of vascular malformations).

Traditional clinical tests such as Trendelenburg, Perthes, and others have proven unreliable and have no place in the mapping of venous incompetence in general, and of varicose veins in particular.<sup>144,145</sup>

## 3.2. Diagnostic tools

### 3.2.1. Definition of reflux

**Scientific evidence.** In a study using DUS, reflux times in the various venous segments of the lower extremity were

system, the deep femoral vein, and the calf veins, longer than 1 s in the common femoral, femoral vein, and popliteal vein, and longer than 0.35 s in perforating veins.<sup>146</sup>

An additional finding of this study is that an erect position is the only reliable way to detect reflux.<sup>146</sup>

Previous international consensus held 0.5 s as a cut off value in all leg vein segments, but this appears to vary with the type of venous segment. The present consensus recommends 1 s as the cut off duration for reflux in femoral and popliteal vein, whereas above 0.5 s is considered reflux in saphenous veins, lower leg veins, and perforators.<sup>146</sup>

The GSV, AASV, PASV, thigh extension, and SSV all situated in their saphenous compartment, are the main superficial conduits to be imaged for morphology and tested for possible reflux, and its segmental distribution.<sup>147</sup> Main thigh or lower leg perforators, mostly on the medial aspect of the limb, should be examined with diameters measured at fascia level. Perforators should also be tested for their inward and/or outward flow during distal calf compression (systole) and release (diastole).<sup>147</sup> Saphenous diameter should be measured at specific locations: the GSV 3 cm below the saphenofemoral junction, at mid-thigh, at the knee, and lower leg; the AASV 3 cm below the SFJ and at mid-thigh when still lying in its saphenous compartment; and the SSV 3 cm below the SPJ.<sup>148</sup> The terminal and pre-terminal valves of GSV must be tested for their function, as Cappelli demonstrated that GSV

Recommendation 7	Class	Level	References
Physical examination of patients should always be performed, looking for varicose veins, oedema, and skin changes.	I	C	140,142
<b>Recommendation 8</b>			
The traditional diagnostic tests Trendelenburg, Perthes, and other such tests are not recommended in the work up of patients with chronic venous disease.	III	B	144,145

**Table 11.** CIVIQ – 20.

*In the past four weeks, to what extent did your leg problems interfere with.../cause you...*

Physical Items	<ol style="list-style-type: none"> <li>1. Climbing stairs</li> <li>2. Crouching/Kneeling</li> <li>3. Walking briskly</li> <li>4. Doing the housework</li> </ol>
Psychological Items	<ol style="list-style-type: none"> <li>1. Feeling on edge</li> <li>2. Becoming tired easily</li> <li>3. Feeling like a burden to people</li> <li>4. Needing to take precautions</li> <li>5. Embarrassment to show one’s legs</li> <li>6. Being easily irritable</li> <li>7. Feeling handicapped</li> <li>8. Having difficulty getting going in the morning</li> <li>9. Not feeling like going out</li> </ol>
Social items	<ol style="list-style-type: none"> <li>1. Going out in the evening</li> <li>2. Practicing a sport</li> <li>3. Travelling by car/bus/plane</li> </ol>
Pain items	<ol style="list-style-type: none"> <li>1. Pain in the ankles or legs</li> <li>2. Interference with work or daily activities</li> <li>3. Interference with sleeping</li> <li>4. Interference with standing for a long time</li> </ol>

diameter at proximal thigh is strictly related to the presence or absence of reflux at the terminal valve and at the iliac-femoral valve.<sup>149,150</sup>

Assessment of venous reflux and of perforators is largely based on DUS. Limitations diminish for the abdominal and or pelvic veins. Antegrade flow and reflux are elicited through the creation of a pressure gradient, with specific manoeuvres (e.g. Valsalva manoeuvre and compression/release manoeuvre). Patency of the main deep veins of the

lower limbs (common femoral vein, femoral vein, popliteal vein, gastrocnemius veins, peroneal and tibial veins) should be highlighted, especially when detection of deep vein thrombosis or its sequelae (post-thrombotic syndrome) is required.

**3.2.2. Handheld continuous wave Doppler**

**Scientific evidence.** Doppler examination is a non-invasive procedure using ultrasound information to determine venous flow. CW Doppler provides no information on venous morphology, therefore it is unsuitable for the determination of any anatomical component of any venous disease. Reliability of CW Doppler examination in detecting obstruction/reflux in deep veins is extremely low in abdominal and lower leg veins. Research has shown that pre-operative planning on the basis of CW Doppler alone, instead of DUS, results in inadequate treatment in a significant proportion of patients.<sup>151</sup> In a study of 40 patients it was found that DUS is much more reliable than both physical examination and CW Doppler, with little difference in reliability between the last two.<sup>152</sup>

**3.2.3. Duplex ultrasound examination**

**3.2.3.1. Efficacy. Scientific evidence.** DUS examination is based on a combination of ultrasound imaging and pulsed wave Doppler with which information can be obtained on both the anatomy and the hemodynamic features of the venous system. Additional colour flow imaging is routinely employed to quicken and improve DUS accuracy.

Anatomy, valvular incompetence, and venous obstruction can be easily detected using DUS.<sup>153–157</sup> With DUS it is also possible to investigate the deep venous system in most segments with adequate accuracy.<sup>158</sup> In addition to good reproducibility, the non-invasive nature of duplex scanning is a great asset. With the development of this technique, invasive tests such as phlebography have been reserved for a few selective indications (see 3.2.5), as well as making former non-invasive devices such as handheld Doppler obsolete. DUS examination should be considered as the gold standard in the diagnosis of CVD.

However, DUS investigation has a lower reliability to elicit patency, obstruction, or occlusion of deep veins in the lower leg, whereas a higher accuracy has been reported in the

Recommendation 9	Class	Level	References
To define venous incompetence the following cut off values are recommended: retrograde flow lasting more than 0.5 s in the superficial venous system, the deep femoral vein, and the calf veins, more than 1 s in the common femoral vein, the femoral vein, and the popliteal vein, and more than 0.35 s in perforating veins.	I	B	<sup>146</sup>

Recommendation 10	Class	Level	References
Continuous wave Doppler is not recommended for the diagnostic work up of chronic venous disease.	III	B	<sup>151, 152</sup>



**Table 12.** VEINES QoL/Sym.

During the last 4 weeks how often did you have:

- |                              |                        |
|------------------------------|------------------------|
| 1. Heavy legs                | - Every day            |
| 2. Aching legs               | - Several times a week |
| 3. Swelling                  | - Once a week          |
| 4. Night cramps              | - <Once a week         |
| 5. Heat or burning sensation | - Never                |
| 6. Restless legs             |                        |
| 7. Throbbing                 |                        |
| 8. Itching                   |                        |
| 9. Tingling sensation        |                        |

At what time of day is the problem most intense?

- On walking
- At midday
- At the end of the day
- During the night
- At any time of day
- Never

Compared to one year ago, how would you rate your leg problem now?

- Much better
- Somewhat better
- About the same
- Somewhat worse
- Much worse
- I did not have a problem last year

Does your leg problem limit you in the following activities?

- |   |                      |
|---|----------------------|
| 1. Daily activities at work             | - I do not work      |
| 2. Daily activities at home (housework) | - Yes, a lot         |
| 3. Standing for long periods            | - Yes, a little      |
| 4. Sitting for long periods             | - Not limited at all |

During the past 4 weeks, have you had any of the following at work/during your day as a result of your leg problem?

- Yes
- No

1. Cut down the amount of time you spent at work/doing activities
2. Accomplished less than you would like
3. Limited in the kind of work or other activities
4. Difficulty performing the work or other activities

During the past 4 weeks, to what extent has your leg problem interfered with your normal social activities with family, friends, neighbours or groups?

- Not at all
- Slightly
- Moderately
- Quite a bit
- Extremely

How much leg pain have you had during the past 4 weeks?

- None
- Very mild
- Mild
- Moderate
- Severe
- Very severe

How have you felt over the past 4 weeks as a result of your leg problem?

Table 12-continued

- |  |                          |
|--|--------------------------|
| 1. Concern about the appearance of your leg(s)?                          | - All of the time        |
| 2. Irritable?  | - Most of the time       |
| 3. Burden to your family or friends?                                     | - A good bit of the time |
| 4. Worried about bumping into things?                                    | - Some of the time       |
| 5. Has the appearance of your leg(s) influenced your choice of clothing? | - A little of the time   |
|  | - None of the time       |

femoro-popliteal segment.<sup>159,160</sup> Transvaginal DUS evaluation of pelvic veins is not yet fully defined.<sup>161,162</sup>

Additional colour flow imaging resulted in facilitation of the overall approach to the insonated segment to assess patency and competence. In the post-thrombotic syndrome, DUS identifies residual obstruction, persistent occlusion, and valvular incompetence in the affected segments, with greater accuracy in the infrainguinal areas. Phlebography or MRV/CTV have a definite role in the diagnostic work up of the veins in the abdominal/pelvic area.

With the introduction of duplex ultrasound, other non-invasive techniques such as Doppler and plethysmography (except certain parameters of air-plethysmography) have lost most of their value, and are no longer used in the routine evaluation of CVD.

DUS is an ideal tool for follow up. DUS performed 1 year after surgery focusing on detection of neovascularization, has a high accuracy in predicting recurrence at the SFJ after 5 years.<sup>163</sup> DUS is also used in the pre-operative assessment of patients undergoing surgery, as recommended by the clinical practice guidelines of the Society for Vascular Surgery and the American Venous Forum.<sup>140</sup>

**3.2.3.2. Technique.** The extent of DUS depends on the symptoms. In severe CVD, after a deep vein thrombosis or persistent or rapidly recurrent varicosities, it is important to fully scan the deep system including the iliac tract. With primary varicose veins it is sufficient to scan below the groin in most cases. When pelvic vein incompetence and/or obstruction is suspected, complementary scanning in the pelvic area is recommended. Alternative methods (e.g. CTV, MRV, and especially phlebography) are to be used for a more complete diagnosis and for planning possible treatment.

The five major components that define a complete DUS examination are: anatomical information, flow visualization (presence or absence of reflux), provocation manoeuvres for flow augmentation, morphology (patency or obliteration), and compressibility (thrombosis diagnosis).

Standardized DUS examination to determine reflux in superficial and perforating veins must be performed with the patient in a physiological standing position with external rotation of the examined limb in a relaxed position, while supporting the weight on the contralateral limb. Investigation of patency of iliac and patency and incompetence of common femoral veins should be performed with the patient in supine position, whereas femoral and popliteal vein segments should be investigated with the patient standing

as for competence, although patency also can be elicited in supine and prone position, respectively.<sup>147</sup> Lower leg deep veins should be examined with relaxed calf muscles.

High frequency broadband linear transducers are generally used to investigate the lower limbs, whereas low frequency broadband curved array transducers are used when investigating deeper veins (e.g. obese patients, abdominal veins). An appropriate transducer for transvaginal ultrasound may be used in case of suspected pelvic vein incompetence. An adequate pulse repetition frequency setting is required to detect low velocities (5–10 cm/s) and/or reflux.<sup>147</sup>

**3.2.3.3. Imaging recurrent disease.** Recurrent disease can be reliably assessed by DUS. DUS can provide the necessary anatomical and functional information about the nature of recurrence and is a fundamental component of the assessment of the lower limb after venous intervention.<sup>148</sup> Studies reporting on recurrent varicose veins largely use DUS examination in their assessment of the venous system.<sup>164–167</sup> As recurrent disease will be most likely secondary to intervention in the GSV or SSV systems, DUS is an appropriate, low risk imaging modality to assess these patients.

It is important to understand that DUS examination diagnosed recurrence may be present in the absence of clinical recurrence. Patients may have recurrent reflux identified during DUS examination that does not cause any clinical symptoms. The 5 year recurrence rate on DUS has been reported at 64%, with a clinical recurrence rate of 4%.<sup>168,170</sup>

### 3.2.4. Plethysmography and venous pressure measurements

**3.2.4.1. Strain-gauge plethysmography. Scientific evidence.** This was first described in 1953 by Whitney, and then developed as a method for indirect venous function measurement.<sup>171</sup> It was then developed for DVT detection or for quantification of post-thrombotic syndrome (PTS). By determining a pressure volume relationship, this technique can translate the volume reduction into a pressure decrease.<sup>172</sup>

**3.2.4.2. Photoplethysmography. Scientific evidence.** The principle of photoplethysmography (also known as light reflection rheography), in which the transmission of light reflection in the subdermal venous plexus is detected as a measure of the change of blood volume in the skin, was described in 1937 by Hertzman.<sup>173</sup> This technique was initially used for arterial research, but adapted by Abramowitz in 1979 for venous applications.<sup>174</sup> In the 1980s, Wienert and Blazek developed the technique towards a standardized digital form.<sup>175,176</sup>

Recommendation 11	Class	Level	References
Duplex ultrasound is recommended as the primary diagnostic test of choice in suspected chronic venous disease, to reliably evaluate the specific venous anatomy and to identify the source and pattern of reflux.	I	A	147, 151, 152
Recommendation 12			
In the presence of suspected abdominal and or pelvic venous pathology, duplex ultrasound is recommended before phlebography, computed tomography venography, and magnetic resonance venography examinations.	I	C	169
Recommendation 13	Class	Level	References
Duplex ultrasound is recommended for the assessment of recurrent varicose veins to identify the source of recurrence.	I	C	148, 165, 170

The main parameter of venous plethysmography is the refill time. There is a good correlation between the refill time and direct venous pressure measurement and photo-plethysmography.<sup>173,177</sup> However, there is no good relationship between the refill time and the degree of venous disease.<sup>178,179</sup>

**3.2.4.3. Air-plethysmography. Scientific evidence.** Using air-plethysmography (APG), volume changes can be measured, with venous filling index (VFI) being the most important parameter.<sup>180,181</sup> Also reflux quantification and ejection fraction have been assessed and APG parameters give an overall evaluation of the functional impairment of the limbs as to venous obstruction/valvular incompetence, quantifying calf pump dysfunction as well.<sup>85</sup>

Since the advance of DUS and other alternative methods, plethysmographical examination techniques have been considered of less importance in routine investigation, and they are no longer considered as stand alone diagnostic tools in patients with CVD. Plethysmography may be considered for assessment of quantitative parameters related to venous function for research purposes and post-treatment follow up.

**3.2.4.4. Foot volumetry.** Foot volumetry is performed in the standing position by immersing the leg in a container with water.<sup>182</sup> The expelled volume (EV) in mL and the refilling rate (Q; mL/100 mL × minute), as well as the total foot volume (mL), are measured. It has been used to assess compression treatment in venous insufficiency and to predict results of interventions on the superficial venous system in case of venous ulceration.

### 3.2.5. Phlebography

**Scientific evidence.** The indication for using phlebography in CVD patients with varicose veins has decreased significantly with the advent of DUS. In the evaluation of superficial, perforating, and deep vein incompetence, DUS is at least as reliable as phlebography.<sup>155,156</sup> However, in the diagnosis of pelvic vein obstruction or incompetence (gonadal veins, iliac veins) and of vascular malformations, when alternative imaging techniques are inconclusive, phlebography can represent a necessary investigation.

In the presence of vascular malformation, complex post-thrombotic cases, or cases of complex recurrent varicose veins, phlebography may help to elicit possible abdominal and/or pelvic vein involvement.

### 3.2.6. Other imaging methods

**3.2.6.1. Scientific evidence.** Both CTV and MRV have evolved significantly in recent years and it is now possible to obtain detailed three dimensional reconstructions of the venous system.<sup>183–188</sup> Ilio-caval and pelvic venous pathology (post-thrombotic obstruction, venous compression/stenosis like Nutcracker syndrome or May-Thurner syndrome and pelvic varicocele) can be reliably identified.<sup>189–193</sup> However, there is insufficient scientific evidence to adequately judge the true effectiveness of both techniques for visualization of the venous vasculature given the heterogeneity of the published studies. Furthermore, in varicose vein disease the use of CTV and MRV should be limited to the specific indications mentioned above.

Recommendation 14	Class	Level	References
Plethysmography may be considered for the assessment of quantitative parameters related to venous function.	IIb	C	85, 180, 181
Recommendation 15			
Foot volumetry is not recommended in the routine diagnosis of patients with chronic venous disease.	III	C	182

Recommendation 16	Class	Level	References
Phlebography may be considered in cases where other diagnostic tools are inconclusive (mainly in the diagnosis of abdominal/pelvic vein diseases).	IIb	B	155, 156

In patients with (severe) renal impairment, administration of intravenous contrast in both MRV and CTV examinations may be contraindicated. A disadvantage of the MRV examination is that the acquisition time is significantly longer compared with CTV. Unlike MRV, however, CTV involves exposing the patient to radiation. Both techniques can be used to diagnose deep venous obstruction, but MRV has the advantage of displaying more heterogenic information of intravascular abnormalities, which may be useful in determining the therapeutic (endovascular) options.<sup>183</sup> The decision of whether to perform MRV or CTV is still mainly dependent on the local expertise in performing and evaluating these studies.

Complementary to the aforementioned techniques, intravascular ultrasound (IVUS) is suitable for determining ilio-caval venous compression.<sup>169,194–198</sup> To assess chronic venous obstruction or incompetence and for planning a deep venous reconstruction, DUS examination, CTV or MRV, ascending and descending phlebography and in selected cases IVUS have to be performed. In addition, venous pressure measurement can be performed to clarify whether the venous collaterals are capable of adequately reducing ambulatory venous hypertension.<sup>154,169,194,199–203</sup>

## CHAPTER 4: TREATMENT OPTIONS IN CHRONIC VENOUS DISEASE

### Introduction

A variety of treatment methods are currently available for patients with CVD, and these are presented in detail below.

#### 4.1. Dressings for venous ulcers

**Scientific evidence.** A large number of types of wound dressing are in current use for venous ulcers. Two separate Cochrane reviews concluded that alginate and foam dressings do not increase venous ulcer healing rates and that more research is needed before recommending them.<sup>204,205</sup> Similar results have been shown for hydrocolloid dressings.<sup>206</sup> There is also no evidence to support the routine use of silver donating dressings beneath compression for venous ulceration.<sup>207</sup>

Another Cochrane review showed that the use of topical cadexomer iodine was more effective than standard care in achieving complete healing when added to compression therapy (risk ratio 6.7,  $p = .011$ ). However, use of compression with povidone iodine versus hydrocolloid dressings was equivalent in achieving complete wound healing.<sup>208</sup>

Recommendation 17	Class	Level	References
To evaluate patients with post-thrombotic syndrome or clinical suspicion of other forms of iliac or inferior vena cava obstruction, duplex ultrasound examination of the veins of the lower limbs and abdominopelvic veins is recommended (whenever feasible).	I	C	154, 169, 194, 200, 201
<b>Recommendation 18</b>			
In patients with clinical signs of persistent venous hypertension (clinical class C3-C6, symptoms of venous claudication, venous collaterals on pubis or abdomen, or rapid recurrence of varicose veins) with or without a history of deep venous thrombosis, additional investigation of the venous system should be considered. This should include imaging of the iliac veins and inferior vena cava.	IIa	C	154, 169, 194, 199-203

Recommendation 19	Class	Level	References
If there is an indication to treat supra-inguinal venous pathology, additional imaging (magnetic resonance venography and computed tomography venography) is recommended.	I	C	169, 194-198
<b>Recommendation 20</b>			
If both magnetic resonance venography and computed tomography venography are inadequate, intravascular ultrasound may be considered as an additional technique for identifying and treating ilio-caval obstruction.	IIb	C	189-193

Zinc oxide impregnated paste bandages have been shown to achieve better ulcer healing compared with alginate dressings and the zinc oxide stockingette.<sup>209</sup> Further research is needed to investigate the role of zinc dressings on wound healing.

Local allergic side effects might limit the use of topical antimicrobial dressings.

graduated elastic compression.<sup>211</sup> Higher pressure at calf level during walking also seems to be the reason why inelastic bandages are haemodynamically more effective than stockings, which give way during muscle contraction.<sup>212</sup> Despite the popularity of elastic stockings, evidence of their efficacy is unclear, based on the lack of randomized controlled trials for both superficial venous incompetence and the post-thrombotic leg.<sup>213,214</sup>

Recommendation 21	Class	Level	References
Wound dressings may be considered to promote healing of venous ulceration.	IIb	A	204, 205, 208
Recommendation 22			
Zinc dressings and cadexomer iodine may be considered to promote venous ulcer healing as first and second choice, respectively.	IIb	C	209

#### 4.2. Compression therapy

**Introduction.** Compression therapy, despite significant improvements in dressing materials and other methods, remains the cornerstone of conservative treatment. This is because of its ease of use, non-invasive nature, and also efficacy in managing venous hypertension, the main pathophysiological mechanism of CVD.

The most common forms of therapeutic leg compression are elastic stockings, including tights, non-elastic and elastic bandages (short and long stretch), and intermittent pneumatic compression. The mechanisms of action include compression of superficial and deep veins and improvement of the muscle pump function, both leading to reduction of ambulatory venous pressure and reduction of oedema.

However, there is ample lower quality evidence based on non-RCTs and clinical experience, to suggest their use because they improve patient symptoms<sup>213</sup> and they improve patients' QoL.<sup>215</sup> In general, there are issues putting on and removing elastic stockings, especially in the elderly, which along with the sensation of warmth and deterioration of pre-existing pruritis associated with venous eczema, could account for the suboptimal patient compliance.<sup>216</sup> Additional issues include potential skin damage, and contraindications to use including peripheral arterial disease. Also, elastic stockings require proper fitting and, to remain effective, should be replaced at intervals of 3–4 months, according to the manufacturers' instructions.

Recommendation 23	Class	Level	References
Elastic stockings are recommended as an effective treatment modality for symptoms and signs of chronic venous disease.	I	B	213, 215
Recommendation 24			
Temporary use of elastic stockings may be considered in patients with chronic venous disease awaiting further investigation, and as a definite treatment in patients who are not managed by invasive methods.	IIb	C	

##### 4.2.1. Chronic venous disease without ulceration (C0–C4)

**Scientific evidence.** Elastic stockings in the form of graduated compression have been the cornerstone of conservative management of CVD C0–C4 for decades. They compress varicose veins, reduce venous reflux, and improve calf muscle pump function. More recently it has been shown that progressive graduated compressive stockings (higher pressure at the calf compared with the ankle) are more effective than the usual degressive graduated compressive stockings (higher pressure at the ankle) in improving pain and lower leg symptoms. Furthermore, they were easier to apply.<sup>210</sup> These beneficial effects might be related to the observation that progressive graduated compressive stockings have a more pronounced effect on venous pumping function than

##### 4.2.2. Venous ulceration (C5–C6)

**4.2.2.1. Venous ulcer healing. Scientific evidence.** Compression bandages have been shown to improve healing rate of ulcers compared with standard care without compression.<sup>217–219</sup> An alternative to traditional bandaging is non-elastic compression, including the Unna boot (a compression dressing impregnated with zinc oxide paste) and a non-elastic compression system based on adjustable Velcro bands that can be changed and adjusted daily eliminating odorous secretions.<sup>220</sup> However, involving an elastic component in a bandage system seems more effective in terms of wound healing than when it is not involved.<sup>219</sup>

In a RCT, sustained compression of at least 40 mmHg with a four layer compression bandage over a week has been

shown to be more effective than lower grades of compression.<sup>221</sup> However, other bandage types applying sustained high pressure compression (including two or three layer compression bandages, the Unna boot, paste bandages, or high compression stockings) have been shown by the vast majority of studies to be equally effective as four layer compression bandages.<sup>222–230</sup> This is likely to be the result of improved properties of the former materials (including adhesiveness of bandaging material allowing it to be kept in place) and familiarity of use.<sup>231</sup> However, use of a four layer bandage does result in faster healing of ulcers compared with a short stretch bandage.<sup>219</sup>

Until several trials with conclusive results favouring one particular compression system are published, the initial treatment modality should be the one with which the person applying the compression is most familiar. However, the differential properties of the various bandage types deserve further investigation.<sup>232</sup>

### 4.2.3. Intermittent pneumatic compression for venous ulceration

**Scientific evidence.** Intermittent pneumatic compression (IPC) improves venous flow significantly in patients using elastic bandages,<sup>237</sup> while, in combination with elastic stockings, it has been shown to increase healing rates and overall healing of venous ulcers compared with elastic stockings alone.<sup>238</sup> Three subsequent trials either failed to demonstrate any benefit when IPC was used in conjunction with compression,<sup>239</sup> or this was marginally significant.<sup>240,241</sup> This raises concerns regarding its efficacy.<sup>242</sup> However, in a trial that included patients with venous ulcers not using background compression, rapid IPC (one short compression period of 6.5 s three times a minute) healed 86% of venous ulcers compared with 61% with slow IPC (one long compression period of 90 s every 3 minutes) at 6 month follow up,  $p = .003$ .<sup>243</sup>

It has been proposed that IPC should be provided only for patients with refractory oedema and significant leg ulceration

Recommendation 25	Class	Level	References
Compression bandages and walking exercises are recommended as the initial treatment modality to promote healing in patients with venous leg ulcers.	I	A	217, 218
<b>Recommendation 26</b>			
The use of high compression pressures of at least 40 mmHg at the ankle level should be considered, to promote ulcer healing.	IIa	B	221

#### 4.2.2.2. Venous ulcer recurrence. Scientific evidence.

Compression is important to prevent ulcer recurrence and most benefit is seen from high compression; however, this is more likely to be associated with patient intolerance.<sup>233</sup> Following healing of the ulcer, compression bandages should be replaced by elastic stockings. The latter could be the definitive treatment, particularly in patients with deep vein occlusion or gross incompetence not amenable to widely accepted surgical or interventional solutions. Patients should wear the highest level of compression that is comfortable, preferably 25–35 mmHg at ankle level.<sup>234</sup> In the ESCHAR trial, compression in the form of four layer bandaging was shown to be equally effective with surgery and compression in achieving healing of venous ulcers, although long-term effects were less durable in terms of recurrence compared with surgery.<sup>235</sup>

Another trial reached similar conclusions but surgery combined with ambulatory compression therapy was more durable than compression alone in patients with medial and/or recurrent ulceration, who should receive superficial and perforating vein surgery.<sup>236</sup>

tion after a 6 month treatment course, with standard methods such as compression stockings, has failed.<sup>244</sup>

IPC is also effective in CVI and higher compression pressures have been reported to be associated with greater leg volume reduction in patients with chronic venous oedema.<sup>245</sup> IPC is able to provide symptom relief in patients with PTS.<sup>246,247</sup>

More research is needed to establish which kind of compression may, in combination with IPC, be most beneficial in ulcer healing. Also the IPC impact should be studied in relation to ulcer characteristics (duration since onset, surface area and depth).

### 4.2.4. Compression after venous intervention

**Scientific evidence.** A meta-analysis has shown that short duration (about a week) compression after varicose vein surgery is as good regarding post-operative pain, leg volume, incidence of complications and absence from work as longer use (3–6 weeks) of compression.<sup>248</sup> Additionally, after EVLA, use of high compression profile (35 mmHg) elastic stockings for 7 days significantly reduced pain and

Recommendation 27	Class	Level	References
Compression with elastic or non-elastic bandages or other compression devices is recommended as the initial treatment modality for venous leg ulcers; however, the possibility of an active venous intervention should be explored and offered to maintain healing.	I	B	235, 236

Recommendation 28	Class	Level	References
Intermittent pneumatic compression is recommended to provide symptomatic relief in patients with chronic venous disease (C3-C6) if standard methods are not indicated or if they have failed.	I	A	245-247
<b>Recommendation 29</b>			
Intermittent pneumatic compression should be considered in patients with venous ulcers after a 6 month treatment course when standard methods have failed.	IIa	B	238

improved both physical function and vitality when compared with use for 2 days.<sup>249</sup>

Similarly, after foam sclerotherapy, compression bandaging for 24 hours and thromboembolus deterrent stockings for a fortnight were equivalent to 5 days of bandaging, confirming results shown by a previous study with a similar design.<sup>250,251</sup> However, use of low compression profile elastic stockings after foam sclerotherapy of larger veins had no effect on efficacy, side effects, and satisfaction scores compared with a control group without compression.<sup>252</sup> Following superficial vein surgery for venous ulceration, especially after GSV stripping to the knee or residual deep or superficial venous reflux, continuation of compression could be considered.

Use of elastic stockings (23–32 mmHg) for 3 weeks after sclerotherapy for leg telangiectasias, compared with no such intervention, was associated with an improved efficacy as determined by clinical vessel disappearance.<sup>253</sup>

Further studies are needed to establish the duration of compression as well as the type of compression (full length or knee length) following superficial vein surgery for ulceration.

function and dynamic calf muscle strength can be improved with exercise,<sup>256,257</sup> as can the range of ankle movement.<sup>258</sup>

One small underpowered RCT showed a non-significant trend for reduced ulcer size with physiotherapy compared with no intervention.<sup>259</sup> Another RCT showed that the group of patients who received lifestyle counselling had increased physical activity and reduced wound days compared with the control group, but a larger RCT of 40 patients failed to demonstrate any effect of home based progressive resistance exercise on ulcer healing parameters.<sup>260,261</sup>

Properly powered studies are needed on the effect of supervised exercise on healing rates of venous ulcers.

#### 4.3.2. Leg elevation

**Scientific evidence.** Leg elevation has been used for a long time and is still recommended to patients to ameliorate venous stasis, provide symptomatic relief, reduce leg oedema, and promote healing of ulcers in patients with CVD.<sup>262,263</sup>

Leg elevation in patients with CVD classified as C3–C6 has been shown to reduce leg volume and venous pressure, and to enhance the microcirculatory flow velocity in lipodermatosclerotic skin.<sup>264–266</sup>

Recommendation 30	Class	Level	References
Post-procedural compression is recommended after superficial venous surgery, endovenous truncal ablation, and sclerotherapy.	I	A	248-251, 253

### 4.3. Physiotherapy, leg elevation, and leg massage

#### 4.3.1. Physiotherapy for leg ulceration

**Scientific evidence.** A reduced range of joint mobility has been described in CVD, correlating with the disease severity (CEAP clinical class) and haemodynamic changes on air plethysmography.<sup>254</sup> A fixed ankle joint and reduced range of movement have been shown to be independent parameters associated with non-healing of venous ulcers, indicating that these findings are related to the impairment of the calf muscle pump.<sup>255</sup> Furthermore, calf muscle pump

In the past, elevation has been used as the main measure to heal venous leg ulcers or as an adjunctive measure in patients wearing elastic bandages.<sup>267,268</sup> It is still practiced in combination with antibiotics and debridement in cases of infected ulcers where compression cannot be tolerated because of pain associated with cellulitis in the surrounding areas. In a retrospective study, elevation was a statistically significant predictor of ulcer free survival among other variables, while in a structured education programme, patients who were allocated to the study group spent more

Recommendation 31	Class	Level	References
Physiotherapy is not recommended as a measure to enhance healing of venous leg ulceration. However, patients with venous ulcers should be kept as mobile as possible.	III	A	259, 261

time with their legs elevated each day and had a reduced ulcer recurrence rate.<sup>269,270</sup> Others reported that in the presence of compression, there was no correlation between median leg elevation per 24 hours and percentage decrease in ulcer size.<sup>265</sup> Although still recommended, treatment cannot rely on this otherwise simple advice, because patient compliance is poor and ulcer recurrence is extremely common even after a period of prolonged hospitalization.<sup>271,272</sup> Finally, leg elevation has been used before bandages are applied and could also be used to reduce leg swelling before elastic stockings are fitted.<sup>273</sup>

Prospective, randomized studies should be performed investigating the role of leg elevation in healing venous leg ulcers. But even with the lack of strong evidence, practice and physiology suggest that leg elevation is helpful.

that there was insufficient evidence to support the use of all venoactive drugs in the treatment of CVD. However, it also showed that micronized purified flavonoid fraction (MPFF) was the most effective at reducing symptoms of oedema and restless legs. Calcium dobesilate reduced cramps and restless legs. MPFF helped in healing venous ulcerations and was also useful in treatment of cramps and swelling. Rutosides decreased venous oedema.<sup>275,276</sup>

A Cochrane review of 17 randomized controlled trials (RCTs) showed that horse chestnut extract (HCSE) was effective at decreasing oedema, pain, and itching.<sup>277</sup>

Numerous studies have been conducted especially with MPFF, showing that these products lead to improvement of symptoms by increasing the venous tone.<sup>278–282</sup> The

Recommendation 32	Class	Level	References
Leg elevation may be considered for patients with leg ulcers when compression cannot be tolerated because of acute inflammation or as an adjunct to compression during resting periods.	IIb	C	268-270

### 4.3.3. Leg massage

**Scientific evidence.** This method can be part of a multi-component regimen aimed at reducing tissue oedema by applying deep massage around the ulcer area, before formal compression is applied, or as an adjunct. Leg massage entails a form of light massage over elastic compression with a stocking.<sup>267,274</sup> Further studies are necessary to assess the role of leg massage in patients with venous oedema, but IPC has largely replaced leg massage.

RELIEF study included 5,052 CVD patients with clinical class C0 to C4. They were divided into two groups: with and without reflux. All patients received MPFF over 6 months. Assessment was made of presence and/or severity of pain, heaviness, sensation of swelling, and cramps in lower limbs. Oedema was measured using the Leg-O-Meter. In both treatment groups, MPFF significantly reduced symptoms and signs, and reduced ankle oedema.<sup>125</sup>

Recommendation 33	Class	Level	References
Leg massage may be considered as an adjunctive treatment to reduce oedema in patients with chronic venous disease.	IIb	C	267, 274

### 4.4. Medical treatment

**Introduction.** Medical treatment has been used for decades, but its place as a treatment modality for CVD is a topic of continuing debate. Venoactive drugs are widely prescribed in some countries but are not available in others. They can be classified into two groups: natural and synthetic drugs, such as naftazone and calcium dobesilate, respectively. The main modes of action of venoactive drugs are to decrease capillary permeability, diminish release of inflammatory mediators, or improve venous tone. Non-venoactive drugs like pentoxifylline, reduce white cell activation, and acetylsalicylic acid inhibits platelet function and also has an anti-inflammatory effect.

#### 4.4.1. Chronic venous disease without ulceration (C0–C4)

**Scientific evidence.** In 2005, a Cochrane review of 110 publications was published with 44 studies (CEAP classification C0–C4) considered valid. This review concluded

Another RCT compared MPFF with placebo and could only show a difference in night cramps without changing other symptoms of CVD.<sup>283</sup>

Calcium dobesilate is a synthetic venoactive drug which has been evaluated in a few RCTs and one meta-analysis published in 2004. A recent large RCT with 509 patients could not show a difference between its study groups.<sup>284</sup> However, a double blind, placebo controlled trial showed that calcium dobesilate reduces leg oedema and improves the symptoms of objectively diagnosed CVD independent of the concomitant usage of compression stockings.<sup>285</sup>

The effect of Red vine leaf extract was evaluated in a prospective randomized trial including 248 patients. Efficacy endpoints were changes in limb volume determined by water displacement volumetry, clinical CVD symptoms assessed on a visual analogue scale and global efficacy evaluations. Red vine leaf extract reduced lower limb



Recommendation 34	Class	Level	References
Venotonic drugs should be considered as a treatment option for swelling and pain caused by chronic venous disease.	Ila	A	125, 275-282, 285, 286

volume and CVD related symptoms significantly more than placebo.<sup>286</sup>

#### 4.4.2. Venous ulceration (C5–C6)

**Scientific evidence.** A Cochrane database review showed that pentoxifylline is effective as an adjuvant therapy to compression, but it also appeared to be effective in the absence of compression.<sup>287</sup> Other studies showed an accelerating healing time when patients were treated with pentoxifylline,<sup>288,289</sup> in addition to wound care.<sup>290</sup>

Other products, like acetylsalicylic acid and oral zinc, are not routinely recommended for the promotion of healing venous leg ulcers.<sup>291–294</sup> Some studies showed an acceleration of healing in a patient group treated with acetylsalicylic acid, but these were small studies and there was large

findings.<sup>298,299</sup> However, according to a Cochrane review, the studies mentioned above showed shortcomings in terms of blinding and allocation.<sup>300</sup>

In 2005, a meta-analysis of five RCTs was performed (723 patients with venous ulcers). This showed that at 6 months, the chance of healing certain subtypes of ulcers was 32% higher in patients treated with MPFF as an adjunctive treatment in comparison with conventional therapy alone.<sup>301</sup>

A more recent review concluded that in prospective randomized studies, MPFF and other flavonoid derivatives, and pentoxifylline have demonstrated clinical benefits in patients with CVD (clinical class C4–C6).<sup>284</sup> Therefore pharmacotherapy should be part of a range of treatment options in the modern management of patients with CVD.

Recommendation 35	Class	Level	References
Sulodexide and micronized purified flavonoid fraction should be considered as an adjuvant to compression therapy in patients with venous ulcers.	Ila	A	295, 297-299, 301
<b>Recommendation 36</b>			
The routine use of zinc, oral antibiotics, horse chestnut seed extract, and pentoxifylline is not recommended in patients with venous leg ulceration.	III	B	208, 287-290, 294, 296
<b>Recommendation 37</b>			
Acetylsalicylic acid is not recommended to promote healing of venous leg ulcers as routine treatment, but it may be considered in therapy of resistant ulcers.	III	C	291-293

variation in the number and size of ulcers. Further research is necessary on this subject.<sup>291–293</sup>

The effectiveness of routine use of systemic antibiotics for venous ulcers could not be demonstrated in a Cochrane review based on 25 RCTs.<sup>208</sup> However, in light of the increasing problem of bacterial resistance to antibiotics, current guidelines recommend that antibacterial preparations should only be used in cases of clinical infection and not for bacterial colonization.

There is some evidence that sulodexide can support ulcer healing in combination with compression therapy.<sup>295</sup>

Although it was thought likely that HCSE would attenuate the pathogenesis of venous insufficiency and, in turn, facilitate venous ulcer healing, a study by Leach did not support this.<sup>296</sup> A possible reason is that reducing oedema alone is insufficient to treat venous ulcers.

The time to complete ulcer healing was compared in a study of patients taking MPFF versus placebo.<sup>297</sup> There was a significant reduction in healing time in the treated group compared with the placebo group. Other symptoms, like heavy sensation of the legs, were evaluated and were also shown to be reduced. Other studies have confirmed these

#### 4.5. Sclerotherapy

**Introduction.** Sclerotherapy involves injection of dilated veins, including major refluxing trunks or tributary varicosities, venules, or telangiectasias, with liquid or foam chemical agents to damage the endothelium and eventually ablate the veins.

**Scientific evidence.** A number of chemical agents — sclerosants — with a variety of mechanisms of action have been used to damage and denude the vessel endothelium, including polidocanol, sodium tetradecyl sulphate (STS), morrhuate sodium, glycerin, and hypertonic saline, either as pure agents or in the form of foam, in increasing concentrations according to the size of vein being treated. Some of these have been mixed with lidocaine to reduce pain during injection.<sup>302,303</sup> Post-procedural compression is an integral part of this type of treatment, which can be used to treat the entire spectrum of refluxing superficial veins, including the saphenous veins, and telangiectasias with a great degree of efficacy and safety.<sup>304</sup> The reader is referred to section 4.2.4. for further information. However, patients should be informed of possible side effects (such

as skin necrosis, telangiectatic matting, hyperpigmentation, and also allergic reactions) and complications (such as deep vein thrombosis, pulmonary embolism, or cerebral embolic event for foam sclerotherapy in the presence of a right to left cardiac shunt).<sup>305,306</sup>

Liquid sclerotherapy is more effective than placebo injection for telangiectasias and reticular and/or varicose veins.<sup>307,308</sup> However, in two Cochrane reviews, there is no evidence suggesting superior efficacy of any one sclerosant over another.<sup>309,310</sup> Lower concentrations of the sclerosant agent are used for smaller veins. In addition to effectiveness,<sup>307,311</sup> sclerotherapy is less time consuming and is an easily repeatable treatment. It provides faster recovery with less pain and is relatively inexpensive compared with surgery or endovenous thermal ablation (EVTA). However, varicose vein recurrence, as high as 90% after 6 years,<sup>312</sup> and the need for additional treatment (more often compared with surgery) are inherent major problems,<sup>312,313</sup> as summarized also by a Cochrane review.<sup>314</sup> This is true not only for the major saphenous trunks, but also for varicose tributaries if the source of incompetence has not been eliminated.<sup>315</sup> On the other hand, good long-term results in the primary treatment of isolated varicose veins, not associated with saphenous vein incompetence have been demonstrated.<sup>312</sup> Treatment of recurrent varicose veins following surgery is another indication, by avoiding the morbidity (40% in one study) associated with redo surgery.<sup>316</sup>

an adjuvant treatment of varicose tributaries following endovenous ablation of the main refluxing trunk,<sup>321</sup> or high ligation (HL),<sup>322</sup> or to treat recurrent varicose veins.<sup>323,324</sup> It is also widely used to treat telangiectasias and reticular veins, although there is no evidence that foam sclerotherapy is better than liquid sclerotherapy in this setting.

UGFS is characterized by a higher recanalization rate when treating veins larger than 5–7 mm in diameter.<sup>325–327</sup> Foam sclerotherapy is associated with a higher recanalization rate and similar results in terms of symptoms and QoL assessment when compared with surgery, laser or radio-frequency endovenous ablation for treating GSV reflux.<sup>328–331</sup> Foam sclerotherapy proved significantly cheaper<sup>329</sup> and it may be considered an attractive minimally invasive alternative to surgery to treat superficial incompetence,<sup>332,333</sup> particularly in elderly and frail patients and especially in those with venous leg ulcers.<sup>334,335</sup> Repeat treatment may be considered an integral part of UGFS in some of the treated patients and the additional cost incurred must be integrated into the global cost when it is compared with the other techniques (surgery or thermal ablation). Foam sclerotherapy is becoming an increasingly popular choice in the management of patients with recurrent varicose veins.<sup>315,324,332</sup> Long catheter foam sclerotherapy has been introduced recently and its short-term efficacy is equal or superior to the usual UGFS for GSV reflux.<sup>336–339</sup> Long-term results are awaited.

Recommendation 38	Class	Level	References
Liquid or foam sclerotherapy is not recommended as the first choice treatment for chronic venous disease C2-C6 due to saphenous vein incompetence. It should be used only as primary treatment in selected cases.	III	A	317-320, 328-331
<b>Recommendation 39</b>			
Foam sclerotherapy is recommended as a second choice treatment of varicose veins (C2) and for more advanced stages of chronic venous disease (C3-C6) in patients with saphenous vein incompetence, not eligible for surgery or endovenous ablation.	I	A	314, 328, 329
<b>Recommendation 40</b>			
Foam sclerotherapy should be considered as primary treatment in patients with recurrent varicose veins, and in elderly and frail patients with venous ulcers.	IIa	B	334, 335
<b>Recommendation 41</b>			
Liquid sclerotherapy should be considered for treating telangiectasias and reticular veins (C1).	IIa	B	308

Foam sclerotherapy, usually guided by DUS (ultrasound guided foam sclerotherapy, UGFS), has been shown to be more effective than liquid sclerotherapy because of the enhanced sclerosing properties of the foam form of the sclerosant.<sup>317–320</sup> Foam sclerotherapy has been used as

**4.6. Transcutaneous laser**

**Introduction.** Surface transcutaneous laser (TCL) has been used for the treatment of telangiectasias and reticular veins since the 1970s. The mechanism behind this treatment is to

cause endothelial injury of the vein by heating the haemoglobin and eventually to obliterate the lumen. The advent of laser technology with delivery of sufficiently controlled energy has enabled achievement of pan-endothelial necrosis without affecting more superficial structures such as the epidermal layer. High intensity pulsed light therapy, which was introduced in 1990, represents a further development in the field as it allows treatment of reticular veins by emitting a spectrum of light rather than a wavelength to obliterate the vein.

**Scientific evidence.** TCL is an effective treatment for telangiectasias and reticular veins, although not capable of making them to disappear completely.<sup>340</sup> Laser light is emitted from the laser equipment and transmitted through the skin to the targeted vessel, where it is selectively absorbed by the oxyhaemoglobin and converted to thermal energy leading to heating of the telangiectatic vein, coagulation, and vessel destruction. Different settings of laser are used for blood vessels of different diameter and skin type and/or colour.<sup>341,342</sup>

TCL is less effective than sclerotherapy at managing leg telangiectasias, requires more treatment sessions,<sup>343,344</sup> and is more expensive. However, particular indications include: 1. known allergy to sclerosant solutions, 2. needle phobia, 3. telangiectatic matting after sclerotherapy, 4. failure of sclerotherapy,<sup>345</sup> and 5. vessel size less than 0.5 mm.

Recent technical modifications have been reported to significantly improve the efficacy of TCL.<sup>346,347</sup> Indocyanine green (ICG)-augmented diode laser therapy has been shown to be superior to pulsed dye laser and the diode laser without ICG.<sup>346</sup> Similarly, improved results have been demonstrated in combination with sclerotherapy.<sup>348</sup>

More studies are needed to establish which telangiectatic veins, and at what site in the lower limb, are better managed with TCL. Also, the role of elastic compression after TCL should be further investigated.

(RFA). Another endovenous thermal ablation (EVTA) technique is steam ablation.<sup>350</sup> Other more recently introduced techniques are mechanochemical ablation (MOCA)<sup>351</sup> and injection of cyanoacrylate glue.<sup>352</sup>

The use of EVTA (EVLA, RFA, Steam) techniques requires injection of tumescent liquid around the target vein. The purpose of this is to protect the perivenous tissue from the heat created during treatment. The tumescent liquid acts as a heat sink.<sup>353</sup> Other purposes of the tumescent liquid injection are to create spasm of the vein and to obtain local compression and anaesthesia. The new non-thermal ablation techniques (MOCA and glue injection) can be performed without injection of tumescence during the ablation.

The scientific evidence for cyanoacrylate glue injection is too little to warrant further attention in this chapter because of the lack of publications. Steam ablation seems to give results comparable with other thermal ablation techniques at 1 year follow up,<sup>354</sup> but more studies are necessary to confirm those results in the medium and long term.

#### 4.7.1. Endovenous thermal ablation

**Introduction.** To evaluate the two most commonly used EVTA techniques, EVLA and RFA, six meta-analyses,<sup>355–360</sup> 31 RCTs,<sup>328,361–390</sup> six non-randomized comparative clinical trials,<sup>391–396</sup> seven prospective clinical trials,<sup>397–403</sup> and one technical review article were selected.<sup>404</sup>

**4.7.1.1. Great saphenous vein. Technique.** The technique is similar for all EVTA methods. The procedure is performed percutaneously with ultrasound guidance. A laserfibre or RFA catheter is inserted and positioned 1–2 cm distal to the SFJ, and tumescent liquid is injected around the saphenous vein. A very dilute solution of local anaesthetic combined with bicarbonate and epinephrine is used for this purpose. It is important to empty the vein of blood as much as possible. While withdrawing the catheter or fibre, energy is emitted intraluminally to cause irreversible ther-

Recommendation 42	Class	Level	References
Transcutaneous laser may be indicated for treatment of teleangiectasias, only when sclerotherapy is not applicable.	IIB	C	345

#### 4.7. Endovenous treatments

**Introduction.** Endovenous techniques in the treatment of saphenous vein incompetence have become very popular as a minimally invasive alternative to classical surgery (HL and stripping). In countries where reimbursement is available, the vast majority of patients are treated endovenously. It was Carlos Boné in 1999, who first treated patients with endovenous laser.<sup>349</sup> In the past 10 years, endovenous techniques have evolved quickly and performance has improved.

The two most frequently used techniques are endovenous laser ablation (EVLA) and radiofrequency ablation

mal destruction of the endothelium of the vein wall. Compression post intervention is recommended (see section 4.2.4.), but the duration of compression is not clearly defined.<sup>405,406</sup>

**Effectiveness.** Occlusion rates of EVLA vary between 77%<sup>365</sup> and 99%<sup>362</sup> at 1 year. Compared with surgery (HL and stripping), most studies report no significant difference in varicose vein recurrence (clinical) or recurrent reflux (according to DUS) after treatment.<sup>328,356,364–366,368–370,391</sup> Other studies report a higher recurrence rate after surgery (20% vs. 4% at 1 year)<sup>362</sup> or after EVLA (7.4% vs. 0% at 2 years).<sup>363</sup> Neovascularization at the SFJ is an important

cause of varicose vein recurrence after treatment. This was seen more commonly after surgery, although this was not significantly different,<sup>359</sup> compared with EVTA.<sup>366,372</sup> Compared with RFA, surgery seems to be more efficient<sup>373,376</sup> or equally effective.<sup>371,372</sup> In cases in which surgery was more efficient, RFA was performed using the older “Closure Plus” catheter (VNUS Med Tech, San Jose, CA, USA). Meta-analyses show that RFA and EVLA are as effective as surgery in the treatment of GSV incompetence.<sup>355,357,359</sup> The first published meta-analysis on EVTA reports superior results of EVLA compared with surgery and RFA.<sup>355</sup> This study, however, only includes trials using either EVLA with lower wavelength or RFA with the “Closure Plus” catheter, and uses heterogeneous definitions of treatment failure.

**Safety.** No difference in safety including the risk of venous thromboembolism could be determined, comparing EVTA and surgical treatment for saphenous vein incompetence.<sup>367,391</sup>

The reported incidence of DVT varies between 0.2% and 1.3% in EVTA, and seems to be higher in patients treated with RFA compared with EVLA.<sup>357</sup> The latter meta-analysis mainly included the old RFA techniques and EVLA with bare tip fibres and lower wavelength. Development of thrombus extension at the SFJ (often called endovenous heat induced thrombosis) can be found in a limited number of cases. Case series report a frequency varying between 0.3% and 7.8% of patients after EVTA.<sup>395,397–399</sup> When thrombus extends into the common femoral vein treatment by anticoagulation (AC) is advised. Pulmonary embolism was reported in 0.0% to 3% after EVLA.<sup>395,398</sup> Nevertheless, the role of routine use of pharmacologic prophylaxis remains uncertain and more studies are necessary.

Thrombo-prophylaxis can be prescribed for high risk patients (previous venous thromboembolism, documented thrombophilia, obesity, immobilized patients, patients with neoplasm, and older patients).<sup>407,408</sup> However, risk factors should be weighted for each individual patient using a specific risk assessment score such as the Caprini score.<sup>409</sup> Patients can be treated in an outpatient setting under local tumescent anaesthesia, which permits early ambulation reducing the risk of possible thromboembolic complications.

**Side effects.** Post-operative complications in EVTA are limited. Reported complications are thrombophlebitis (7%),<sup>359</sup> thermal skin injury (<1%),<sup>359</sup> bruising, hyperpigmentation (5%),<sup>359</sup> paresthesia (1–2%),<sup>364,369</sup> and haematomas (0–7%).<sup>364,369,374,378</sup> Compared with EVTA, surgically treated patients more frequently develop complications, such as wound infection (2–6% for surgery vs. 0% for EVTA)<sup>356</sup> and haematomas (5% for surgery vs. 2% for EVTA).<sup>359</sup> Patients treated with EVTA have, on average, less pain compared with patients treated surgically.<sup>356,365,369,374,377,378</sup> Post EVTA as opposed to surgery, swelling and bruising is reduced.<sup>391</sup> This results in quicker recovery<sup>357,362,375,376</sup> and faster return to normal activities.<sup>364,365,374,378,392</sup> Endovenously treated patients also

seem to have an equal<sup>364,366,367</sup> or better<sup>361</sup> QoL after treatment. The risk of superficial thrombophlebitis appears to be significantly higher (2.3 times) in RFA than in surgery.<sup>356</sup>

**EVLA: different wavelengths and fibres.** To reduce possible side effects of EVLA (pain, bruising, and haematoma), higher laser wavelengths have been introduced and different fibre tips have been developed. Theoretically, light of lower wavelength lasers (810, 940, 980, 1320 nm) is less specifically absorbed by their chromophores (haemoglobin, water, proteins) compared with the light of higher wavelength lasers (1320, 1470, 1500 nm).<sup>404</sup>

The clinical use of higher wavelength lasers should result in equal occlusion rates (97–100%) and less post-operative pain.<sup>396,402,403</sup> There is only one randomized clinical trial comparing the use of lower and higher wavelength lasers.<sup>379</sup> Also, most studies reporting results of higher wavelengths use a lower energy level which makes it difficult to draw any conclusions regarding outcome and potential side effects. As the use of a bare fibre creates unequal energy delivery at the vein wall resulting in local vein wall perforations and perivenous tissue destruction, new fibres have been designed.<sup>380,400,404</sup> The purpose of these new fibre designs is to increase the heated surface area, resulting in lower energy density. The use of these new fibres, Never-touch (AngioDynamics, Latham, NY, USA),<sup>393</sup> Radial fibre (Biolitec, Wien, Austria),<sup>394,400</sup> and Tulip fibre (Tobrix, Waalre, the Netherlands),<sup>380</sup> may be safe and effective in the treatment of saphenous vein reflux.

There is a lack of RCTs comparing these fibres with a standard bare fibre. Only one RCT reports fewer side effects and an equal occlusion rate using a Tulip fibre compared with a bare fibre.<sup>380</sup>

**RFA versus EVLA.** EVLA and RFA have the same occlusion rates, but patients treated with RFA have less post-operative pain and bruising.<sup>328,381–384</sup> This can result in an equal<sup>383</sup> or faster<sup>328</sup> return to normal activities. In trials comparing EVLA and RFA, however, the ClosureFast catheter was compared with lower wavelength lasers using a bare fibre. No trials have been published comparing the use of ClosureFast with higher wavelength lasers and new fibre tip design.

Consideration must be given to the fact that in the last decade the technique and the fibres or catheters used have improved. The more recently introduced ClosureFast catheter (VNUS Med Tech, San Jose, CA, USA), although no RCTs are available, seems to be more effective, faster (shorter operative time), and induces fewer side effects compared with the older “Closure Plus” catheter.<sup>401</sup>

**UGFS versus EVTA/surgery.** The advantage of foam sclerotherapy is its simplicity. There is no need to inject tumescent liquid, the treatment is cheap, and easy to repeat if necessary.

Complications of UGFS include hyperpigmentation, thrombophlebitis, matting, and pain at the injection site. Also, some neurologic events, such as visual disturbances, migraine, and stroke, have been reported.<sup>410–413</sup>

Myers et al. reported primary and secondary success rates of 52.4% and 76.8% respectively.<sup>327</sup> Compared with surgery, UGFS is less efficient<sup>328,329,355,356,414,415</sup> but has significantly fewer side effects (less pain, better post-operative QoL, faster return to normal activities).<sup>322,328,329,356,414–416</sup>

Occlusion rates of saphenous veins treated with UGFS seem to be inferior to those of veins treated with EVTA.<sup>355,356,361</sup> Compared with EVLA, patients treated with UGFS have somewhat less post-operative pain, but no difference could be found compared with RFA.<sup>328</sup>

The results (occlusion rates and side effects) of EVTA in the treatment of saphenous vein reflux also depend on a good technique (e.g. detailed pre-operative ultrasound, correct positioning of the catheter or the fibre tip, targeting injection of tumescent fluid, regular pull back speed). The vein to be treated should be emptied of blood far as possible.

Recommendation 43	Class	Level	References
For the treatment of great saphenous vein reflux in patients with symptoms and signs of chronic venous disease, endovenous thermal ablation techniques are recommended in preference to surgery.	I	A	328, 354, 356, 357, 359, 361-378, 391, 392
<b>Recommendation 44</b>			
For the treatment of great saphenous vein reflux in patients with symptoms and signs of chronic venous disease, endovenous thermal ablation techniques are recommended in preference to foam sclerotherapy.	I	A	322, 328, 329, 355, 356, 414-416

**4.7.1.2. Small saphenous vein. Scientific evidence.** EVTA of the SSV has excellent early and mid-term results.<sup>386,388,389</sup> Access at the lateral malleolus results in a higher paresthesia rate compared with mid-calf access, because of the proximity of the sural nerve to the SSV in the distal part of the calf.<sup>386</sup> EVLA of the SSV is associated with a significantly higher incidence of sensory disturbance compared with EVLA of the GSV.<sup>387</sup> SPJ ligation and stripping of the SSV often fails because of the complex anatomy.<sup>360</sup>

Compared with surgery, EVTA seems to be more efficient and results in fewer post-operative side effects (less paresthesia, pain, and a faster return to normal activities).<sup>388</sup>

UGFS for the treatment of SSV incompetence can be an alternative to EVTA and surgery. Two articles on UGFS showed success rates varying from 82% to 100% (follow up 1.5–60 months). Thrombophlebitis (5%) and hyperpigmentation (24%) were common complications.<sup>326,360,417</sup> There are no RCTs comparing foam sclerotherapy with surgery or EVTA in treatment of SSV incompetence.

Recommendation 45	Class	Level	References
For the treatment of small saphenous vein reflux in patients with symptoms and signs of chronic venous disease, endovenous thermal ablation techniques should be considered. Access to the small saphenous vein should be gained no lower than mid-calf.	IIa	B	386, 387, 389

**4.7.2. Mechanochemical endovenous ablation**

**Introduction.** Recently, a new hybrid (dual injury) technique has been developed (ClariVein Vascular Insights, Quincy, MA, USA). Endomechanical abrasion is produced by the tip of the

catheter’s rotating wire (mechanical component) and endovenous chemical ablation via the simultaneous injection of sclerosant over the rotating wire (chemical component). This technique is under development as the optimal dosage of sclerosans still needs to be determined.

**Scientific evidence.** To date, there have been only two cohort studies including a small number of patients treated with MOCA.<sup>351,418</sup> The occlusion rate at 6 months is 96.7% and side effects seem to be minimal.

**4.8. Surgery of the superficial veins**

**Introduction.** For many years the gold standard for treatment for CVD patients with superficial venous incompetence was surgery.

**4.8.1. High ligation with/without stripping**

**Scientific evidence.** It has been reported that surgical treatment of varicose veins is superior to conservative management. In the REACTIV trial,<sup>419</sup> the results of surgery were compared with results of compression alone in 246 patients with uncomplicated varicose veins, the surgical treatment comprising high ligation/stripping (HL/S) of the GSV and multiple phlebectomies.<sup>420</sup> At 2-year follow up the results showed more symptomatic relief, better cosmetic results, and much improved QoL for surgery compared with conservative management by compression.

In a prospective cohort study, 203 consecutive patients who underwent varicose vein surgery were monitored, and reported an improvement in QoL 2 years after surgery, with a significant improvement in the health related AVVQ score and the SF-36 score.<sup>421</sup> In addition, improvement in QoL from varicose vein surgery has been shown to be statistically significant and clinically relevant.<sup>422</sup>

Comparative studies relating to traditional surgical treatment compare isolated HL and HL/S.<sup>423–426</sup> In a randomized trial in 100 patients and 133 legs, HL was compared with HL/S.<sup>424</sup> The need for reoperation was 6% in

patients who underwent HL/S versus 20% in those patients who underwent HL alone ( $p < .02$ ). In another study it was shown that the HL group and the sclerotherapy group with intention to close the GSV, had significantly higher recurrence rates than HL/S at 4 years.<sup>425</sup> Cosmetic results, both judged by the patient and the surgeon, were significantly better ( $p < .05$ ) in the stripped limbs than in the limbs with HL and sclerotherapy.<sup>426</sup> They also found that CW Doppler evidence of reflux of the saphenous vein was less frequent ( $p < 0.001$ ) after the stripping operation. Better results after aggressive and extensive surgical treatment of the refluxing veins and the sources of the reflux were reported. A randomized trial showed a significant reduction of risk of re-operation in a HL/S group compared with a HL alone group at 11 years of follow up, even if there was no difference for the rate of visible recurrent veins.<sup>423</sup>

In a RCT it was shown that patients in whom the stump of the GSV had been invaginated with a non-absorbable suture, had less neovascularization in comparison with those who had the endothelium of the stump exposed.<sup>427</sup> According to a single centre prospective cohort study, interposition of an anatomical barrier, by closing the cribriform fascia after SFJ ligation, also reduced ultrasound detected neovascularization at the SFJ after 1 year.<sup>428</sup> In a RCT of 389 limbs by van Rij, polytetrafluoroethylene (PTFE) patch coverage of the SFJ created a significant reduction of recurrence at 3 year follow up by reducing neovascularization at the groin.<sup>120</sup> The potential benefit of inserting a PTFE patch in recurrent varicose vein operations could not be proven in another small RCT.<sup>429</sup>

Traditional HL/S has evolved towards a less invasive technique by invagination under tumescent local anaesthesia, giving post-operative results as good as endovenous ablation techniques or foam sclerotherapy in terms of

haematoma, pain, and QoL as shown by Rasmussen in a randomized control study.<sup>328</sup> A non-comparative prospective study showed that the use of isotonic sodium bicarbonate as excipient for tumescent anaesthesia reduced intra-operative pain and improved cost-effectiveness of surgery.<sup>430</sup>

As endovenous procedures have shown good results without HL, stripping of the saphenous vein has also been described without HL. A retrospective study showed that stripping of the GSV without HL led to low neovascularization and SFJ reflux rates at 3 year follow up (0.9% and 1.8%, respectively).<sup>431</sup> In a RCT at 8 year follow up, a group treated by stripping without HL had significantly less recurrence than a group treated by HL/S (9.8% vs. 29%,  $p = .014$ ).<sup>432</sup>

Several RCTs have been performed comparing HL/s with endovenous techniques (EVLA, RFA, foam sclerotherapy). Among them, Rasmussen published a four arm RCT comparing HL/S under tumescent local anaesthesia by invagination stripping with EVLA, RFA, and foam sclerotherapy. The results showed that the post-operative average pain scores at 10 days were significantly lower in the groups treated with RFA and foam sclerotherapy compared with HL/S and EVLA, with a shorter time to resumption of normal activities and work. But the VCSS, the AVVQ scores, and the clinical recurrence were not different between HL/S and the other treatments at 3 years. The conclusion was that beyond a higher pain score in the post-operative period and a higher total cost for HL/S and EVLA, the efficiency of the four modalities was not significantly different.<sup>433</sup>

There is no evidence in the literature for continuing indications for HL/S, unless there is lack of availability of the endovenous techniques for financial or other reasons. On the other hand, HL/S is not inferior compared with the new modalities of treatment in the mid term.

Recommendation 46	Class	Level	References
For non-complicated varicose veins (C2, C3), surgical treatment is recommended instead of conservative management, to improve symptoms, cosmetics, and quality of life.	I	B	420, 421, 434
<b>Recommendation 47</b>			
In cases in which surgical treatment of the refluxing saphenous vein is performed, high ligation and stripping is recommended instead of high ligation only.	I	A	423-426
<b>Recommendation 48</b>			
Surgical stripping of the saphenous vein without high ligation leaving a 2 cm stump may be considered.	IIb	B	431, 432
<b>Recommendation 49</b>			
If high ligation is performed, oversewing the great saphenous vein stump, interposition of a polytetrafluoroethylene patch, or closure of the cribriform fascia may be considered, in order to reduce the effect of neovascularization at the saphenofemoral junction.	IIb	B	120, 427, 428
<b>Recommendation 50</b>			
The use of tumescent anaesthesia should be considered for surgical treatment of great saphenous vein reflux to reduce post-operative side effects.	IIa	C	328, 430

#### 4.8.2. Phlebectomy

**Scientific evidence.** The technique of ambulatory phlebectomy (AP; stab or hook or mini-phlebectomy) was described by Muller in 1966 with removal or avulsion of varicose veins through small incisions performed with hooks and forceps.<sup>15</sup> Numerous authors have reported that ambulatory phlebectomy is a safe and immediately effective procedure for the treatment of varicose veins,<sup>315,434–438</sup> which can be done under local anaesthesia in an office based setting.

Phlebectomy can be considered as an adjunctive treatment in association with stripping or endovenous ablation of the main refluxing truncal vein,<sup>439–442</sup> or as the exclusive procedure for the treatment of varicose veins.<sup>15,315,435,443,444</sup>

A randomized study showed that ambulatory phlebectomy compared with liquid sclerotherapy plus compression for accessory vein incompetence caused significantly fewer recurrences at 1 and 2 years of follow up (respectively, 1/48 vs. 12/48 and 1/48 vs. 18/48  $p < .001$ ).<sup>315</sup>

Some publications advocate limiting the treatment to thermal ablation of the SV without treating the tributary varicose veins.<sup>445,446</sup> According to these papers, secondary treatment (foam sclerotherapy, phlebectomy, stripping) for residual varicose veins was only necessary in 17–62.5% after a short follow up period (3–9 months). On the contrary, another prospective study in 67 patients showed that the performance of concomitantly performed phlebectomy with an EVLA of the saphenous vein obviates the need for subsequent procedures.<sup>447</sup> The authors found that an additional treatment by sclerotherapy or by phlebectomy was performed in only 4% and 1% at 1 and 12 weeks. In a randomized study of 50 patients between EVLA alone and EVLA with concomitant ambulatory phlebectomy (EVLA/AP), it was shown that at 3 months in the EVLA/AP group the requirement for a secondary procedure was less common (1/25 vs. 16/24,  $p < .001$ ), the VCSS was lower (0(0 + 1) vs. 2 (0–2),  $p < .001$ ), and the AVVQ score was better (7.9 vs. 13.5  $p < .001$ ).<sup>448</sup>

intrafascial saphenous vein, leading to decompensation of the saphenous vein wall, moving on to eventually reach the saphenofemoral or saphenopopliteal junction.

**Scientific evidence.** The theory for the development of varicose veins is historically based on the descending theory. Anatomical, DUS examination, and morphological information confirmed the theory that the reflux begins at the saphenous junctions and progresses downwards through the saphenous axis leading to venous hypertension, wall dilatation, and dilatation of tributaries which become varicose veins. Cotton reported in an anatomical study that normal veins have a significantly higher number of valves than varicose veins.<sup>90</sup> Cooper assessed in a retrospective analysis of venous DUS examinations that the incompetence of the SFJ has a major influence on the extension of the reflux and that the venous incompetence was most commonly proximal in presence of varicose veins.<sup>449</sup> Takase described numerous alterations in structure of valves induced by venous hypertension in association with varicose veins.<sup>450</sup>

However, numerous publications challenge the theory of descending disease progression, citing the possibility of local or multifocal early distal evolution, sometimes ascending or antegrade, based on precise and detailed DUS investigations.<sup>49,431,451–456</sup> The fact that the terminal valve at the SFJ is frequently competent (in >50% of cases) in the presence of truncal reflux has been clearly proven.<sup>449,457–459</sup>

The disappearance of reflux in the GSV following phlebectomy<sup>460–463</sup> or after thermal ablation of an incompetent tributary<sup>464</sup> has been reported in the literature. Quill and Fegan also found such reversibility of the saphenous reflux following sclerotherapy.<sup>465</sup> The diameter of the GSV was observed to be reduced after ablating a refluxing tributary.<sup>466</sup>

In addition, the evolution of CVD, whether ascending or descending, remains largely unknown, as prospective longitudinal studies with a lengthy period of observation and a large sample size, are missing and RCTs are needed.

Recommendation 51	Class	Level	References
When performing endovenous thermal ablation of a refluxing saphenous trunk, adding concomitant phlebectomies should be considered.	IIa	B	447, 448
<b>Recommendation 52</b>			
To treat tributary varicose veins, ambulatory phlebectomy should be considered.	IIa	C	15, 434–437, 443, 444

#### 4.8.3. Ambulatory Selective Varices Ablation under Local anaesthesia

**Introduction.** The Ambulatory Selective Varices Ablation under Local anaesthesia (ASVAL) method, consisting of single phlebectomies with preservation of the saphenous trunk, is based on the concept of ascending or multifocal evolution of varicose veins. According to this pathophysiological concept, progression of the disease could begin in subcuticular veins, outside the saphenous compartment, creating a dilated and refluxing venous network. When this refluxing network becomes large enough, it could create a “filling” effect in the

A retrospective cohort of 303 limbs treated by ASVAL reported complete abolition of the saphenous reflux after 1, 2, 3, and 4 years in 69.2%, 68.7%, 68.0%, and 66.3% of cases, respectively, and reduction in SFJ vein diameter, marked symptom relief, and low recurrence rates.<sup>431</sup> In this study, the cohort of patients operated on with ASVAL was younger, more frequently asymptomatic, with a less extensive reflux, and lower average diameter of the SFJ compared with the patients who underwent stripping during the same period of time.

In a prospective study including 94 patients with large varicose tributaries and GSV reflux assessed by DUS

examination, single phlebectomies led to abolition of the GSV reflux in 50% of the cases, with a significant reduction of the GSV diameter and a significant improvement of the AVVQ score.<sup>467</sup>

#### 4.8.5. Powered phlebectomy

**Introduction.** Transilluminated powered phlebectomy (TIPP) consists of removal of large varicose vein clusters, with a decrease in the number of incisions needed and a faster

Recommendation 53	Class	Level	References
In selected patients, with less evolved varicose veins (C2-C3), single phlebectomies with preservation of the saphenous trunk should be considered.	Ila	B	431, 463, 467

#### 4.8.4. Cure conservatrice et Hémodynamique de l'Insuffisance Veineuse en Ambulatoire (CHIVA)

**Introduction.** CHIVA was described by Franceschi in 1988. It aims to improve the haemodynamics of the superficial venous network by splitting the column of hydrostatic pressure and disconnecting venovenous shunts by interrupting the incompetent trunks at strategic levels (SFJ, perforating veins) depending on a precise pre-operative DUS examination, to obtain a well-drained superficial venous system with low pressure and high flow.

**Scientific evidence.** One RCT, concerned with treatment of venous ulcers, showed that the group treated by CHIVA had a similar healing rate (100% vs. 96%) and a lower recurrence rate (9% vs. 38%) at 3 years follow up than the group treated by compression.<sup>468</sup>

The clinical and DUS recurrence of varicose veins was studied in two RCTs: the results were in favour of CHIVA versus HL/S in both studies, 8% vs. 35% ( $p < .004$ ) at 10 year follow up in one study<sup>469</sup> and 31.1% vs. 52.7% ( $p < .001$ ) at 5 year follow up in the other.<sup>470</sup>

Some observations must be noted: in the paper by Carandina, there is an important bias concerning the randomization and follow up.<sup>469</sup> In another study all stripping procedures were done under general or epidural anaesthesia whereas the CHIVA treatments were performed under local anaesthesia, which acted as a confounder for the evaluation of the post-operative side effects.<sup>470</sup> The most serious limiting concerns in both studies were how "failure" by recurrence was defined: it is unclear if the presence of visible recurrent varicose veins or the presence of refluxing veins during the DUS evaluation or both were considered to define the failure of the treatment.

performance of the procedure, often combined with saphenous vein ablation procedures or HL/S.

**Scientific evidence.** A published series of 114 patients, in a prospective, non-comparative, multicentre, pilot study reported the safety and efficacy of TIPP.<sup>471</sup> The patients, an independent nurse, and the surgeon subjectively scored the evaluation of outcomes in this study.

Other authors have stated in observational studies that a learning curve exists to minimize bruising and that other local complications may vary.<sup>472–474</sup> Complications observed include haematoma (4.9–95%), paresthesias and nerve injury (9.5–39%), skin perforation (1.2–5%), superficial phlebitis (2.4–13%), swelling (5–17.5%), and hyperpigmentation (1.2–3.3%).<sup>475,476</sup>

More recently, a new system with important technical modifications (lower oscillation frequency, larger volume of tumescence, dermal drainage, flushing of hematoma, and residual tissue fragments), has improved the results of TIPP with a lower rate of complications.<sup>477</sup>

A limited number of studies with many limitations (pilot study, non-randomized, observational) have been published and clearly lack data to show a significant advantage of TIPP over phlebectomy. It seems that the newer generation system and modified technique enable TIPP to be less invasive. Further studies are required to confirm the potential benefits of TIPP.

#### 4.9. Treatment of deep vein pathology

**Introduction.** Annually one to two adults per 1,000 in the Western population develop a DVT of the lower extremity. Treatments using low molecular weight heparin (LMWH) or unfractionated heparin and vitamin K antagonists in the acute phase will not be discussed here. Despite adequate

Recommendation 54	Class	Level	References
Ambulatory conservative hemodynamic treatment of venous incompetence (Cure Conservatrice et Hémodynamique de l'Insuffisance Veineuse en Ambulatoire, CHIVA) may be considered in patients with chronic venous disease, if performed by physicians exclusively performing CHIVA.	Iib	B	468-470

Recommendation 55	Class	Level	References
Transilluminated powered phlebectomy (using a low oscillation speed and a large volume of tumescence) may be considered as an alternative to phlebectomy, to reduce the number of incisions.	Iib	C	477



treatment according to this regimen, residual venous lesions occur in a substantial number of these patients (20–50%). The incidence of residual lesions is greater after a recurrent DVT in the ipsilateral leg aggravating venous hypertension because of deep venous obstruction and valvular incompetence. The effect of this is the development of oedema and dysfunction of the (micro)circulation, which can lead to the clinical characteristics of post-thrombotic syndrome (PTS). Also in well or partially recanalized veins, residual venous obstruction may be important, because the scarred venous outflow causes increased outflow resistance, especially during and after activity. As a result of chronic venous obstruction, collaterals develop, which partly take over the outflow capacity of the thrombosed venous segments. However, these collaterals often feature a relatively low outflow capacity, and are mainly used when venous pressure rises significantly. These collaterals are clinically visible at the level of the thigh, lower abdomen, and pubis. Less commonly, the cause of obstruction is extrinsic compression on the vein, for example by a malignant tumour. There are also specific iliac vein compression syndromes caused by non-thrombotic iliac vein lesions (NIVL) such as May-Thurner syndrome, in which the left common iliac vein is compressed between the right iliac artery and the spine. There are several forms of congenital deep venous anomalies causing obstruction of the outflow tract. One severe anomaly is atresia (congenital absence) of the IVC in which the sub-hepatic segment of the IVC has not developed. This may cause CVD because of outflow obstruction, often complicated by recurrent ilio-femoral DVT and subsequent post-thrombotic problems.<sup>478</sup>

In patients who have suffered from extensive DVT, apart from residual venous obstruction, deep venous reflux may occur, secondary to valvular damage. However, deep venous reflux can also be induced by a very important proximal outflow obstruction, causing dilatation of the deep veins in the leg, and eventually failure of the valves to close completely. The increased hydrostatic pressure leads to venous hypertension, damage of the microcirculation, and symptoms and signs of CVD. In some patients there may be a congenital hypo- or aplasia of valves in the deep venous system. This form of deep venous reflux is very rare.

The current standard treatment for symptoms and signs of chronic venous obstruction or deep venous reflux is compression therapy. However, its effectiveness may be suboptimal in selected cases, especially when compression therapy has limited effect on venous symptoms or the compliance is poor.

#### 4.9.1. Treatment of chronic deep venous obstruction

This can be performed either by percutaneous transluminal angioplasty (PTA) and stenting, or by surgical correction, usually bypass.

**4.9.1.1. Percutaneous transluminal angioplasty and stenting. Introduction.** The endovenous treatment of ilio-caval obstruction includes traversing the obstruction with a guide wire (occlusions need to be recanalized, i.e., a new lumen

created), followed by placement of a stent to cover the obstructed vein segment. Self-expandable stents should be used in the veins, ideally with a high radial force and sufficient flexibility. The aim is for the stent to support the vein wall and prevent recoil/collapse, and thereby to maintain patency in the long-term. The largest longer term experience reported from multiple centres utilizes a braided stent made of elgiloy (main content cobalt, chromium and nickel). Although clinical results are favourable, these stents have potential design inherited disadvantages, mainly foreshortening and rigidity, and could possibly be improved. Recently, dedicated venous stents of nitinol (nickel and titanium) have therefore been designed to specifically treat venous obstructions with these disadvantages in mind. Nitinol is commonly used in the arterial system and is known for its superelasticity and shape memory (recovers its designed form at body temperature). Clinical results using dedicated venous stents and comparison between different types of stent are lacking. The optimal design and material of a venous stent is presently not known.

In the arterial system, in most cases it is sufficient to use PTA alone. In the venous system, PTA must always be complemented by a stent placement to avoid collapse of the vein.<sup>26,479,480</sup>

**Scientific evidence.** Sixteen articles have been identified related to PTA and stenting.<sup>479–494</sup> Fifteen articles are non-comparative in nature, with only four studies having a prospective design. The methodology is generally moderately clearly described and follow up varies from 2 to 144 months. Often there is no Kaplan-Meier survival analysis performed to assess patency rates; however, some studies with longer follow up report Kaplan-Meier data. Potential confounding factors related to clinical outcome are often not described, frequently additional treatment of the superficial system is performed during follow up. One study is a retrospective, comparative study.<sup>482</sup> This study has a large proportion of C6 patients, particularly in the intervention group, with a short follow up. There is a possible selection bias, as the inclusion and exclusion criteria are poorly described and it is not clear why patients are included in either the intervention or control groups.

In seven studies with a total of 426 legs there was NIVL, often May-Thurner syndrome, and post-thrombotic pathology present.<sup>479,480,482,483,489,492</sup> Technical success was achieved in 87–100% of cases, with an average follow up of 45 months (range 4–120 months). Primary\* patency was 78% (59–94%), assisted primary patency\*\* 83% (63–90%), and secondary patency\*\*\* 93% (72–100%). Ulcer healing rates ranged from 47% to 100%,<sup>479,482,483,487,492</sup> with 8% to 17% ulcer recurrence rates; patients with patent reconstruction performed generally better.<sup>479,487</sup> Reduction of pain was observed in 48% of the patients and 61% showed reduction of oedema.<sup>490</sup> In four studies, with a total of 1,000 lower extremities, NIVL was specifically assessed.<sup>484,485,487,493</sup> Technical success was achieved in 96–100% of cases, with a follow up of 59 months (6–72 months). Primary\* patency was 85% (79–99%), and assisted primary\*\* and secondary

patencies\*\*\* were 100%. Rates of ulcer healing ranged from 82% to 85%,<sup>485,493</sup> with 5% to 8% recurrence.<sup>485,487</sup> There was statistically significant improvement at all points of the CIVIQ,<sup>487</sup> and in the VAS and QoL scores.<sup>487,493</sup> Oedema decreased in 32% to 89% of cases,<sup>485,487,493</sup> and hyperpigmentation improved in 87%.<sup>485</sup>

In six studies with a total of 921 legs, secondary (post-thrombotic) obstruction was specifically examined.<sup>481,486–488,490,491</sup> Technical success was achieved in 93–100% of cases, with a mean follow up of 46 months (2–72 months). Primary patency\* was 57% (50–80%), assisted primary patency\*\* 80% (76–82%), and secondary patency\*\*\* 86% (82–90%). Ulcer healing ranged from 63% to 67%,<sup>486,490</sup> with 0 to 8% recurrence.<sup>487,490</sup> There was statistically significant improvement at all points of the CIVIQ<sup>487</sup> and VCSS<sup>491</sup> scores. Oedema decreased in 32–51% of cases.<sup>486,487,490</sup>

\* Primary patency: the vein is open without any additional intervention.

\*\* Assisted primary patency: the vein is patent, but an additional intervention was needed to keep the vein patent.

\*\*\* Secondary patency: the vein is patent after one or more additional interventions were required to treat an occlusion of the vein.

Stent placement is safe with low mortality and morbidity. Stents in the external iliac vein may cross the inguinal ligament to “land” in the common femoral vein. It has been shown that in two thirds of patients with post-thrombotic disease it is necessary to implant stents down to the groin below the inguinal ligament to improve inflow into the reconstructed iliac veins.<sup>487,491</sup> Interventions distal to the groin, including endophlebectomy or stenting further down into the femoral vein or profunda femoral vein are not yet validated.

**4.9.1.2. Open bypass procedures. Scientific evidence.** Two studies from the same institution were identified, with

different types of surgical bypasses, that is femoro-femoral bypass (Palma procedure, using GSV or polytetrafluoroethylene bypass), femoro-iliac-inferior vena cava bypass, spiral vein grafts, and femoral vein patch angioplasty.<sup>495,496</sup> The most recent report also includes the data of the first publication and data about hybrid reconstructions (endophlebectomy, patch angioplasty, stenting).<sup>495</sup> Both studies are retrospective in nature and often include patients who have already had previous venous interventions, which are not clearly described. A second problem with these studies is that different procedures were performed. Results are not always entirely clear, although Kaplan-Meier analyses were calculated. In these studies with a total of 110 legs and a follow up of 31 to 41 months, there was 89% technical success.<sup>495</sup> Primary patency of 42% and secondary patency of 56% were achieved at 60 months. Ulcer healing was not registered.

AbuRahma reported a low clinical success and primary patency rate for saphenopopliteal venovenous bypasses (May-Husni procedures) of 56% after 66 months.<sup>497</sup>

New externally reinforced, ringed, grafts with large diameters and coating may affect future results in a positive fashion. Selectively constructing an AV-fistula may also influence patency positively.

**4.9.2. Treatment of deep venous incompetence**

**Introduction.** Deep venous incompetence can be divided into primary and secondary forms. In primary incompetence, the structure of the valve sometimes remains intact and is therefore suitable for external or internal repair (valvuloplasty). More commonly there is valvular incompetence caused by DVT. This secondary, post-thrombotic incompetence is caused by a destruction of the valve as a result of the inflammatory response in the thrombus, vein wall, and valve. There are two options for reconstruction. One is to replace the affected valve by transposition or transplantation of a vein segment containing a valve; the second is to create a neovalve from the thickened vein wall.

Recommendation 56	Class	Level	References
In patients with clinically relevant chronic ilio-caval or ilio-femoral obstruction or in patients with symptomatic non-thrombotic iliac vein lesions, percutaneous transluminal angioplasty and stent placement using large self expanding stents should be considered.	IIa	B	479-483, 485-494
<b>Recommendation 57</b>			
Percutaneous transluminal angioplasty is not recommended as a single treatment for patients with chronic deep venous obstruction.	III	C	26, 479, 480
<b>Recommendation 58</b>			
After percutaneous transluminal angioplasty stent placement should be considered for patients with chronic deep venous obstruction.	IIa	C	479-483, 485-494

Recommendation 59	Class	Level	References
In patients with deep venous obstruction bypass, surgery is not recommended as standard primary treatment.	III	C	495-497

**Scientific evidence.** A total of 24 articles were identified that describe the non-conservative treatment of deep venous reflux.<sup>498–520</sup> There were 19 retrospective, one prospective case series, and four prospective cohort studies. In addition, one meta-analysis<sup>520</sup> was performed. A wide variety of surgical techniques were described, including: internal valvuloplasty, external valvuloplasty, valvuloplasty through external “banding”, creation of a new valve from the local vessel wall (“neovalve”), transposition of the incompetent vein on to a competent vein, trans-

Most patients with deep venous incompetence can be treated with conservative measures alone. A surgical correction is indicated only when, despite the use of adequate compression therapy and a strict adherence to lifestyle advice, severe symptoms persist, such as leg ulcers. Surgical repair of deep venous incompetence cannot be considered as a replacement therapy, but it is performed in addition to conservative measures and surgical treatment of superficial venous incompetence, and, if necessary, perforating vein incompetence.

Recommendation 60	Class	Level	References
Deep venous obstruction should be treated first, before considering treatment of deep venous reflux.	I	C	513
<b>Recommendation 61</b>			
In the absence of deep venous obstruction and after abolition of superficial venous reflux, surgical correction of deep venous axial reflux (proven by duplex ultrasound and descending venography) may be considered in patients with severe and persistent symptoms and signs of chronic venous disease.	IIb	C	498-504, 506-520
<b>Recommendation 62</b>			
Surgical treatment of patients with deep venous reflux, but without severe clinical symptoms and signs of chronic venous disease, is not recommended.	III	C	

plantation of an autologous valve bearing vein segment to an incompetent vein in the leg, and other less common techniques of valve repair. Often, these operations were combined with surgical treatment of incompetent superficial or perforating veins during or just before or after deep venous surgery, which makes the interpretation of the results rather difficult. In general, very heterogeneous populations, often with only small patient numbers (between 20 and 50), were described or patient history and demographics were simply not mentioned. Outcome measures used were heterogenous. In conclusion, it can be stated that the durability of all of these techniques cannot be derived from the available literature.

**Summary.** In general, good short-term results are described in all the above mentioned studies for all techniques. Technical success of the operation is close to 100%, when it is described. Competence of the replaced or repaired valve during follow up is variable between 35% and 100% at a follow up of up to 144 months.<sup>498–520</sup> There seems to be a trend in the literature, that valvuloplasty and creating a neovalve leads to better results than transposition or valve transplantation. Success rates of 70% are reported after valvuloplasty in primary incompetence versus 50% after transposition or transplantation in post-thrombotic patients at 60 months.<sup>521</sup> Overall, ulcer healing varies between 54% and 100% up to 5 years.

As no comparative studies have been performed, it is not possible to indicate which valve (re)construction techniques or other invasive treatments should be performed and at what timing, in patients with deep venous incompetence.

In addition to all invasive treatment options, compression therapy is mandatory, presumably lifelong. Patients with post-thrombotic changes may continue to suffer from venous reflux (e.g. calf veins) and/or obstruction. Compression therapy improves venous outflow and may enhance the patency of the reconstruction.

Therapeutic anticoagulation (AC) with coumadins or LMWH is necessary after PTA and stenting, at least for patients with chronic obstruction after DVT. The duration of AC is unclear and should last at least 3 months. Some authors recommend lifelong AC. LMWH and antiplatelet drugs are recommended by some authors for treatment after PTA and stenting of the deep venous system in NIVL patients.

## CHAPTER 5: RECURRENT VARICOSE VEINS

### Introduction

Varicose vein recurrence following surgical intervention is a common problem for both patients and clinicians. Whether after open surgery or endovenous intervention, mid-term recurrence rates remain in the region of up to 35% at 2 year follow up, and 65% at 11 year follow up.<sup>423,522–524</sup>

According to an international consensus meeting held on recurrent varices after surgery (REVAS), the definition of recurrent varicose veins is as follows: “the existence of varicose veins in a lower limb previously operated on for varicosities, with or without adjuvant therapies, which includes true recurrences, residual veins and new varices, as a result of disease progression.”<sup>107,525,526</sup>

In the more recently published “Vein Term Update,” a new acronym has been introduced to describe both

recurrent varices (i.e. those presenting de novo in an area previously treated successfully) and residual varices (i.e. those remaining after treatment).<sup>1</sup> PREVAIT stands for PREsence of Varices (residual or recurrent) after InTervention and defines recurrent varicosities following both surgery and endovenous intervention (thermal, ultrasound guided foam sclerotherapy [UGFS]).

Recurrence can be classified according to clinical criteria and duplex ultrasound (DUS) examination. Clinical recurrence has to be further defined by DUS examination.

### 5.1. Etiology

The etiology of recurrent varicose veins is still poorly understood. It was originally thought that these were largely tactical and technical errors resulting from poorly planned or completed procedures.<sup>107,168</sup> There is, however, evidence suggesting that factors such as neovascularization may be involved in recurrence.<sup>167,524,527</sup>

The sources of reflux feeding recurrent varicosities, assessed by venous DUS, can be multiple, but have been reported most commonly at the SFJ.<sup>107</sup> A multicentre study identified incompetence at the level of the junction in 47% of their patients: 10% had no identifiable source of reflux; 75% of legs assessed had incompetent perforator veins, whereas in 17% it was of pelvic or abdominal origin.

Pelvic vein reflux has been identified as an important contributing factor to varicose vein recurrence.<sup>528</sup> It is particularly common in multiparous women, having been reported in 44% of parous and 5% of nulliparous asymptomatic women.<sup>529</sup> Pregnancy increases blood volume and causes compression of the pelvic veins secondary to the gravid uterus, resulting in pelvic vein incompetence.<sup>530</sup> In addition to mechanical compression, hormonal effects may also be implicated in the development of varicose veins in pregnancy, with both oestrogen and progesterone receptors present in normal and varicose vein walls.<sup>531–533</sup> Venous obstruction, secondary to DVT, or direct compression, secondary to pelvic pathology, may also contribute to varicose vein recurrence.

A prospective study of 113 limbs identified four main causes of recurrence (Table 13).<sup>166</sup>

**Tactical error.** Tactical error refers to errors in pre-operative planning. This includes erroneous identification of the refluxing segment. With the advent of improved pre-operative imaging in the form of venous DUS examination and with minimally invasive ultrasound guided techniques providing targeted treatment, human error should play a lesser part in the development of recurrence.<sup>534</sup> Pre-operative DUS imaging has been shown to improve the results of varicose vein surgery, based on correct identification of incompetence in the GSV, AASV, and/or SSV system.<sup>534</sup> Tactical errors also include decisions regarding the surgical approach by the treating physician that may result in recurrence.

There is evidence that stripping or ablating the GSV, as opposed to performing high ligation only, results in reduced recurrence rates. A randomized trial of SFJ ligation ± GSV stripping revealed recurrence rates at 2 years of 43% in the ligation group and 25% in the ligation + stripping group.<sup>522</sup>

**Table 13.** Causes of recurrent varicose veins (least to most common).

Tactical error — 4%	Persistent venous reflux in a saphenous vein secondary to inadequate preoperative evaluation and inappropriate surgery
Technical error — 5.3%	Persistent venous reflux due to inadequate or incomplete surgical technique
Neovascularisation — 13%	Presence of reflux in a previously ligated SFJ or SPJ caused by development of incompetent tortuous veins linked to thigh (or calf) varicosities
Disease progression — 15%	Development of venous reflux secondary to the natural evolution of the disease

In endovenous intervention, the persistence of a below knee refluxing GSV segment (i.e. ablation of the above knee segment only) was found to be associated with recurrence, reflux, and the need for further intervention.<sup>535</sup> However, the increased risk of paraesthesiae and saphenous nerve damage following treatment of the below knee GSV should be taken into account.<sup>536</sup>

When planning intervention in CVD, it is of paramount importance to carefully discuss the risks and benefits of each option with the patient.

**Technical error.** Technical error refers to inaccurate treatment at the time of surgery or endovenous intervention. This may be related to poor access, poor visualization of the target vein segment and the SFJ or SPJ (in ultrasound guided endovenous procedures), or inexperience.

Historically, a lack of experience by the operating surgeon has been blamed for high recurrence rates. However, there is evidence against this, suggesting that human, or technical error, plays a lesser role in the development of recurrence compared with neovascularization and disease progression.<sup>166,537</sup>

**Neovascularization.** Neovascularization refers to the formation of new veins, typically at the site of the previous ligation of the GSV or SSV. This results in reconnection of the deep vein with a residual main saphenous trunk (if not stripped) or with superficial tributaries, eventually resulting in clinical recurrence.<sup>538</sup> After GSV stripping, revascularization of the saphenectomy track has been observed, seen as multiple tortuous venous channels in the track of the previously stripped GSV.<sup>539</sup>

On DUS examination, neovascularization is visualized as a network of complex, tortuous vessels, connecting the end, or stump, of the GSV or SSV to a tributary in the thigh or calf.<sup>148,164</sup> It is important to note that different degrees of DUS-detected neovascularization exist; neovascularization is present in 25–94% of recurrent varicose veins.<sup>540,541</sup> However, assessment of neovascularization on DUS examination can be challenging.

The mechanism for the development of angiogenesis and neovascularization is still unclear.<sup>524</sup> Mediators such as growth factors (e.g. vascular endothelial growth factor), matrix metalloproteinases, and angiotensin are involved.<sup>164</sup> A number of theories have been postulated to explain why neovascularization develops post-operatively. It may be part of the physiological healing process after venous surgery. In the track where the original vein was stripped, the post-operative haematoma may organize, with development of capillaries, venules, and finally tortuous recurrent veins. Altered venous haemodynamics may lead to its development. Or finally, it may be a physiological response to venous disconnection.

Either way, neovascularization has been found to account for a considerable proportion of recurrences and there is evidence suggesting it plays a greater role in open surgery than in endovenous therapy.<sup>166</sup> DUS examination detected neovascularization in 18% of the surgery group and 1% of the Endovenous Laser Ablation (EVLA) group, while clinical recurrence rates were similar.<sup>167</sup>

However, the presence of DUS detected recurrence does not necessarily mean a new intervention is needed. The rate of re-operation following varicose vein surgery was shown to vary according to the nature of the recurrence.<sup>534</sup> DUS detected neovascularization seldom required re-intervention, whereas patients with recurrent or residual varicose veins because of tactical or technical failure had more re-operations during a follow up period of 7 years.

**Disease progression.** Disease progression accounts for a large proportion of recurrences.<sup>166</sup> The progression may be multifocal, ascending, or descending. According to the ascending pathophysiological principle, superficial veins may dilate and become varicose over time. According to the descending principle, ongoing reflux at the SFJ or SPJ and/or saphenous trunks may cause superficial tributaries to dilate and become varicose. As a result of disease progression, incompetence can also develop in a previously untreated saphenous trunk, for instance in the SSV, after previous treatment of the GSV, or in perforating veins.

Recurrent varicose veins remain a poorly understood entity with several proposed etiologic factors. Their incidence and severity may be related to the original treatment modality; however, disease progression may also play a major role. Further studies are required to increase

understanding of their development at a molecular level to enable the development of effective prevention and treatment strategies for recurrent varicose veins.

### 5.2. Risk factors

In addition to the aforementioned four factors, there is evidence suggesting that the original intervention has an impact on the likelihood of recurrence, although recurrence rates are largely comparable among treatment modalities.<sup>166,542</sup>

### 5.3. Diagnosis of recurrent varicose veins

DUS is the preferred diagnostic approach to investigate recurrent varicose veins (see 3.2.3.3).

### 5.4. Treatment of recurrent varicose veins

The management of recurrent varicose veins is a challenge for the clinician. Repeated intervention is associated with reduced patient satisfaction.<sup>166,543,544</sup> Therefore, a less invasive approach, consisting of multiple phlebectomies or alternative techniques, has been advocated to replace invasive redo surgery including re-exploration of the groin or popliteal fossa.<sup>545,546</sup> Extensive redo surgery should be performed only in selected cases.

RFA and EVLA have been described as safe and effective options for treatment of recurrent varicose veins.<sup>377,547,548</sup> The pattern of reflux feeding the recurrence can be from multiple origins, and the SFJ is often involved as a source.<sup>107</sup> Recurrence may also be secondary to incompetent perforators or pelvic vein incompetence. If a truncal vein segment is involved, this may be suitable for endovenous ablation, which may re-establish competence in previously incompetent perforating veins.<sup>547</sup> Ablation of the refluxing axial segment has been reported to re-establish competence in previously incompetent perforator veins.<sup>547</sup>

When compared with conventional surgery in the treatment of SSV recurrence, EVLA was found to have a higher technical success rate and lower complication rate, particularly with respect to sural nerve neuralgia (20% vs. 9%).<sup>549</sup> RFA was also found to be superior to redo groin surgery, with significantly lower pain scores, bruising, and procedure times.<sup>377</sup>

UGFS has also been used successfully in the treatment of recurrence,<sup>323</sup> although with lower success rates compared with laser ablation.

Recommendation 63	Class	Level	References
Endovenous thermal ablation, ultrasound guided foam sclerotherapy, or phlebectomies should be considered for the treatment of symptomatic recurrent varicose veins.	IIa	B	323, 377, 547-549
<b>Recommendation 64</b>			
Extensive redo surgery (including re-exploration of the groin or popliteal fossa) is not recommended as a first choice treatment in patients with recurrent varicose veins.	III	B	377, 545, 549

## CHAPTER 6: CONGENITAL VENOUS MALFORMATIONS

### Introduction

CVD describes visual and functional abnormalities in the peripheral venous system, affecting most commonly, but not exclusively, the lower limbs. Classification systems, such as the CEAP classification,<sup>109</sup> have been employed to differentiate between congenital, primary, secondary, and unknown causes of CVD.

Congenital vascular malformations (CVMs) are present in a very small proportion of patients. However, despite a limited incidence, the magnitude and severity of their clinical manifestations can be striking. Congenital venous malformations are disorders resulting from abnormalities in the development of the venous system. Depending on the developmental aberration, venous, arterial, and/or lymphatic channels may be involved, resulting in heterogeneous clinical presentations.<sup>550</sup>

In this chapter, the classification of CVMs is discussed, paying particular attention to congenital venous malformations, as well as syndromes affecting the venous system, such as Klippel-Trenaunay (KTS) and Parkes-Weber syndrome (PWS).

### 6.1. Pathophysiology

The pathophysiology of CVMs is unclear and may be secondary to sporadic mutations or a possible hereditary component, although familial inheritance is rare. CVMs are non-degenerative and non-inflammatory in origin and can appear anywhere in the body.

Development of the circulatory and lymphatic systems begins in the third gestational week, with the formation of peripheral and central blood islands from mesoblastic cells. In the first developmental stage, proliferation and fusion of these cells results in the creation of a primitive capillary network. This is followed by retiform and plexiform stages as the foetus develops. Ultimately, specific vessels enlarge to contribute to the definitive circulatory system, while others that are present only in the embryonic stages regress.<sup>550</sup>

Aberrant development at any of these stages can result in CVMs. Importantly, if this occurs during the primitive capillary stage, the abnormal embryonic vessels remain in the form of clusters and do not differentiate into definitive vessels.

Furthermore, they are separate from the main venous trunk and are therefore defined as extratruncular.<sup>550</sup> If the defect occurs at a later stage, it may lead to abnormalities in “named” vessels, with resulting hypoplasia, aplasia, obstruction, or dilatation. These are directly involved with the truncal venous system, and are therefore classified as truncular. This distinction is important in the classification of CVMs.

### 6.2. Classification

**Introduction.** CVMs are challenging to understand and define. A number of contributors have attempted to classify these lesions, aiming to develop a universal system to standardize their diagnosis and description, as well as to improve communication among specialists reporting in the literature. Different contributors have employed differing

**Table 14.** Haemangiomas and Vascular Malformations.

Haemangiomas
Vascular Malformations
- Capillary
- Venular
- Venous
- Lymphatic
- Arteriovenous
- Combined
○ Venous-lymphatic
○ Venous-venular

standards for their classifications, including embryological, anatomical, clinical, and haemodynamic criteria, resulting in heterogeneous classification systems.<sup>550</sup> The International Society for the Study of Vascular Anomalies (ISSVA) aims to further increase knowledge of the pathogenesis, diagnosis, and treatment of patients with CVMs. Among its roles is review of specific classification systems.<sup>551</sup>

#### 6.2.1. International Society for the Study of Vascular Anomalies classification

Mulliken and Glowacki first introduced a biological classification based on pathological characteristics of the endothelium and the natural course of the vascular lesion.<sup>552</sup> This system made the distinction between vascular tumours (of which haemangioma is the most common) and vascular malformations (Table 14).

This classification was redefined<sup>553</sup> and adopted by the ISSVA. Again, the distinction was made between haemangiomas and vascular malformations, which were subdivided into single system and combined lesions (e.g. arterial and/or venous, and/or lymphatic; Table 15).

#### 6.2.2. Hamburg classification

The Hamburg classification was developed in 1988<sup>554</sup> and approved by the ISSVA. This classification system described CVMs in terms of their anatomical and clinical characteristics (i.e. arterial, venous, shunt, or combined) and the embryological stage during which the malformation began to develop (truncular or extratruncular).

This classification system does not take into account haemangiomas or lymphatic malformations, but adequately describes lesions according to clinical and anatomical characteristics and facilitates communication between different specialties as a result of its descriptive nature (Table 16).

#### 6.2.3. Puig classification

A new classification system was also developed by Puig, describing the subgroup of venous malformations (VMs) in terms of their anatomical characteristics and pattern of venous drainage (Table 17).<sup>555</sup> The authors used this classification system as a basis for interventional therapy, particularly in assessing the suitability of paediatric patients for sclerotherapy.

### 6.3. Venous malformations

Venous malformations (VMs) are a subtype of CVMs. They have an estimated incidence of 1–2/10,000 births, a

Recommendation 65	Class	Level	References
The Modified Hamburg Classification system may be considered for the classification of vascular malformations.	IIB	B	<sup>554</sup>

prevalence of 1%, and are the most common type of CVM.<sup>556</sup>

**Etiology.** The majority of isolated VM's appear on a sporadic basis with no hereditary component,<sup>557</sup> although rare autosomal dominant conditions such as familial cutaneo-mucosal VM or glomuvenous malformation exist.<sup>556</sup>

**Clinical characteristics.** VMs may not be apparent from birth, developing in later childhood or adulthood. Often rapid growth occurs in puberty. The location of VMs is relatively equally distributed: 40% occur in the head and neck area, 40% in the extremities, and 20% in the trunk.<sup>558</sup>

VMs present as soft, compressible, blue-tinged masses that, like veins, may change in size according to position or expand with the Valsalva manoeuvre.<sup>558</sup> Superficial ecchymoses, teleangiectasiae or varicosities may be present. There is no evidence of pulsatility, thrill, raised temperature, or hyperaemia, differentiating them from arteriovenous malformations (AVMs). VMs are most commonly found in the skin and subcutaneous tissues; however, they can involve the

underlying muscle, bone, and viscera. If large in size, they may cause pressure effects on surrounding structures and planes, including bone, muscle, and subcutaneous tissue.

Importantly, VMs may be located intraorally and may cause bleeding, speech impediments, and airway obstruction. VMs are also at risk of thrombosis and there is evidence that the presence of VMs is associated with localized intravascular coagulopathic features.<sup>559</sup>

**Diagnosis.** DUS examination is the preferred initial imaging modality in the examination of VMs. It is safe, widely available, rapid, non-invasive, and low cost. Patients with VMs are young, so avoiding ionizing radiation is paramount. DUS allows differentiation between high flow (AVMs) and low flow (VMs, lymphatic malformations) CVMs. VMs are usually compressible, heterogeneous masses, and appear as hypoechoic, heterogeneous lesions in the majority of cases (82%). In a study of 51 soft tissue VMs, 16% had an identifiable pathognomonic phlebolith on DUS.<sup>560</sup>

VMs may be difficult to differentiate from adjacent fatty structures. Fat suppression techniques, such as inversion recovery sequences (Short Inversion Recovery, STIR), may be helpful in characterizing lesions.

CT is of limited use because it requires ionizing radiation and because of its poor lesion characterization, particularly in cases where the VM is deep and adjacent to underlying structures.<sup>556</sup> In addition, the use of contrast CT may underestimate the true lesion extent.<sup>558</sup>

MR imaging, with its superior soft tissue and lesion characterization, is the preferred imaging modality to define lesion extent and the relationship with adjacent

**Table 15.** Tumours and Vascular Malformations.

Tumours	
Haemangiomata	Superficial (capillary of strawberry) Deep (cavernous) Combined
Others	Kaposiform haemangioendothelioma Tufted angioma Haemangiopericytoma Spindle-cell haemangioendothelioma Glomangiomas Pyogenic granuloma Kaposi sarcoma Angiosarcoma
Vascular Malformations	
Single	Capillary (C) (port wine stain, naevus flammeus) Venous (V) Lymphatic (L) (lymphangioma, cystic hygroma) Arterial (A)
Combined	Arteriovenous fistula (AVF) Arteriovenous malformation (AVM) Capillary Lymphatic Venous Malformation (CLVM) [(associated with Klippel-Trenaunay Syndrome (KTS)) - Capillary Venous Malformations (CVM) - Lymphatic Venous Malformation (LVM) Capillary, arteriovenous malformation (CAVM) Capillary, lymphatico - arteriovenous malformation (CLAVM)

**Table 16.** Modified Hamburg Classification.

Type of defect	Truncular	Extratruncular
Predominantly arterial	Aplasia	Infiltrating
	Obstruction	Limited
	Dilation	
Predominantly venous	Aplasia	Infiltrating
	Obstruction	Limited
	Dilation	
Arteriovenous shunting	Superficial AV fistula	Infiltrating
	Deep AV fistula	Limited
Mixed defects	Arterial and venous	Infiltrating
	Haemolympathic	Limited

**Table 17.** Puig Classification.

Type I	Isolated malformation without peripheral drainage
Type II	Malformation that drains into normal veins
Type III	Malformation that drains into dilated veins/venous ectasia
Type IV	Malformation that represents dysplastic venous ectasia

structures.<sup>556</sup> Fat suppression techniques, such as inversion recovery sequences (Short inversion Time Inversion Recovery, STIR), may be particularly helpful in characterizing lesions difficult to differentiate from adjacent fatty structures.<sup>561</sup>

Direct percutaneous phlebography entails fine needle puncturing of the VM and contrast injection under fluoroscopy. It is the imaging modality of choice to diagnose VMs in situations where previous imaging has been equivocal<sup>556</sup> and is used during sclerotherapy procedures as an initial diagnostic evaluation.

### Management

The management of VMs involves a number of disciplines, including surgery, dermatology, medicine or paediatrics, and radiology. Clear communication between members of these disciplines and a true multidisciplinary approach are extremely important in the assessment and management of patients with VMs.

**Conservative.** VMs can be a chronic, non-life threatening condition with a potentially variable clinical picture. Mild symptoms are successfully managed with conservative measures, including limb elevation during sleep and avoidance of activities that may exacerbate symptoms. Patients can have localized intravascular coagulopathy, which may lead to thrombosis and paroxysmal pain.<sup>559</sup> Aspirin and prophylactic treatment with LMWH have been used in selected cases as an adjunct to conservative treatment,<sup>556</sup> while elastic compression garments have been employed to provide symptomatic relief.<sup>562</sup>

**Sclerotherapy.** The rationale for using sclerotherapy to treat VMs is the same as for treating varicose veins: to cause damage to the venous endothelium. A sclerosing agent (e.g. ethanol, sodium tetradecyl sulphate [STS] or polidocanol), in liquid form or aerated to produce foam, is directly delivered into the venous lumen via fine needle injection under image guidance (e.g. ultrasound, phlebography), allowing the agent to directly interact with the endothelium.<sup>556</sup>

QoL measures following sclerotherapy to VMs have revealed improved symptoms following therapy.<sup>563</sup> Patients with localized VMs did better than those with diffuse malformations affecting whole muscles or compartments.

The choice of sclerosant agent is an important variable in both the efficacy and complication rate profile of the different agents. A large series reporting the use of ethanol in 87 patients over 399 sessions has revealed initial success rates of 95%, with no recurrence at follow up (average 18.2 months).<sup>564</sup>

Minor and major complication rates were 12.4%: erythema, blistering, and localized skin ulceration or necrosis, as well as DVT and pulmonary embolism (reported in 1.25% and 0.25% of sessions, respectively) have all been reported.

Sodium tetradecyl sulphate (STS) has a more favourable side effect profile. A large series of 72 patients over 226 sessions revealed no major complications. Minor complications were present in approximately 3% of the sessions, including ulceration, skin necrosis, and transient sensory deficits.<sup>565</sup> According to this series, after treatment, 15% of

patients became asymptomatic, 28% rated the therapy as good, 24% were improved, 28% unchanged, and 5.6% felt worse. Again, patients with infiltrative lesions reported poorer outcomes than those with localized lesions.

Polidocanol has the lowest side effect profile, with pain and swelling being the most common complications.<sup>556</sup> A retrospective series of 19 patients with VMs found that, after treatment, patients reported a decrease in pain and significant reduction in the size of the lesion.<sup>566</sup>

A prospective study compared use of UGFS with ultrasound guided liquid sclerotherapy in treatment of symptomatic VMs. UGFS required a significantly smaller volume of sclerosant and had improved treatment outcomes compared with liquid sclerotherapy.<sup>567</sup>

**Surgical.** The decision to treat VMs surgically should be multidisciplinary. The main indications for treatment are persistent pain, functional impairment, or cosmetic implications in head and neck lesions, as well as location posing a realistic risk to the patient (e.g. lesions affecting the airway).<sup>558</sup>

Surgical resection is appropriate in patients with focal, well-defined VMs that are thrombosed and limited to a specific area. However, many VMs are infiltrative and involve more than one muscle group or fascial plane, resulting in extensive debulking. In these cases, sclerotherapy can be used as an adjunct.<sup>556</sup> Truncular VMs with deep venous abnormalities may require resection and deep venous reconstruction. Extratruncular, diffuse VMs are best treated with sclerotherapy.

Patients with VMs should be treated conservatively or with sclerotherapy where possible.

### 6.4. Syndromes

Some forms of combined congenital vascular malformations have been previously described as syndromes. The two most important syndromes are KTS and PWS, and both will be discussed in this chapter.

#### 6.4.1. Klippel-Trenaunay syndrome

Maurice Klippel and Paul Trenaunay first described this condition in 1900, referring to it as “naevus vasculosus osteohypertrophicus” after observing two patients with skin lesions associated with asymmetric soft tissue and bone hypertrophy.<sup>568</sup>

Vascular malformations can be single or combined depending on the components of the circulatory system that are involved in the lesion.<sup>553</sup> KTS is a syndrome characterized by capillary, venous, and lymphatic abnormalities, without significant arteriovenous shunting. It is a rare condition, occurring in 1:20,000-1:40,000 live births with an unclear cause.<sup>569</sup> Patients with this condition are characterized by the clinical triad of port wine stain, varicose veins, and soft tissue and/or bone hypertrophy (occasionally hypotrophy).

**6.4.1.1. Etiology.** The genetic origin of KTS is still unclear. The literature on the subject is heterogenous, varying from sporadic cases<sup>568</sup> to single gene defects.<sup>569</sup>

With regards to the development of clinical signs and symptoms, several theories have been proposed. It is thought that KTS presents as a consequence of a



mesodermal abnormality during foetal development, resulting in the maintenance of microscopic arteriovenous communications in the limb bud, leading to the development of naevi, hypertrophy, and superficial varices.<sup>570</sup>

Other developmental theories include primary obstruction or atresia of the venous system (leading to increased venous pressure, chronic venous hypertension, limb hypertrophy, and varicose veins)<sup>571</sup> and increased angiogenesis during development.<sup>572</sup>

**6.4.1.2. Clinical characteristics.** Clinical findings are usually present at birth, but in some cases they may not be fully apparent.<sup>573</sup> Clinical features are variable, ranging from minimal disease to disfigurement with a significant cosmetic impact.

**Clinical signs: capillary malformation (naevus flammeus).** In KTS patients typical capillary malformations are seen, often described as “naevus flammeus.” There are characterized by reddish pink macules that are present from birth but may not be visible until a few days after delivery.

Capillary malformations are present in KTS in up to 98% of patients, making them the most common associated clinical abnormality.<sup>574</sup> They are usually multiple, affecting the lower limb in 95% of cases, and can spread to the buttock or chest. Rarely, the entire side of the body may be affected.

**Clinical signs: varicose veins.** Varicose veins are another clinical feature associated with KTS. Abnormal veins can manifest as anomalous lateral veins or persistent embryonic veins. These are dilated and tortuous secondary to valvular incompetence or deep venous abnormalities. In the Mayo Clinic series, 72% of patients had atypical veins, the most common abnormality being the persistence of a lateral embryonic vein.<sup>575</sup> The authors advised that the presence of a large, persistent, superficial vein in the lateral thigh that does not join the deep system should alert the clinician to the possibility of KTS. A smaller proportion of patients had an anomalous medial vein or, more rarely, a suprapubic vein.

In addition to superficial venous abnormalities, the deep venous system also may be anomalous. Venous ectasia, hypoplasia, aplasia, or the persistence of an embryological sciatic vein are all manifestations of deep venous abnormalities in KTS.

**Clinical signs: lymphatic hyperplasia.** Lymphatic hyperplasia is found in a large number of patients. This presents as vesicles containing clear fluid and may be associated with marked lymphoedema, resulting in soft tissue hypertrophy and leg length discrepancy. In a large series from the Mayo Clinic, lymphatic hyperplasia was present in 67% of their patients.<sup>575</sup> Importantly, the presence of this triad was variable. In 63% of patients, all three features were present, while the remaining patients had two or fewer. Furthermore, most had lower limb malformations, mainly unilateral. Only 30% suffered from upper limb malformations.

Patients with KTS are at increased risk of developing superficial vein thrombosis, DVT and pulmonary embolism.<sup>569</sup>

**Symptoms.** The diagnosis of KTS is made according to the presence of physical signs. However, patients may present with symptoms, most commonly swelling, pain, bleeding from superficial varicosities, and superficial thrombophlebitis.<sup>575</sup>

Pain is a significant complaint, with up to 88% of patients experiencing varying degrees of discomfort.<sup>576</sup> A number of factors causing pain and discomfort in patients with KTS have been identified, including varicose veins, CVI (C3–C6), cellulitis, superficial vein thrombosis, DVT, vascular malformations, arthritis, and neuropathic pain.<sup>569</sup>

**6.4.1.3. Diagnosis.** The diagnosis of KTS is largely clinical. As for CVD, DUS examination is the gold standard to assess the superficial and deep venous systems in these patients. This enables assessment of aberrant venous anatomy, as well as confirming the absence of any clinically significant arteriovenous shunting.

Plain radiographs are used to measure limb length in the first instance. Other helpful imaging modalities to assess for venous abnormalities include MR imaging (useful to differentiate between bone, fat, muscle hypertrophy, and lymphoedema), MR angiography and/or venography, CT imaging (helpful in assessing bony anatomy), and contrast studies (arterial and venous), which allow delineation of the deep venous system and collaterals, as well as revealing localized vascular malformations.<sup>574</sup>

**6.4.1.4. Management.** KTS is a rare, complex disorder requiring a multidisciplinary approach to its management.<sup>577</sup> This involves a number of specialties, including paediatrics, general medicine, orthopaedic, plastic and vascular surgery, interventional radiology, cardiology, and physical therapy.<sup>578</sup>

The disorder is a mixed vascular malformation, with capillary, venous, and lymphatic components. There is no cure for the syndrome, and treatment is directed towards symptomatic management, secondary prevention of venous hypertension, and preservation of functional integrity of the legs.<sup>579</sup>

Patients often do well without intervention; however, absolute indications for treatment exist. These include haemorrhage, infection, acute venous thromboembolism, and refractory ulceration.<sup>578</sup>

**Conservative treatment.** The treatment of VMs is similar to that of other forms of CVD. Limb elevation, compression therapy (stockings or compression bandaging), and decongestive physical therapy, in the form of massage, all can be beneficial in the management of the hypertrophied limb affected by lymphoedema and CVI (C3–C6). Skin care is paramount in patients at risk of developing cutaneous manifestations of CVD, including ulceration.<sup>580</sup>

Because of the increased risk of venous thromboembolism, AC may be considered in patients with recurrent episodes of superficial or deep vein thrombosis.<sup>578</sup>

TCL therapy has been used in the treatment of naevus flammeus to lighten or, where possible, remove the cutaneous abnormality.

**Surgical treatment.** Surgical intervention is limited to those patients who are not candidates for conservative treatment. It is important to fully assess both the superficial and deep venous systems by DUS to evaluate the extent of VMs and the patency of the deep venous system prior to performing any surgical procedures.<sup>580</sup>

The Mayo Clinic has published the largest reported series of patients with KTS.<sup>575</sup> According to their experience, the most common operations performed in these patients were

epiphysiodesis (i.e. fusion of the epiphyseal, or growth, plate, in a child to slow or halt the growth of a limb), stripping of refluxing truncal veins, debulking procedures, and amputations. Nonetheless, they advised that patients with KTS should be treated conservatively where possible.

Abnormal veins and obvious varicosities can be removed where the deep venous system is competent and functional. Otherwise, compression therapy has been used successfully to reduce swelling and signs of venous disease.<sup>580</sup>

Incompetence of the main superficial trunks in KTS patients may not only be addressed by stripping, but also with more modern technology in the form of endovenous thermal (laser or radiofrequency) ablation or foam sclerotherapy.<sup>551,581</sup>

UGFS with STS and polidocanol has been used to treat superficial varicose tributaries with good cosmetic and functional results, with a reduction in pain levels and in the size of varicosities.<sup>566,579</sup>

Endovascular RFA has also been employed to treat venous insufficiency in patients with this syndrome. Patients reported decreased leg pain, oedema, and varicose vein prominence after intervention.<sup>551,582</sup> In selected cases, both treatment modalities can be used together for the treatment of superficial venous disease.<sup>581</sup>

Open surgery is not only limited to ligation and stripping, but also includes deep venous reconstructions or entrapped popliteal vein release in those cases where embryological abnormalities have left the patient with significant deep venous anomalies. Recurrence rates for treatment of VMs can be up to 15%, but clinical improvement in patients is significant and further interventions may be performed if required.<sup>580</sup>

Limb hypertrophy, resulting in leg length discrepancy, may be treated by epiphysiodesis in the growing child where the difference is predicted to exceed 2 cm. Very rarely, amputation is required where the size of the limb affects the patient's day to day functioning.<sup>583</sup>

**6.4.2. Parkes-Weber syndrome**

PWS presents similarly to KTS but has a distinct pathophysiological mechanism. It was first described in 1907 by the physician Frederick Parkes Weber. The incidence is sporadic, with no apparent racial or gender predilection.

**6.4.2.1. Etiology.** Unlike KTS, which is a low flow malformation involving the capillary, venous, and lymphatic systems, PWS is characterized by fast flow arteriovenous abnormalities. It is present from birth and most commonly affects the lower limbs. Persistent lateral thigh vein is uncommon, and lymphatic and soft tissue malformations do

not usually occur.<sup>551</sup> The presence of a fast flow fistula can increase cardiac preload, leading to cardiac failure, and even cutaneous ischaemia.

Originally thought to be a sporadic disease, there is evidence that the *RASA1* gene on chromosome 5 plays a significant role in the development of PWS. This gene mediates growth, differentiation, and proliferation of several cell types, including vascular endothelial cells.<sup>584,585</sup> Mutations result in multifocal capillary malformations with fast flow vascular lesions.<sup>584</sup>

**6.4.2.2. Clinical characteristics.** PWS is characterized, like KTS, by capillary cutaneous malformations and limb hypertrophy, in addition to AVMs. The connections between arteries and veins are high flow, and can result in skeletal or soft tissue hypertrophy. Local effects of arteriovenous fistulae are prominence and dilatation of the superficial veins secondary to increased pressure. A bruit or machinery murmur is audible and palpable throughout the cardiac cycle.

The presence of high flow fistulae prior to epiphyseal union results in regional effects, including increase in bone length, girth, and in the temperature of the affected limb.

Systemic effects are the result of the large flow of blood travelling from the arterial to the venous system. This can result in a marked increase in cardiac preload, leading to congestive cardiac failure.<sup>586</sup>

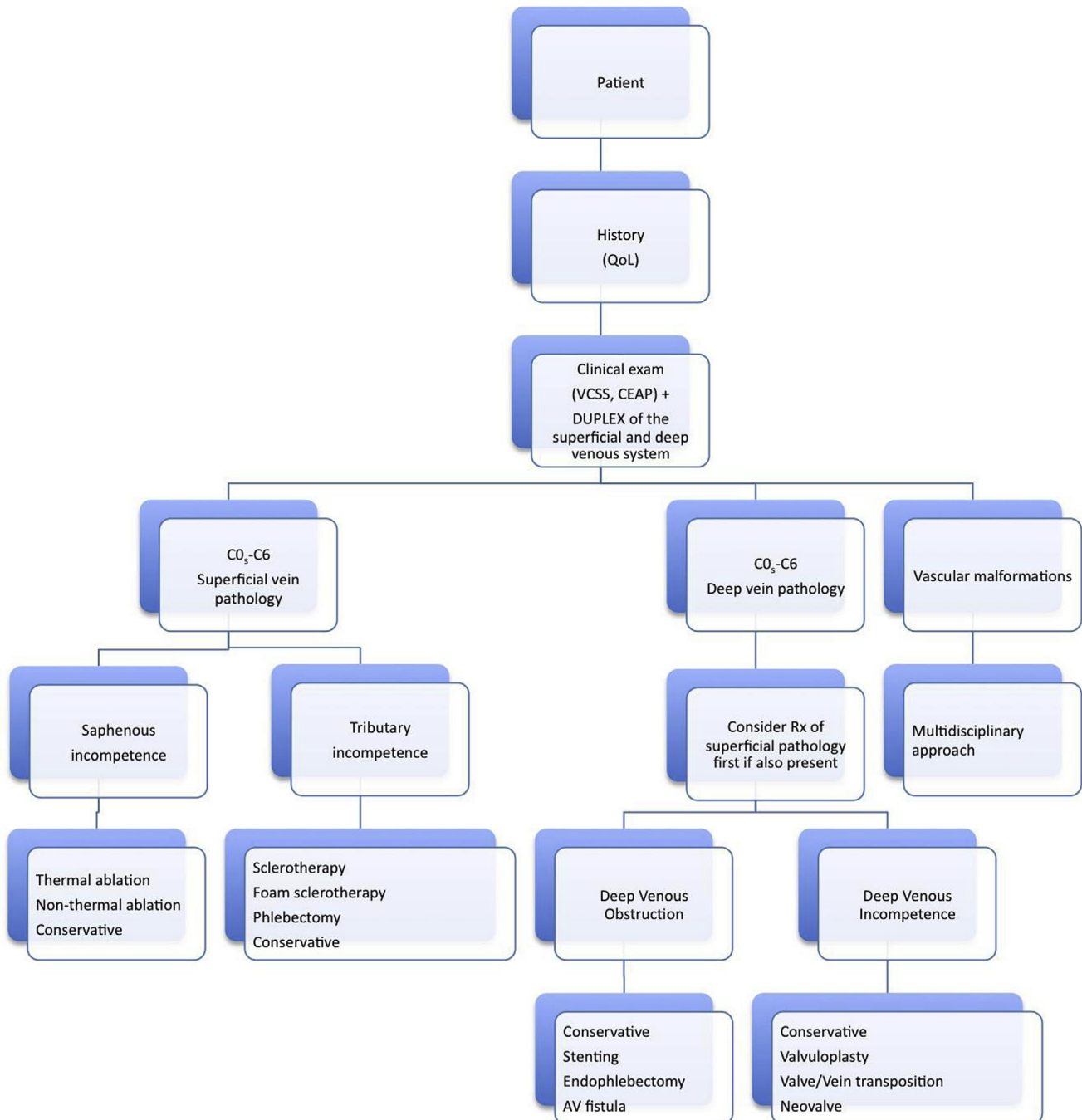
**6.4.2.3. Diagnosis.** Similar to KTS, DUS examination can be very helpful in characterizing arterial and venous anatomy, as well as in differentiating between high and low flow anomalies. Plain radiographs and MR imaging are helpful in assessing the hypertrophied limb. MR studies also provide assessment of lymphatic, venous, and soft tissue components of the affected limbs.<sup>587</sup> Arteriography and venography can assess the circulatory anatomy and characterize arteriovenous fistulation.

**6.4.2.4. Management.** Conservative management, where possible, is preferred. This includes prevention of trauma and damage to the affected limb as healing may be impaired and the patient is at an increased risk of bleeding in the presence of AVMs. Lower limb swelling may be managed with limb elevation and compression therapy. Limb growth, similar to KTS, can be addressed with epiphysiodesis where marked.

Fast flow, significant AVMs associated with clinical signs (e.g. ulceration or congestive cardiac failure), are a potential indication for intervention. This is in the form of arterial embolization or surgical resection of the lesion.<sup>585,588</sup> In extreme cases, amputation may be required where the affected limb is markedly impinging on a patient's QoL.

Recommendation 66	Class	Level	References
Symptoms and signs of chronic venous disease secondary to congenital venous malformations should be treated conservatively where possible.	I	C	551, 563, 566, 579, 585, 588
<b>Recommendation 67</b>			
Potential interventions in severe cases of congenital venous malformations, Klippel-Trenaunay syndrome, and Parkes-Weber syndrome should be decided by a multidisciplinary approach in a specialised centre	I	C	

## Flowchart 'Management of chronic venous disease'



## ACKNOWLEDGEMENT

The Writing Committee, the ESVS Review Committee and the Document Reviewers would like to thank Cora Hazelzet for her invaluable contribution in the preparation of the present guidelines.

## REFERENCES

- Eklöf B, Perrin M, Delis KT, Rutherford RB, Gloviczki P. Updated terminology of chronic venous disorders: the VEIN-TERM transatlantic interdisciplinary consensus document. *J Vasc Surg* 2009;**49**:498–501.
- Beebe-Dimmer JL, Pfeifer JR, Engle JS, Schottenfeld D. The epidemiology of chronic venous insufficiency and varicose veins. *Ann Epidemiol* 2005;**15**:175–84.
- Robertson L, Evans C, Fowkes FG. Epidemiology of chronic venous disease. *Phlebology* 2008;**23**:103–11.
- Van den Oever R, Hepp B, Debbaut B, Simon I. Socio-economic impact of chronic venous insufficiency. An underestimated public health problem. *Int Angiol* 1998;**17**:161–7.
- Bradbury A, Evans C, Allan P, Lee A, Ruckley CV, Fowkes FG. What are the symptoms of varicose veins? Edinburgh vein study cross sectional population survey. *Br Med J* 1999;**318**:353–6.
- Caggiati A, Bertocchi P. Regarding “fact and fiction surrounding the discovery of the venous valves”. *J Vasc Surg* 2001;**33**:1317.
- Caggiati A, Allegra C. Historical introduction. In: Bergan JJ, editor. *The vein book*. London: Elsevier Academic Press; 2007. p. 1–14.
- Illig KA, Rhodes JM, DeWeese J. Venous and lymphatic disease: a historical review. In: Gloviczki P, editor. *Handbook of venous disorders*. London: Edward Arnold Publishers Ltd; 2009. p. 3–11.
- Homans J. The etiology of treatment of varicose ulcer of the leg. *Surg Gyn Obstet* 1917:300–11.
- Linton RR. The post-thrombotic ulceration of the lower extremity: its etiology and surgical treatment. *Ann Surg* 1953;**138**:415–33.
- Smith FL. Varicose veins, complications and results of treatment of 5,000 patients. *Milit Surg* 1939;**85**:514–21.
- Orbach EJ. Sclerotherapy of varicose veins: utilization of an intravenous air block. *Am J Surg* 1944;**LXVI**:362–6.
- Trendelenburg F. Über die Unterbindung der Vena Saphena Magna bei Unterschenkel Varicen. *Beitr Z Clin Chir* 1891:195–210.
- Perrin M. *Insuffisance veineuse superficielle: notions fondamentales. Technique chirurgicales — Chirurgie vasculaire*. Paris: Elsevier Masson SAS; 2007. p. 43–161.
- Muller R. Traitement des varices par la phlebectomie ambulatoire. *Phlébologie* 1966;**19**:277–9.
- Bergan JJ. Conrad Jobst and the development of pressure gradient therapy for venous disease. In: Bergan JJ, Yao JST, editors. *Surgery of the veins*. Orlando: Grune & Stratton; 1985. p. 529–40.
- Husni EA. In situ saphenopopliteal bypass graft for incompetence of the femoral and popliteal veins. *Surg Gynecol Obstet* 1970;**130**:279–84.
- Palma EC, Esperon R. Vein transplants and grafts in the surgical treatment of the postphlebotic syndrome. *J Cardiovasc Surg (Torino)* 1960;**1**:94–107.
- Gloviczki P, Hollier LH, Dewanjee MK, Trastek VF, Hoffman EA, Kaye MP. Experimental replacement of the inferior vena cava: factors affecting patency. *Surgery* 1984;**95**:657–66.
- Eklöf B, Albrechtson U, Einarsson E, Plate G. The temporary arteriovenous fistula in venous reconstructive surgery. *Int Angiol* 1985;**4**:455–62.
- Kistner RL. Surgical repair of the incompetent femoral vein valve. *Arch Surg* 1975;**110**:1336–42.
- Raju S. Valvuloplasty and valve transfer. *Int Angiol* 1985;**4**:419–24.
- Hauer G. Die endoskopische subfasziale Diszision der Perforansvenen—vorläufige Mitteilung. *Vasa* 1985;**14**:59–61.
- Okrent D, Messersmith R, Buckman J. Transcatheter fibrinolytic therapy and angioplasty for left iliofemoral venous thrombosis. *J Vasc Interv Radiol* 1991;**2**:195–7 [discussion 8–200].
- Semba CP, Dake MD. Iliofemoral deep venous thrombosis: aggressive therapy with catheter-directed thrombolysis. *Radiology* 1994;**191**:487–94.
- Neglen P, Berry MA, Raju S. Endovascular surgery in the treatment of chronic primary and post-thrombotic iliac vein obstruction. *Eur J Vasc Endovasc Surg* 2000;**20**:560–71.
- Rabe E, Guex JJ, Puskas A, Scuderi A, Fernandez Quesada F. Epidemiology of chronic venous disorders in geographically diverse populations: results from the Vein Consult Program. *Int Angiol* 2012;**31**:105–15.
- Callam MJ. Epidemiology of varicose veins. *Br J Surg* 1994;**81**:167–73.
- Evans CJ, Fowkes FG, Ruckley CV, Lee AJ. Prevalence of varicose veins and chronic venous insufficiency in men and women in the general population: Edinburgh Vein Study. *J Epidemiol Community Health* 1999;**53**:149–53.
- Graham ID, Harrison MB, Nelson EA, Lorimer K, Fisher A. Prevalence of lower-limb ulceration: a systematic review of prevalence studies. *Adv Skin Wound Care* 2003;**16**:305–16.
- Criqui MH, Jamosmos M, Fronck A, Denenberg JO, Langer RD, Bergan J, et al. Chronic venous disease in an ethnically diverse population: the San Diego Population Study. *Am J Epidemiol* 2003;**158**:448–56.
- Rabe E, Pannier-Fisher F, Bromen K. Bonner Venenstudie der Deutschen Gesellschaft für Phlebologie — epidemiologische Untersuchung zur Frage der Häufigkeit und Ausprägung von chronischen Venenkrankheiten in der städtischen und ländlichen Wohnbevölkerung. *Phlebologie* 2003;**32**:1–14.
- Jawien A, Grzela T, Ochwat A. Prevalence of chronic insufficiency in men and women in Poland: multicenter cross-sectional study in 40,095 patients. *Phlebology* 2003;**18**:110–21.
- Carpentier PH, Maricq HR, Biro C, Poncot-Makinen CO, Franco A. Prevalence, risk factors, and clinical patterns of chronic venous disorders of lower limbs: a population-based study in France. *J Vasc Surg* 2004;**40**:650–9.
- Chiesa R, Marone EM, Limoni C, Volonte M, Schaefer E, Petrini O. Chronic venous insufficiency in Italy: the 24-cities cohort study. *Eur J Vasc Endovasc Surg* 2005;**30**:422–9.
- Bromen K, Pannier-Fischer F, Stang A, Rabe E, Bock E, Jockel KH. Lassen sich geschlechtsspezifische Unterschiede bei Venenerkrankungen durch Schwangerschaften und Hormoneinnahme erklären? *Gesundheitswesen* 2004;**66**:170–4.
- Brand FN, Dannenberg AL, Abbott RD, Kannel WB. The epidemiology of varicose veins: the Framingham Study. *Am J Prev Med* 1988;**4**:96–101.
- Hirai M, Naiki K, Nakayama R. Prevalence and risk factors of varicose veins in Japanese women. *Angiology* 1990;**41**:228–32.
- Jukkala TM, Mäkivaara LA, Juukkaala T, Hakama M, Laurikka J. The effects of parity, oral contraceptive use and hormone

- replacement therapy on the incidence of varicose veins. *J Obstet Gynaecol* 2006;448–51.
- 40 Engelhorn CA, Cassou MF, Engelhorn AL, Salles-Cunha SX. Does the number of pregnancies affect patterns of great saphenous vein reflux in women with varicose veins? *Phlebology* 2010;25:190–5.
  - 41 Rabe E. Vein Bonn Study. *Phlebologie* 2006:179–86.
  - 42 Iannuzzi A, Panico S, Ciardullo AV, Bellati C, Cioffi V, Iannuzzo G, et al. Varicose veins of the lower limbs and venous capacitance in postmenopausal women: relationship with obesity. *J Vasc Surg* 2002;36:965–8.
  - 43 Padberg Jr F, Cerveira JJ, Lal BK, Pappas PJ, Varma S, Hobson RW. Does severe venous insufficiency have a different etiology in the morbidly obese? Is it venous? *J Vasc Surg* 2003;37:79–85.
  - 44 Danielsson G, Eklöf B, Grandinetti A, Kistner RL. The influence of obesity on chronic venous disease. *Vasc Endovascular Surg* 2002;36:271–6.
  - 45 Zoller B, Ji J, Sundquist J, Sundquist K. Family history and risk of hospital treatment for varicose veins in Sweden. *Br J Surg* 2012;99:948–53.
  - 46 Krysa J, Jones GT, van Rij AM. Evidence for a genetic role in varicose veins and chronic venous insufficiency. *Phlebology* 2012;27:329–35.
  - 47 Ruckley CV, Evans CJ, Allan PL, Lee AJ, Fowkes FG. Chronic venous insufficiency: clinical and duplex correlations. The Edinburgh Vein Study of venous disorders in the general population. *J Vasc Surg* 2002;36:520–5.
  - 48 Maurins U, Hoffmann BH, Losch C, Jockel KH, Rabe E, Pannier F. Distribution and prevalence of reflux in the superficial and deep venous system in the general population — results from the Bonn Vein Study, Germany. *J Vasc Surg* 2008;48:680–7.
  - 49 Labropoulos N, Leon L, Kwon S, Tassiopoulos A, Gonzalez-Fajardo JA, Kang SS, et al. Study of the venous reflux progression. *J Vasc Surg* 2005;41:291–5.
  - 50 Pannier F, Rabe E. The relevance of the natural history of varicose veins and refunded care. *Phlebology* 2012;27(Suppl. 1):23–6.
  - 51 Caggiati A. Fascial relationships of the long saphenous vein. *Circulation* 1999;100:2547–9.
  - 52 Caggiati A. The saphenous venous compartments. *Surg Radiol Anat* 1999;21:29–34.
  - 53 Oguzkurt L. Ultrasonographic anatomy of the lower extremity superficial veins. *Diagn Interv Radiol* 2012;18:423–30.
  - 54 Pang AS. Location of valves and competence of the great saphenous vein above the knee. *Ann Acad Med Singapore* 1991;20:248–50.
  - 55 Cavezzi A, Labropoulos N, Partsch H, Ricci S, Caggiati A, Myers K, et al. Duplex ultrasound investigation of the veins in chronic venous disease of the lower limbs — UIP consensus document. Part II. Anatomy. *Eur J Vasc Endovasc Surg* 2006;31:288–99.
  - 56 Caggiati A. Fascial relationships of the short saphenous vein. *J Vasc Surg* 2001;34:241–6.
  - 57 Schweighofer G, Muhlberger D, Brenner E. The anatomy of the small saphenous vein: fascial and neural relations, saphenofemoral junction, and valves. *J Vasc Surg* 2010;51:982–9.
  - 58 van Limborgh J, Hage RW. The systemic anatomy of the perforating veins in the leg, especially Cockett's veins. *Phlebologie* 1982;35:19–28.
  - 59 Delis KT, Husmann M, Kalodiki E, Wolfe JH, Nicolaidis AN. In situ hemodynamics of perforating veins in chronic venous insufficiency. *J Vasc Surg* 2001;33:773–82.
  - 60 Delis KT, Ibegbuna V, Nicolaidis AN, Lauro A, Hafez H. Prevalence and distribution of incompetent perforating veins in chronic venous insufficiency. *J Vasc Surg* 1998;28:815–25.
  - 61 Mozes G, Gloviczki P, Menawat SS, Fisher DR, Carmichael SW, Kadar A. Surgical anatomy for endoscopic subfascial division of perforating veins. *J Vasc Surg* 1996;24:800–8.
  - 62 White JV, Katz ML, Cisek P, Kreithen J. Venous outflow of the leg: anatomy and physiologic mechanism of the plantar venous plexus. *J Vasc Surg* 1996;24:819–24.
  - 63 Caggiati A, Bergan JJ, Gloviczki P, Jantet G, Wendell-Smith CP, Partsch H, et al. Nomenclature of the veins of the lower limbs: an international interdisciplinary consensus statement. *J Vasc Surg* 2002;36:416–22.
  - 64 Quinlan DJ, Alikhan R, Gishen P, Sidhu PS. Variations in lower limb venous anatomy: implications for US diagnosis of deep vein thrombosis. *Radiology* 2003;228:443–8.
  - 65 Casella IB, Presti C, Yamazaki Y, Vassoler AA, Furuya LA, Sabbag CD. A duplex scan-based morphologic study of the femoral vein: incidence and patterns of duplication. *Vasc Med* 2010;15:197–203.
  - 66 Banjo AO. Comparative study of the distribution of venous valves in the lower extremities of black Africans and Caucasians: pathogenetic correlates of prevalence of primary varicose veins in the two races. *Anat Rec* 1987;217:407–12.
  - 67 Muhlberger D, Morandini L, Brenner E. An anatomical study of femoral vein valves near the saphenofemoral junction. *J Vasc Surg* 2008;48:994–9.
  - 68 Shepherd JT. Role of the veins in the circulation. *Circulation* 1966;33:484–91.
  - 69 Rothe CF. Venous system: physiology of the capacitance vessels. In: Shepherd JT, Abboud FM, Geiger SR, editors. *The Cardiovascular System, peripheral circulation and organ blood flow, part 1, Handbook of physiology*. Bethesda: American Physiological Society; 1983. p. 397–452.
  - 70 Katz AI, Chen Y, Moreno AH. Flow through a collapsible tube. Experimental analysis and mathematical model. *Biophys J* 1969;9:1261–79.
  - 71 Katz ML, Comerota AJ, Kerr RP, Caputo GC. Variability of venous-hemodynamics with daily activity. *J Vasc Surg* 1994;19:361–5.
  - 72 Arnoldi CC. Venous pressure in the leg of healthy human subjects at rest and during muscular exercise in the nearly erect position. *Acta Chir Scand* 1965;130:570–83.
  - 73 Strandén E. Ventömningens fysiologi. In: Norgren L, editor. *Vensjukdomar*. Lund: Studentlitteratur; 2004. p. 45–55.
  - 74 Goldman MP, Fronck A. Anatomy and pathophysiology of varicose veins. *J Dermatol Surg Oncol* 1989;15:138–45.
  - 75 Meissner MH, Moneta G, Burnand K, Gloviczki P, Lohr JM, Lurie F, et al. The hemodynamics and diagnosis of venous disease. *J Vasc Surg* 2007;46(Suppl. S):4S–24S.
  - 76 Lurie F, Kistner RL, Eklöf B, Kessler D. Mechanism of venous valve closure and role of the valve in circulation: a new concept. *J Vasc Surg* 2003;38:955–61.
  - 77 Lurie F, Kistner RL. The relative position of paired valves at venous junctions suggests their role in modulating three-dimensional flow pattern in veins. *Eur J Vasc Endovasc Surg* 2012;44:337–40.
  - 78 Alimi YS, Barthelemy P, Juhan C. Venous pump of the calf: a study of venous and muscular pressures. *J Vasc Surg* 1994;20:728–35.
  - 79 Gardner AMN, Fox RH. *The return of blood to the heart: venous pumps in health and disease*. London: John Libbey & Co Ltd; 1989.

- 80 Araki CT, Back TL, Padberg FT, Thompson PN, Jamil Z, Lee BC, et al. The significance of calf muscle pump function in venous ulceration. *J Vasc Surg* 1994;**20**:872–7.
- 81 Ludbrook J. The musculovenous pumps of the human lower limb. *Am Heart J* 1966;**71**:635–41.
- 82 Strandén E. Edema in venous insufficiency. In: Wittens C, editor. *Best practice in venous procedures*. Turin: Ediziona Minerva Medica; 2010. p. 131–40.
- 83 Nicolaides AN, Hussein MK, Szendro G, Christopoulos D, Vasdekis S, Clarke H. The relation of venous ulceration with ambulatory venous pressure measurements. *J Vasc Surg* 1993;**17**:414–9.
- 84 Plate G, Brudin L, Eklöf B, Jensen R, Ohlin P. Congenital vein valve aplasia. *World J Surg* 1986;**10**:929–34.
- 85 Nicolaides AN. Investigations of chronic venous insufficiency: a consensus statement (France March 5–9, 1997). *Circulation* 2000;**E126**–63.
- 86 Hosoi Y, Zukowski A, Kakkos SK, Nicolaides AN. Ambulatory venous pressure measurements: new parameters derived from a mathematic hemodynamic model. *J Vasc Surg* 2002;**36**:137–42.
- 87 Raju S, Fredericks R. Venous obstruction: an analysis of one hundred thirty-seven cases with hemodynamic, venographic, and clinical correlations. *J Vasc Surg* 1991;**14**:305–13.
- 88 Labropoulos N, Patel PJ, Tiongson JE, Pryor L, Leon Jr LR, Tassiopoulos AK. Patterns of venous reflux and obstruction in patients with skin damage due to chronic venous disease. *Vasc Endovascular Surg* 2007;**41**:33–40.
- 89 Rose SS, Ahmed A. Some thoughts on the aetiology of varicose veins. *J Cardiovasc Surg (Torino)* 1986;**27**:534–43.
- 90 Cotton LT. Varicose veins. Gross anatomy and development. *Br J Surg* 1961;**48**:589–98.
- 91 Travers JP, Brookes CE, Evans J, Baker DM, Kent C, Makin GS, et al. Assessment of wall structure and composition of varicose veins with reference to collagen, elastin and smooth muscle content. *Eur J Vasc Endovasc Surg* 1996;**11**:230–7.
- 92 Lowell RC, Gloviczki P, Miller VM. In vitro evaluation of endothelial and smooth muscle function of primary varicose veins. *J Vasc Surg* 1992;**16**:679–86.
- 93 Gandhi RH, Irizarry E, Nackman GB, Halpern VJ, Mulcare RJ, Tilson MD. Analysis of the connective tissue matrix and proteolytic activity of primary varicose veins. *J Vasc Surg* 1993;**18**:814–20.
- 94 Alexander CJ. The theoretical basis of varicose vein formation. *Med J Aust* 1972;**1**:258–61.
- 95 Labropoulos N, Giannoukas AD, Delis K, Mansour MA, Kang SS, Nicolaides AN, et al. Where does venous reflux start? *J Vasc Surg* 1997;**26**:736–42.
- 96 Lurie F, Kistner R, Perrin M, Raju S, Neglen P, Maleti O. Invasive treatment of deep venous disease. A UIP consensus. *Int Angiol* 2010;**29**:199–204.
- 97 Johnson BF, Manzo RA, Bergelin RO, Strandness Jr DE. Relationship between changes in the deep venous system and the development of the postthrombotic syndrome after an acute episode of lower limb deep vein thrombosis: a one- to six-year follow-up. *J Vasc Surg* 1995;**21**:307–12.
- 98 Johnson BF, Manzo RA, Bergelin RO, Strandness Jr DE. The site of residual abnormalities in the leg veins in long-term follow-up after deep vein thrombosis and their relationship to the development of the post-thrombotic syndrome. *Int Angiol* 1996;**15**:14–9.
- 99 Nelzen O, Bergqvist D, Lindhagen A. Leg ulcer etiology – a cross sectional population study. *J Vasc Surg* 1991;**14**:557–64.
- 100 Delis KT. Perforator vein incompetence in chronic venous disease: a multivariate regression analysis model. *J Vasc Surg* 2004;**40**:626–33.
- 101 Darvall KA, Bate GR, Adam DJ, Bradbury AW. Generic health-related quality of life is significantly worse in varicose vein patients with lower limb symptoms independent of CEAP clinical grade. *Eur J Vasc Endovasc Surg* 2012;**44**:341–4.
- 102 Palfreyman SJ, Drewery-Carter K, Rigby K, Michaels JA, Tod AM. Varicose veins: a qualitative study to explore expectations and reasons for seeking treatment. *J Clin Nurs* 2004;**13**:332–40.
- 103 Fragkouli K, Mitselou A, Boumba VA, Siozios G, Vougiouklakis GT, Vougiouklakis T. Unusual death due to a bleeding from a varicose vein: a case report. *BMC Res Notes* 2012;**5**:488.
- 104 Chiesa R, Marone EM, Limoni C, Volonte M, Petrini O. Chronic venous disorders: correlation between visible signs, symptoms, and presence of functional disease. *J Vasc Surg* 2007;**46**:322–30.
- 105 Navarro TP, Delis KT, Ribeiro AP. Clinical and hemodynamic significance of the greater saphenous vein diameter in chronic venous insufficiency. *Arch Surg* 2002;**137**:1233–7.
- 106 Kahn SR, M’Lan CE, Lamping DL, Kurz X, Berard A, Abenheim LA, et al. Relationship between clinical classification of chronic venous disease and patient-reported quality of life: results from an international cohort study. *J Vasc Surg* 2004;**39**:823–8.
- 107 Perrin MR, Labropoulos N, Leon Jr LR. Presentation of the patient with recurrent varices after surgery (REVAS). *J Vasc Surg* 2006;**43**:327–34.
- 108 Beebe HG, Bergan JJ, Bergqvist D, Eklöf B, Eriksson I, Goldman MP, et al. Classification and grading of chronic venous disease in the lower limbs. A consensus statement. *Eur J Vasc Endovasc Surg* 1996;**12**:487–91 [discussion 91–2].
- 109 Eklöf B, Rutherford RB, Bergan JJ, Carpentier PH, Gloviczki P, Kistner RL, et al. Revision of the CEAP classification for chronic venous disorders: consensus statement. *J Vasc Surg* 2004;**40**:1248–52.
- 110 Sinabulya H, Holmberg A, Blomgren L. Interobserver variability in the assessment of the clinical severity of superficial venous insufficiency. *Phlebology* 2013. <http://dx.doi.org/10.1177/0268355513515474> [Epub].
- 111 Krishnan S, Nicholls SC. Chronic venous insufficiency: clinical assessment and patient selection. *Semin Intervent Radiol* 2005;**22**:169–77.
- 112 Rabe E, Pannier F. Clinical, aetiological, anatomical and pathological classification (CEAP): gold standard and limits. *Phlebology* 2012;**27**(Suppl. 1):114–8.
- 113 Carradice D, Mazari FA, Samuel N, Allgar V, Hatfield J, Chetter IC. Modelling the effect of venous disease on quality of life. *Br J Surg* 2011;**98**:1089–98.
- 114 Shepherd AC, Gohel MS, Lim CS, Davies AH. A study to compare disease-specific quality of life with clinical anatomical and hemodynamic assessments in patients with varicose veins. *J Vasc Surg* 2011;**53**:374–82.
- 115 Rutherford RB, Padberg Jr FT, Comerota AJ, Kistner RL, Meissner MH, Moneta GL. Venous severity scoring: an adjunct to venous outcome assessment. *J Vasc Surg* 2000;**31**:1307–12.
- 116 Vasquez MA, Rabe E, McLafferty RB, Shortell CK, Marston WA, Gillespie D, et al. Revision of the venous clinical severity score: venous outcomes consensus statement: special communication of the American Venous Forum Ad Hoc Outcomes Working Group. *J Vasc Surg* 2010;**52**:1387–96.

- 117 Ricci MA, Emmerich J, Callas PW, Rosendaal FR, Stanley AC, Naud S, et al. Evaluating chronic venous disease with a new venous severity scoring system. *J Vasc Surg* 2003;**38**: 909–15.
- 118 Passman MA, McLafferty RB, Lentz MF, Nagre SB, Iafrati MD, Bohannon WT, et al. Validation of Venous Clinical Severity Score (VCSS) with other venous severity assessment tools from the American Venous Forum, National Venous Screening Program. *J Vasc Surg* 2011;**54**:25–9S.
- 119 Kakkos SK, Rivera MA, Matsagas MI, Lazarides MK, Robless P, Belcaro G, et al. Validation of the new venous severity scoring system in varicose vein surgery. *J Vasc Surg* 2003;**38**:224–8.
- 120 van Rij AM, Jones GT, Hill BG, Amer M, Thomson IA, Pettigrew RA, et al. Mechanical inhibition of angiogenesis at the saphenofemoral junction in the surgical treatment of varicose veins: early results of a blinded randomized controlled trial. *Circulation* 2008;**118**:66–74.
- 121 Perrin M, Dedieu F, Jessent V, Blanc MP. Evaluation of the new severity scoring system in chronic venous disease of the lower limbs: an observational study conducted by French angiologists. *Phlebology* 2006;**13**:6–11.
- 122 Villalta S, Bagatella P, Piccioli A, Lensing A, Prins M, Prandoni P. Assessment and validity and reproducibility of a clinical scale for the post-thrombotic syndrome [abstract]. *Haemostasis* 1994:158a.
- 123 Kahn SR. Measurement properties of the Villalta scale to define and classify the severity of the post-thrombotic syndrome. *J Thromb Haemost* 2009;**7**:884–8.
- 124 Sritharan K, Lane TR, Davies AH. The burden of depression in patients with symptomatic varicose veins. *Eur J Vasc Endovasc Surg* 2012;**43**:480–4.
- 125 Jantet G. Chronic venous insufficiency: worldwide results of the RELIEF study. Reflux assessment and quality of life improvement with micronized flavonoids. *Angiology* 2002;**53**: 245–56.
- 126 Ware Jr JE, Gandek B. Overview of the SF-36 Health Survey and the International Quality of Life Assessment (IQOLA) Project. *J Clin Epidemiol* 1998;**51**:903–12.
- 127 Kaplan RM, Criqui MH, Denenberg JO, Bergan J, Fronck A. Quality of life in patients with chronic venous disease: San Diego population study. *J Vasc Surg* 2003;**37**:1047–53.
- 128 Moura RM, Goncalves GS, Navarro TP, Britto RR, Dias RC. Relationship between quality of life and the CEAP clinical classification in chronic venous disease. *Rev Bras Fisioter* 2010;**14**:99–105.
- 129 EuroQol, Group. EuroQol – a new facility for the measurement of health-related quality of life. *Health Policy* 1990;**16**: 199–208.
- 130 Garratt AM, Macdonald LM, Ruta DA, Russell IT, Buckingham JK, Krukowski ZH. Towards measurement of outcome for patients with varicose veins. *Qual Health Care* 1993;**2**:5–10.
- 131 Smith JJ, Garratt AM, Guest M, Greenhalgh RM, Davies AH. Evaluating and improving health-related quality of life in patients with varicose veins. *J Vasc Surg* 1999;**30**:710–9.
- 132 Launois R, Reboul-Marty J, Henry B. Construction and validation of a quality of life questionnaire in chronic lower limb venous insufficiency (CIVIQ). *Qual Life Res* 1996;**5**:539–54.
- 133 Likert R. A technique for the measurement of attitudes. *Arch Psychol* 1932;**22**:1–55.
- 134 Erenidou K, Launois R, Katsamouris A, Lionis C. Translation and validation of a quality of life questionnaire for chronic lower limb venous insufficiency into greek. *Int Angiol* 2004;**23**:394–9.
- 135 Biemans AA, van der Velden SK, Bruijninx CM, Buth J, Nijsten T. Validation of the chronic venous insufficiency quality of life questionnaire in Dutch patients treated for varicose veins. *Eur J Vasc Endovasc Surg* 2011;**42**:246–53.
- 136 Launois R, Mansilha A, Jantet G. International psychometric validation of the Chronic Venous Disease quality of life Questionnaire (CIVIQ-20). *Eur J Vasc Endovasc Surg* 2010;**40**: 783–9.
- 137 Abenheim L, Kurz X. The VEINES study (VEnous Insufficiency Epidemiologic and Economic Study): an international cohort study on chronic venous disorders of the leg. VEINES Group. *Angiology* 1997;**48**:59–66.
- 138 Lamping DL, Schroter S, Kurz X, Kahn SR, Abenheim L. Evaluation of outcomes in chronic venous disorders of the leg: development of a scientifically rigorous, patient-reported measure of symptoms and quality of life. *J Vasc Surg* 2003;**37**:410–9.
- 139 Kahn SR, Lamping DL, Ducruet T, Arsenault L, Miron MJ, Roussin A, et al. VEINES-QOL/Sym questionnaire was a reliable and valid disease-specific quality of life measure for deep venous thrombosis. *J Clin Epidemiol* 2006;**59**:1049–56.
- 140 Glociczki P, Comerota AJ, Dalsing MC, Eklöf BG, Gillespie DL, Glociczki ML, et al. The care of patients with varicose veins and associated chronic venous diseases: clinical practice guidelines of the Society for Vascular Surgery and the American Venous Forum. *J Vasc Surg* 2011;**53**:25–48S.
- 141 Fowkes FG, Lee AJ, Evans CJ, Allan PL, Bradbury AW, Ruckley CV. Lifestyle risk factors for lower limb venous reflux in the general population: Edinburgh Vein Study. *Int J Epidemiol* 2001;**30**:846–52.
- 142 Cronenwett JL, Johnston KW. *Patient clinical evaluation. Rutherford's Vascular Surgery*. 7th ed. Philadelphia: Saunders; 2010. p. 204–15.
- 143 Uhl JF, Cornu-Thenard A, Carpentier PH, Widmer MT, Partsch H, Antignani PL. Clinical and hemodynamic significance of corona phlebectatica in chronic venous disorders. *J Vasc Surg* 2005;**42**:1163–8.
- 144 Vrouwenraets BC, Keeman JN. Fysische diagnostiek – de bandjesproeven bij varices. *Ned Tijdschr Geneesk* 2000;**144**:1267–72.
- 145 Hoffmann WH, Toonder IM, Wittens CHA. Value of the Trendelenburg tourniquet test in the assessment of primary varicose veins. *Phlebology* 2004;**19**:77–80.
- 146 Labropoulos N, Tiongson J, Pryor L, Tassiopoulos AK, Kang SS, Ashraf Mansour M, et al. Definition of venous reflux in lower-extremity veins. *J Vasc Surg* 2003;**38**:793–8.
- 147 Coleridge-Smith P, Labropoulos N, Partsch H, Myers K, Nicolaidis A, Cavezzi A. Duplex ultrasound investigation of the veins in chronic venous disease of the lower limbs – UIP consensus document. Part I. Basic principles. *Eur J Vasc Endovasc Surg* 2006;**31**:83–92.
- 148 De Maeseneer M, Pichot O, Cavezzi A, Earnshaw J, van Rij A, Lurie F, et al. Duplex ultrasound investigation of the veins of the lower limbs after treatment for varicose veins – UIP consensus document. *Eur J Vasc Endovasc Surg* 2011;**42**:89–102.
- 149 Cappelli M, Molino Lova R, Ermini S, Zamboni P. Hemodynamics of the sapheno-femoral junction. Patterns of reflux and their clinical implications. *Int Angiol* 2004;**23**:25–8.
- 150 Cappelli M, Molino Lova R, Ermini S, Giangrandi I, Giannelli F, Zamboni P. Hemodynamics of the sapheno-femoral complex: an operational diagnosis of proximal femoral valve function. *Int Angiol* 2006;**25**:356–60.

- 151 Rautio T, Perala J, Biancari F, Wiik H, Ohtonen P, Haukipuro K, et al. Accuracy of hand-held Doppler in planning the operation for primary varicose veins. *Eur J Vasc Endovasc Surg* 2002;**24**:450–5.
- 152 DePalma RG, Hart MT, Zanin L, Massarin EH. Physical examination, Doppler ultrasound and colour flow duplex scanning: guides to therapy for primary varicose veins. *Phlebology* 1993;**8**:7–11.
- 153 Baker SR, Burnand KG, Sommerville KM, Thomas ML, Wilson NM, Browse NL. Comparison of venous reflux assessed by duplex scanning and descending phlebography in chronic venous disease. *Lancet* 1993;**341**:400–3.
- 154 Magnusson M, Kalebo P, Lukes P, Sivertsson R, Risberg B. Colour Doppler ultrasound in diagnosing venous insufficiency. A comparison to descending phlebography. *Eur J Vasc Endovasc Surg* 1995;**9**:437–43.
- 155 Baldt MM, Bohler K, Zontsich T, Bankier AA, Breitenseher M, Schneider B, et al. Preoperative imaging of lower extremity varicose veins: color coded duplex sonography or venography. *J Ultrasound Med* 1996;**15**:143–54.
- 156 Meyer T, Cavallaro A, Lang W. Duplex ultrasonography in the diagnosis of incompetent Cockett veins. *Eur J Ultrasound* 2000;**11**:175–80.
- 157 Blomgren L, Johansson G, Bergqvist D. Randomized clinical trial of routine preoperative duplex imaging before varicose vein surgery. *Br J Surg* 2005;**92**:688–94.
- 158 Haenen JH, van Langen H, Janssen MC, Wollersheim H, van 't Hof MA, van Asten WN, et al. Venous duplex scanning of the leg: range, variability and reproducibility. *Clin Sci (Lond)* 1999;**96**:271–7.
- 159 Lensing AW, Prandoni P, Brandjes D, Huisman PM, Vigo M, Tomasella G, et al. Detection of deep-vein thrombosis by real-time B-mode ultrasonography. *N Engl J Med* 1989;**320**:342–5.
- 160 Mattos MA, Londrey GL, Leutz DW, Hodgson KJ, Ramsey DE, Barkmeier LD, et al. Color-flow duplex scanning for the surveillance and diagnosis of acute deep venous thrombosis. *J Vasc Surg* 1992;**15**:366–75.
- 161 Holdstock JM, Dos Santos SJ, Harrison CC, Price BA, Whiteley MS. Haemorrhoids are associated with internal iliac vein reflux in up to one-third of women presenting with varicose veins associated with pelvic vein reflux. *Phlebology* 2014 [Epub].
- 162 Park SJ, Lim JW, Ko YT, Lee DH, Yoon Y, Oh JH, et al. Diagnosis of pelvic congestion syndrome using transabdominal and transvaginal sonography. *Am J Roentgenol* 2004;**182**:683–8.
- 163 De Maeseneer MG, Vandenbroeck CP, Hendriks JM, Lauwers PR, Van Schil PE. Accuracy of duplex evaluation one year after varicose vein surgery to predict recurrence at the sapheno-femoral junction after five years. *Eur J Vasc Endovasc Surg* 2005;**29**:308–12.
- 164 Jiang P, van Rij AM, Christie R, Hill G, Solomon C, Thomson I. Recurrent varicose veins: patterns of reflux and clinical severity. *Cardiovasc Surg* 1999;**7**:332–9.
- 165 Labropoulos N, Touloupakis E, Giannoukas AD, Leon M, Katsamouris A, Nicolaidis AN. Recurrent varicose veins: investigation of the pattern and extent of reflux with color flow duplex scanning. *Surgery* 1996;**119**:406–9.
- 166 Kostas T, Ioannou CV, Touloupakis E, Daskalaki E, Giannoukas AD, Tsetis D, et al. Recurrent varicose veins after surgery: a new appraisal of a common and complex problem in vascular surgery. *Eur J Vasc Endovasc Surg* 2004;**27**:275–82.
- 167 Theivacumar NS, Darwood R, Gough MJ. Neovascularisation and recurrence 2 years after varicose vein treatment for sapheno-femoral and great saphenous vein reflux: a comparison of surgery and endovenous laser ablation. *Eur J Vasc Endovasc Surg* 2009;**38**:203–7.
- 168 Chapman-Smith P, Browne A. Prospective five-year study of ultrasound-guided foam sclerotherapy in the treatment of great saphenous vein reflux. *Phlebology* 2009;**24**:183–8.
- 169 Labropoulos N, Borge M, Pierce K, Pappas PJ. Criteria for defining significant central vein stenosis with duplex ultrasound. *J Vasc Surg* 2007;**46**:101–7.
- 170 Phillips GW, Paige J, Molan MP. A comparison of colour duplex ultrasound with venography and varicography in the assessment of varicose veins. *Clin Radiol* 1995;**50**:20–5.
- 171 Whitney RJ. The measurement of volume changes in human limbs. *J Physiol* 1953;**121**:1–27.
- 172 Janssen MC, Claassen JA, van Asten WN, Wollersheim H, de Rooij MJ, Thien T. Validation of the supine venous pump function test: a new non-invasive tool in the assessment of deep venous insufficiency. *Clin Sci (Lond)* 1996;**91**:483–8.
- 173 Hertzman AB. Photoelectric plethysmography on the fingers and toes in man. *Exp Biol Med (Maywood)* 1937;**37**:529–34.
- 174 Abramowitz HB, Queral LA, Finn WR, Nora Jr PF, Peterson LK, Bergan JJ, et al. The use of photoplethysmography in the assessment of venous insufficiency: a comparison to venous pressure measurements. *Surgery* 1979;**86**:434–41.
- 175 Wienert V, Blazek V. Eine neue, apparative nichtinvasive Diagnostik der chronisch-venösen Insuffizienz. *Phleb u Prokt* 1982;**11**:110–3.
- 176 Blazek V, Schmitt HJ, Schulz-Ehrenburg U, Kerner J. Digitale Photoplethysmografie (dPPG) für die Beinvenendiagnostik – medizinisch-technische Grundlagen. *Phleb u Prokt* 1989;**18**:91–7.
- 177 Nicolaidis AN, Miles C. Photoplethysmography in the assessment of venous insufficiency. *J Vasc Surg* 1987;**5**:405–12.
- 178 van Bemmelen PS, van Ramshorst B, Eikelboom BC. Photoplethysmography reexamined: lack of correlation with duplex scanning. *Surgery* 1992;**112**:544–8.
- 179 Bays RA, Healy DA, Atnip RG, Neumyer M, Thiele BL. Validation of air plethysmography, photoplethysmography, and duplex ultrasonography in the evaluation of severe venous stasis. *J Vasc Surg* 1994;**20**:721–7.
- 180 Owens LV, Farber MA, Young ML, Carlin RE, Criado-Pallares E, Passman MA, et al. The value of air plethysmography in predicting clinical outcome after surgical treatment of chronic venous insufficiency. *J Vasc Surg* 2000;**32**:961–8.
- 181 Yang D, Vandongen YK, Stacey MC. Variability and reliability of air plethysmographic measurements for the evaluation of chronic venous disease. *J Vasc Surg* 1997;**26**:638–42.
- 182 Thulesius O, Norgren L, Gjores JE. Foot-volumetry, a new method for objective assessment of edema and venous function. *Vasa* 1973;**2**:325–9.
- 183 Ruehm SG, Wiesner W, Debatin JF. Pelvic and lower extremity veins: contrast-enhanced three-dimensional MR venography with a dedicated vascular coil-initial experience. *Radiology* 2000;**215**:421–7.
- 184 Pfeil A, Betge S, Poehlmann G, Boettcher J, Drescher R, Malich A, et al. Magnetic resonance VIBE venography using the blood pool contrast agent gadofosveset trisodium – an interrater reliability study. *Eur J Radiol* 2012;**81**:547–52.
- 185 Spritzer CE. Progress in MR imaging of the venous system. *Perspect Vasc Surg Endovasc Ther* 2009;**21**:105–16.



- 186 Enden T, Storås TH, Negård A, Haig Y, Sandvik L, Gjesdal KI, et al. Visualization of deep veins and detection of deep vein thrombosis (DVT) with balanced turbo field echo (b-TFE) and contrast-enhanced T1 fast field echo (CE-FFE) using a blood pool agent (BPA). *J Magn Reson Imaging* 2010;**31**:416–24.
- 187 Koc Z, Oguzkurt L. Interruption or congenital stenosis of the inferior vena cava: prevalence, imaging, and clinical findings. *Eur J Radiol* 2007;**62**:257–66.
- 188 Gayer G, Luboshitz J, Hertz M, Zissin R, Thaler M, Lubetsky A, et al. Congenital anomalies of the inferior vena cava revealed on CT in patients with deep vein thrombosis. *Am J Roentgenol* 2003;**180**:729–32.
- 189 Wolpert LM, Rahmani O, Stein B, Gallagher JJ, Drezner AD. Magnetic resonance venography in the diagnosis and management of May-Thurner syndrome. *Vasc Endovascular Surg* 2002;**36**:51–7.
- 190 Asciutto G, Mumme A, Marpe B, Koster O, Asciutto KC, Geier B. MR venography in the detection of pelvic venous congestion. *Eur J Vasc Endovasc Surg* 2008;**36**:491–6.
- 191 Hsieh MC, Chang PY, Hsu WH, Yang SH, Chan WP. Role of three-dimensional rotational venography in evaluation of the left iliac vein in patients with chronic lower limb edema. *Int J Cardiovasc Imaging* 2011;**27**:923–9.
- 192 Fraser DG, Moody AR, Morgan PS, Martel A. Iliac compression syndrome and recanalization of femoropopliteal and iliac venous thrombosis: a prospective study with magnetic resonance venography. *J Vasc Surg* 2004;**40**:612–9.
- 193 Marston W, Fish D, Unger J, Keagy B. Incidence of and risk factors for ilio caval venous obstruction in patients with active or healed venous leg ulcers. *J Vasc Surg* 2011;**53**:1303–8.
- 194 Depalma RG, Kowallek DL, Barcia TC, Cafferata HT. Target selection for surgical intervention in severe chronic venous insufficiency: comparison of duplex scanning and phlebography. *J Vasc Surg* 2000;**32**:913–20.
- 195 Raju S, Furrh JB, Neglen P. Diagnosis and treatment of venous lymphedema. *J Vasc Surg* 2012;**55**:141–9.
- 196 Raju S, Neglen P. High prevalence of nonthrombotic iliac vein lesions in chronic venous disease: a permissive role in pathogenicity. *J Vasc Surg* 2006;**44**:136–43.
- 197 Neglen P, Raju S. Intravascular ultrasound scan evaluation of the obstructed vein. *J Vasc Surg* 2002;**35**:694–700.
- 198 Forauer AR, Gemmete JJ, Dasika NL, Cho KJ, Williams DM. Intravascular ultrasound in the diagnosis and treatment of iliac vein compression (May-Thurner) syndrome. *J Vasc Interv Radiol* 2002;**13**:523–7.
- 199 Arnoldussen CW, de Graaf R, Wittens CH, de Haan MW. Value of magnetic resonance venography and computed tomographic venography in lower extremity chronic venous disease. *Phlebology* 2013;**28**(Suppl. 1):169–75.
- 200 Arnoldussen CW, Toonder I, Wittens CH. A novel scoring system for lower-extremity venous pathology analysed using magnetic resonance venography and duplex ultrasound. *Phlebology* 2012;**27**(Suppl. 1):163–70.
- 201 Labropoulos N, Gasparis AP, Pefanis D, Leon Jr LR, Tassiopoulos AK. Secondary chronic venous disease progresses faster than primary. *J Vasc Surg* 2009;**49**:704–10.
- 202 Wittens CH, Bukkems SF, Toonder IT. Abdominal wall venous collaterals: the latent clinical sign for central chronic venous obstruction. *Circulation* 2010;**122**:2089–90.
- 203 Meissner MH, Eklof B, Smith PC, Dalsing MC, DePalma RG, Gloviczki P, et al. Secondary chronic venous disorders. *J Vasc Surg* 2007;**46**(Suppl. S):68S–83S.
- 204 O'Meara S, Martyn-St James M. Foam dressings for venous leg ulcers. *Cochrane Database Syst Rev* 2013;**5**:CD009907.
- 205 O'Meara S, Martyn-St James M. Alginate dressings for venous leg ulcers. *Cochrane Database Syst Rev* 2013;**4**:CD010182.
- 206 Palfreyman S, Nelson EA, Michaels JA. Dressings for venous leg ulcers: systematic review and meta-analysis. *Br Med J* 2007;**335**:244.
- 207 Michaels JA, Campbell B, King B, Palfreyman SJ, Shackley P, Stevenson M. Randomized controlled trial and cost-effectiveness analysis of silver-donating antimicrobial dressings for venous leg ulcers (VULCAN trial). *Br J Surg* 2009;**96**:1147–56.
- 208 O'Meara S, Al-Kurdi D, Ologun Y, Ovington LG. Antibiotics and antiseptics for venous leg ulcers. *Cochrane Database Syst Rev* 2010:CD003557.
- 209 Stacey MC, Jopp-Mckay AG, Rashid P, Hoskin SE, Thompson PJ. The influence of dressings on venous ulcer healing — a randomised trial. *Eur J Vasc Endovasc Surg* 1997;**13**:174–9.
- 210 Couzan S, Leizorovicz A, Laporte S, Mismetti P, Pouget JF, Chapelle C, et al. A randomized double-blind trial of upward progressive versus degressive compressive stockings in patients with moderate to severe chronic venous insufficiency. *J Vasc Surg* 2012;**56**:1344–50.
- 211 Mosti G, Partsch H. Compression stockings with a negative pressure gradient have a more pronounced effect on venous pumping function than graduated elastic compression stockings. *Eur J Vasc Endovasc Surg* 2011;**42**:261–6.
- 212 Mosti G, Mattaliano V, Partsch H. Inelastic compression increases venous ejection fraction more than elastic bandages in patients with superficial venous reflux. *Phlebology* 2008;**23**:287–94.
- 213 Shingler S, Robertson L, Boghossian S, Stewart M. Compression stockings for the initial treatment of varicose veins in patients without venous ulceration. *Cochrane Database Syst Rev* 2011:CD008819.
- 214 Kolbach DN, Sandbrink MW, Neumann HA, Prins MH. Compression therapy for treating stage I and II (Widmer) post-thrombotic syndrome. *Cochrane Database Syst Rev* 2003:CD004177.
- 215 Andreozzi GM, Cordova R, Scomparin MA, Martini R, D'Eri A, Andreozzi F, et al. Effects of elastic stocking on quality of life of patients with chronic venous insufficiency. An Italian pilot study on Triveneto Region. *Int Angiol* 2005;**24**:325–9.
- 216 Carpentier PH, Becker F, Thiney G, Poensin D, Satger B. Acceptability and practicability of elastic compression stockings in the elderly: a randomized controlled evaluation. *Phlebology* 2011;**26**:107–13.
- 217 O'Brien JF, Grace PA, Perry IJ, Hannigan A, Clarke Moloney M, Burke PE. Randomized clinical trial and economic analysis of four-layer compression bandaging for venous ulcers. *Br J Surg* 2003;**90**:794–8.
- 218 Wong IK, Andriessen A, Charles HE, Thompson D, Lee DT, So WK, et al. Randomized controlled trial comparing treatment outcome of two compression bandaging systems and standard care without compression in patients with venous leg ulcers. *J Eur Acad Dermatol Venereol* 2012;**26**:102–10.
- 219 O'Meara S, Cullum N, Nelson A, Dumville JC. Compression for venous leg ulcers. *The Cochrane Library* 2012:CD000265.
- 220 Blecken SR, Villavicencio JL, Kao TC. Comparison of elastic versus nonelastic compression in bilateral venous ulcers: a randomized trial. *J Vasc Surg* 2005;**42**:1150–5.

- 221 Blair SD, Wright DD, Backhouse CM, Riddle E, McCollum CN. Sustained compression and healing of chronic venous ulcers. *Br Med J* 1988;**297**:1159–61.
- 222 Harrison MB, Vandenkerkhof EG, Hopman WM, Graham ID, Carley ME, Nelson EA, et al. The Canadian Bandaging Trial: evidence-informed leg ulcer care and the effectiveness of two compression technologies. *BMC Nurs* 2011;**10**:20.
- 223 Lazareth I, Moffatt C, Dissemond J, Lesne Padiou AS, Truchetet F, Beissert S, et al. Efficacy of two compression systems in the management of VLUs: results of a European RCT. *J Wound Care* 2012;**21**:553–4.
- 224 Franks PJ, Moody M, Moffatt CJ, Hiskett G, Gatto P, Davies C, et al. Randomized trial of two foam dressings in the management of chronic venous ulceration. *Wound Repair Regen* 2007;**15**:197–202.
- 225 Nelson EA, Iglesias CP, Cullum N, Torgerson DJ. Randomized clinical trial of four-layer and short-stretch compression bandages for venous leg ulcers (VenUS I). *Br J Surg* 2004;**91**:1292–9.
- 226 Franks PJ, Moody M, Moffatt CJ, Martin R, Blewett R, Seymour E, et al. Randomized trial of cohesive short-stretch versus four-layer bandaging in the management of venous ulceration. *Wound Repair Regen* 2004;**12**:157–62.
- 227 Polignano R, Bonadeo P, Gasbarro S, Allegra C. A randomised controlled study of four-layer compression versus Unna's Boot for venous ulcers. *J Wound Care* 2004;**13**:21–4.
- 228 Moffatt CJ, McCullagh L, O'Connor T, Doherty DC, Hourican C, Stevens J, et al. Randomized trial of four-layer and two-layer bandage systems in the management of chronic venous ulceration. *Wound Repair Regen* 2003;**11**:166–71.
- 229 Meyer FJ, McGuinness CL, Lagattolla NR, Eastham D, Burnand KG. Randomized clinical trial of three-layer paste and four-layer bandages for venous leg ulcers. *Br J Surg* 2003;**90**:934–40.
- 230 Scriven JM, Taylor LE, Wood AJ, Bell PR, Naylor AR, London NJ. A prospective randomised trial of four-layer versus short stretch compression bandages for the treatment of venous leg ulcers. *Ann R Coll Surg Engl* 1998;**80**:215–20.
- 231 Moffatt CJ, Edwards L, Collier M, Treadwell T, Miller M, Shafer L, et al. A randomised controlled 8-week crossover clinical evaluation of the 3M Coban 2 Layer Compression System versus Profore to evaluate the product performance in patients with venous leg ulcers. *Int Wound J* 2008;**5**:267–79.
- 232 Hirai M, Niimi K, Iwata H, Sugimoto I, Ishibashi H, Ota T, et al. A comparison of interface pressure and stiffness between elastic stockings and bandages. *Phlebology* 2009;**24**:120–4.
- 233 Nelson EA, Bell-Syer SE. Compression for preventing recurrence of venous ulcers. *Cochrane Database Syst Rev* 2012;**8**:CD002303.
- 234 Nelson EA, Harper DR, Prescott RJ, Gibson B, Brown D, Ruckley CV. Prevention of recurrence of venous ulceration: randomized controlled trial of class 2 and class 3 elastic compression. *J Vasc Surg* 2006;**44**:803–8.
- 235 Gohel MS, Barwell JR, Taylor M, Chant T, Foy C, Earnshaw JJ, et al. Long term results of compression therapy alone versus compression plus surgery in chronic venous ulceration (ESCHAR): randomised controlled trial. *Br Med J* 2007;**335**:83.
- 236 van Gent WB, Hop WC, van Praag MC, Mackaay AJ, de Boer EM, Wittens CH. Conservative versus surgical treatment of venous leg ulcers: a prospective, randomized, multicenter trial. *J Vasc Surg* 2006;**44**:563–71.
- 237 Kalodiki E, Ellis M, Kakkos SK, Williams A, Davies AH, Geroulakos G. Immediate hemodynamic effect of the additional use of the SCD EXPRESS Compression System in patients with venous ulcers treated with the four-layer compression bandaging system. *Eur J Vasc Endovasc Surg* 2007;**33**:483–7.
- 238 Smith PC, Sarin S, Hasty J, Scurr JH. Sequential gradient pneumatic compression enhances venous ulcer healing: a randomized trial. *Surgery* 1990;**108**:871–5.
- 239 Kumar S, Samraj K, Nirujogi V, Budnik J, Walker MA. Intermittent pneumatic compression as an adjuvant therapy in venous ulcer disease. *J Tissue Viability* 2002;**12**:42–4.
- 240 McCulloch JM, Marler KC, Neal MB, Phifer TJ. Intermittent pneumatic compression improves venous ulcer healing. *Adv Wound Care* 1994;**7**:22–4.
- 241 Schuler JJ, Maibenco T, Megerman J, Ware M, Montalvo J. Treatment of chronic venous ulcers using sequential gradient intermittent pneumatic compression. *Phlebology* 1996;**11**:111–6.
- 242 Nelson EA, Mani R, Thomas K, Vowden K. Intermittent pneumatic compression for treating venous leg ulcers. *Cochrane Database Syst Rev* 2011:CD001899.
- 243 Nikolovska S, Arsovski A, Damevska K, Gocev G, Pavlova L. Evaluation of two different intermittent pneumatic compression cycle settings in the healing of venous ulcers: a randomized trial. *Med Sci Monit* 2005;**11**:CR337–43.
- 244 Berliner E, Ozbilgin B, Zarin DA. A systematic review of pneumatic compression for treatment of chronic venous insufficiency and venous ulcers. *J Vasc Surg* 2003;**37**:539–44.
- 245 Vanscheidt W, Ukat A, Partsch H. Dose-response of compression therapy for chronic venous edema — higher pressures are associated with greater volume reduction: two randomized clinical studies. *J Vasc Surg* 2009;**49**:395–402.
- 246 O'Donnell MJ, McRae S, Kahn SR, Julian JA, Kearon C, Mackinnon B, et al. Evaluation of a venous-return assist device to treat severe post-thrombotic syndrome (VENOPTS). A randomized controlled trial. *Thromb Haemost* 2008;**99**:623–9.
- 247 Cohen JM, Akl EA, Kahn SR. Pharmacologic and compression therapies for postthrombotic syndrome: a systematic review of randomized controlled trials. *Chest* 2012;**141**:308–20.
- 248 Huang TW, Chen SL, Bai CH, Wu CH, Tam KW. The optimal duration of compression therapy following varicose vein surgery: a meta-analysis of randomized controlled trials. *Eur J Vasc Endovasc Surg* 2013;**45**:397–402.
- 249 Bakker NA, Schieven LW, Bruins RM, van den Berg M, Hissink RJ. Compression stockings after endovenous laser ablation of the great saphenous vein: a prospective randomized controlled trial. *Eur J Vasc Endovasc Surg* 2013;**46**:588–92.
- 250 O'Hare JL, Stephens J, Parkin D, Earnshaw JJ. Randomized clinical trial of different bandage regimens after foam sclerotherapy for varicose veins. *Br J Surg* 2010;**97**:650–6.
- 251 Shouler PJ, Runchman PC. Varicose veins: optimum compression after surgery and sclerotherapy. *Ann R Coll Surg Engl* 1989;**71**:402–4.
- 252 Hamel-Desnos CM, Guias BJ, Desnos PR, Mesgard A. Foam sclerotherapy of the saphenous veins: randomised controlled trial with or without compression. *Eur J Vasc Endovasc Surg* 2010;**39**:500–7.
- 253 Kern P, Ramelet AA, Wutschert R, Hayoz D. Compression after sclerotherapy for telangiectasias and reticular leg veins: a randomized controlled study. *J Vasc Surg* 2007;**45**:1212–6.
- 254 Cavalheri Jr G, de Godoy JM, Belczak CE. Correlation of haemodynamics and ankle mobility with clinical classes of clinical,

- aetiological, anatomical and pathological classification in venous disease. *Phlebology* 2008;**23**:120–4.
- 255 Milic DJ, Zivic SS, Bogdanovic DC, Karanovic ND, Golubovic ZV. Risk factors related to the failure of venous leg ulcers to heal with compression treatment. *J Vasc Surg* 2009;**49**:1242–7.
- 256 Yang D, Vandongen YK, Stacey MC. Effect of exercise on calf muscle pump function in patients with chronic venous disease. *Br J Surg* 1999;**86**:338–41.
- 257 Padberg Jr FT, Johnston MV, Sisto SA. Structured exercise improves calf muscle pump function in chronic venous insufficiency: a randomized trial. *J Vasc Surg* 2004;**39**:79–87.
- 258 Davies JA, Bull RH, Farrelly JJ, Wakelin MJ. A home-based exercise programme improves ankle range of motion in long-term venous ulcer patients. *Phlebology* 2007;**22**:86–9.
- 259 O'Brien J, Edwards H, Stewart I, Gibbs H. A home-based progressive resistance exercise programme for patients with venous leg ulcers: a feasibility study. *Int Wound J* 2013;**10**:389–96.
- 260 Heinen M, Borm G, van der Vleuten C, Evers A, Oostendorp R, van Achterberg T. The Lively Legs self-management programme increased physical activity and reduced wound days in leg ulcer patients: results from a randomized controlled trial. *Int J Nurs Stud* 2012;**49**:151–61.
- 261 Jull A, Parag V, Walker N, Maddison R, Kerse N, Johns T. The prepare pilot RCT of home-based progressive resistance exercises for venous leg ulcers. *J Wound Care* 2009;**18**:497–503.
- 262 Schneidman HM. Treatment of circulatory disorders of the lower extremities. *Calif Med* 1966;**105**:368–70.
- 263 Simon DA, Dix FP, McCollum CN. Management of venous leg ulcers. *Br Med J* 2004;**328**:1358–62.
- 264 Barnes MD, Mani R, Barrett DF, White JE. How to measure changes in oedema in patients with chronic venous ulcers? *Phlebology* 1992;**7**:31–5.
- 265 Dix FP, Reilly B, David MC, Simon D, Dowding E, Ivers L, et al. Effect of leg elevation on healing, venous velocity and ambulatory venous pressure in venous ulceration. *Phlebology* 2005;**20**:87–94.
- 266 Abu-Own A, Scurr JH, Coleridge Smith PD. Effect of leg elevation on the skin microcirculation in chronic venous insufficiency. *J Vasc Surg* 1994;**20**:705–10.
- 267 Fergusson AG, Logan JC. Leg ulcers: assessment of response to certain topical medicaments. *Br Med J* 1961;**1**:871–4.
- 268 Bourne IH. Vertical leg drainage of oedema in treatment of leg ulcers. *Br Med J* 1974;**2**:581–3.
- 269 Finlayson K, Edwards H, Courtney M. Factors associated with recurrence of venous leg ulcers: a survey and retrospective chart review. *Int J Nurs Stud* 2009;**46**:1071–8.
- 270 Brooks J, Ersser SJ, Lloyd A, Ryan TJ. Nurse-led education sets out to improve patient concordance and prevent recurrence of leg ulcers. *J Wound Care* 2004;**13**:111–6.
- 271 Collins L, Seraj S. Diagnosis and treatment of venous ulcers. *Am Fam Physician* 2010;**81**:989–96.
- 272 Reeder S, de Roos KP, de Maeseneer M, Sommer A, Neumann HA. Ulcer recurrence after in-hospital treatment for recalcitrant venous leg ulceration. *Br J Dermatol* 2013;**168**:999–1002.
- 273 Bourne IH. Treatment of leg ulcers. *J R Soc Med* 1992;**85**:733–5.
- 274 Harrington CI. Porcine dermis dressing versus Bisgaard therapy for leg ulcers. *Br Med J* 1976;**2**:641.
- 275 Martinez MJ, Bonfill X, Moreno RM, Vargas E, Capella D. Phlebotonics for venous insufficiency. *Cochrane Database Syst Rev* 2005:CD003229.
- 276 Ramelet AA, Boisseau MR, Allegra C, Nicolaides A, Jaeger K, Carpentier P, et al. Veno-active drugs in the management of chronic venous disease. An international consensus statement: current medical position, prospective views and final resolution. *Clin Hemorheol Microcirc* 2005;**33**:309–19.
- 277 Pittler MH, Ernst E. Horse chestnut seed extract for chronic venous insufficiency. *Cochrane Database Syst Rev* 2012;**11**:CD003230.
- 278 Barbe R, Amiel M. Pharmacodynamic properties and therapeutic efficacy of Daflon 500 mg. *Phlebology* 1992;**7**:41–4.
- 279 Blume J, Langenbahn H, de Champvallins M. Quantification of oedema using the volometer technique: therapeutic application of Daflon 500 mg in chronic venous insufficiency. *Phlebology* 1992;**7**:37–40.
- 280 Galley P, Thiollet M. A double-blind, placebo-controlled trial of a new veno-active flavonoid fraction (S 5682) in the treatment of symptomatic capillary fragility. *Int Angiol* 1993;**12**:69–72.
- 281 Gilly R, Pillion G, Frileux C. Evaluation of a new veno-active micronized flavonoid fraction (S5682) in symptomatic disturbances of the venolymphatic circulation of the lower limb. A double-blinded, placebo-controlled trial. *Phlebology* 1994;**9**:67–70.
- 282 Allaert FA. Meta-analysis of the impact of the principal venoactive drugs agents on malleolar venous edema. *Int Angiol* 2012;**31**:310–5.
- 283 Danielsson G, Jungbeck C, Peterson K, Norgren L. A randomised controlled trial of micronised purified flavonoid fraction vs placebo in patients with chronic venous disease. *Eur J Vasc Endovasc Surg* 2002;**23**:73–6.
- 284 Gohel MS, Davies AH. Pharmacological agents in the treatment of venous disease: an update of the available evidence. *Curr Vasc Pharmacol* 2009;**7**:303–8.
- 285 Rabe E, Jaeger KA, Bulitta M, Pannier F. Calcium dobesilate in patients suffering from chronic venous insufficiency: a double-blind, placebo-controlled, clinical trial. *Phlebology* 2011;**26**:162–8.
- 286 Rabe E, Stucker M, Esperester A, Schafer E, Ottlinger B. Efficacy and tolerability of a red-vine-leaf extract in patients suffering from chronic venous insufficiency — results of a double-blind placebo-controlled study. *Eur J Vasc Endovasc Surg* 2011;**41**:540–7.
- 287 Jull AB, Arroll B, Parag V, Waters J. Pentoxifylline for treating venous leg ulcers. *Cochrane Database Syst Rev* 2012;**12**:CD001733.
- 288 Dale JJ, Ruckley CV, Harper DR, Gibson B, Nelson EA, Prescott RJ. Randomised, double blind placebo controlled trial of pentoxifylline in the treatment of venous leg ulcers. *Br Med J* 1999;**319**:875–8.
- 289 Falanga V, Fujitani RM, Diaz C, Hunter G, Jorizzo J, Lawrence PF, et al. Systemic treatment of venous leg ulcers with high doses of pentoxifylline: efficacy in a randomized, placebo-controlled trial. *Wound Repair Regen* 1999;**7**:208–13.
- 290 Nelson EA, Prescott RJ, Harper DR, Gibson B, Brown D, Ruckley CV. A factorial, randomized trial of pentoxifylline or placebo, four-layer or single-layer compression, and knitted viscose or hydrocolloid dressings for venous ulcers. *J Vasc Surg* 2007;**45**:134–41.
- 291 Layton AM, Ibbotson SH, Davies JA, Goodfield MJ. Randomised trial of oral aspirin for chronic venous leg ulcers. *Lancet* 1994;**344**:164–5.

- 292 Ibbotson SH, Layton AM, Davies JA, Goodfield MJ. The effect of aspirin on haemostatic activity in the treatment of chronic venous leg ulceration. *Br J Dermatol* 1995;**132**:422–6.
- 293 del Rio Sola ML, Antonio J, Fajardo G, Vaquero Puerta C. Influence of aspirin therapy in the ulcer associated with chronic venous insufficiency. *Ann Vasc Surg* 2012;**26**:620–9.
- 294 Wilkinson EA, Hawke CI. Does oral zinc aid the healing of chronic leg ulcers? A systematic literature review. *Arch Dermatol* 1998;**134**:1556–60.
- 295 Andreozzi GM. Sulodexide in the treatment of chronic venous disease. *Am J Cardiovasc Drugs* 2012;**12**:73–81.
- 296 Leach MJ, Pincombe J, Foster G. Clinical efficacy of horsechestnut seed extract in the treatment of venous ulceration. *J Wound Care* 2006;**15**:159–67.
- 297 Guilhou JJ, Dereure O, Marzin L, Ouvry P, Zuccarelli F, Debure C, et al. Efficacy of Daflon 500 mg in venous leg ulcer healing: a double-blind, randomized, controlled versus placebo trial in 107 patients. *Angiology* 1997;**48**:77–85.
- 298 Glinski W, Chodyncka B, Roszkiewicz J, Bogdanowski T, Lecewicz-Torun B, Kaszuba A, et al. The beneficial augmentative effect of micronized purified flavonoid fraction (MPFF) on the healing of leg ulcers: an open, multicentre, controlled randomised study. *Phlebology* 1999;**14**:151–7.
- 299 Roztocil K, Stvrtinova V, Strejcek J. Efficacy of a 6-month treatment with Daflon 500 mg in patients with venous leg ulcers associated with chronic venous insufficiency. *Int Angiol* 2003;**22**:24–31.
- 300 Scallan C, Bell-Syer SE, Aziz Z. Flavonoids for treating venous leg ulcers. *Cochrane Database Syst Rev* 2013;**5**:CD006477.
- 301 Coleridge-Smith P, Lok C, Ramelet AA. Venous leg ulcer: a meta-analysis of adjunctive therapy with micronized purified flavonoid fraction. *Eur J Vasc Endovasc Surg* 2005;**30**:198–208.
- 302 Bukhari RH, Lohr JM, Paget DS, Hearn AT, Cranley RD. Evaluation of lidocaine as an analgesic when added to hypertonic saline for sclerotherapy. *J Vasc Surg* 1999;**29**:479–83.
- 303 Kern P, Ramelet AA, Wutschert R, Mazzolai L. A double-blind, randomized study comparing pure chromated glycerin with chromated glycerin with 1% lidocaine and epinephrine for sclerotherapy of telangiectasias and reticular veins. *Dermatol Surg* 2011;**37**:1590–4.
- 304 Guex JJ, Allaert FA, Gillet JL, Chleir F. Immediate and midterm complications of sclerotherapy: report of a prospective multicenter registry of 12,173 sclerotherapy sessions. *Dermatol Surg* 2005;**31**:123–8.
- 305 Goldman MP, Sadick NS, Weiss RA. Cutaneous necrosis, telangiectatic matting, and hyperpigmentation following sclerotherapy. Etiology, prevention, and treatment. *Dermatol Surg* 1995;**21**:19–29.
- 306 Cavezzi A, Parsi K. Complications of foam sclerotherapy. *Phlebology* 2012;**27**(Suppl. 1):46–51.
- 307 Kahle B, Leng K. Efficacy of sclerotherapy in varicose veins – prospective, blinded, placebo-controlled study. *Dermatol Surg* 2004;**30**:723–8.
- 308 Zhang J, Jing Z, Schliephake DE, Otto J, Malouf GM, Gu YQ. Efficacy and safety of Aethoxysklerol(R) (polidocanol) 0.5%, 1% and 3% in comparison with placebo solution for the treatment of varicose veins of the lower extremities in Chinese patients (ESA-China Study). *Phlebology* 2012;**27**:184–90.
- 309 Tisi PV, Beverley C, Rees A. Injection sclerotherapy for varicose veins. *Cochrane Database Syst Rev* 2006:CD001732.
- 310 Schwartz L, Maxwell H. Sclerotherapy for lower limb telangiectasias. *Cochrane Database Syst Rev* 2011:CD008826.
- 311 Rabe E, Schliephake D, Otto J, Breu FX, Pannier F. Sclerotherapy of telangiectases and reticular veins: a double-blind, randomized, comparative clinical trial of polidocanol, sodium tetradecyl sulphate and isotonic saline (EASI study). *Phlebology* 2010;**25**:124–31.
- 312 Hobbs JT. Surgery and sclerotherapy in the treatment of varicose veins. A random trial. *Arch Surg* 1974;**109**:793–6.
- 313 Beresford SA, Chant AD, Jones HO, Piachaud D, Weddell JM. Varicose veins: a comparison of surgery and infection/compression sclerotherapy. Five-year follow-up. *Lancet* 1978;**1**:921–4.
- 314 Rigby KA, Palfreyman SJ, Beverley C, Michaels JA. Surgery versus sclerotherapy for the treatment of varicose veins. *Cochrane Database Syst Rev* 2004:CD004980.
- 315 de Roos KP, Nieman FH, Neumann HA. Ambulatory phlebectomy versus compression sclerotherapy: results of a randomized controlled trial. *Dermatol Surg* 2003;**29**:221–6.
- 316 Hayden A, Holdsworth J. Complications following re-exploration of the groin for recurrent varicose veins. *Ann R Coll Surg Engl* 2001;**83**:272–3.
- 317 Hamel-Desnos C, Desnos P, Wollmann JC, Ouvry P, Mako S, Allaert FA. Evaluation of the efficacy of polidocanol in the form of foam compared with liquid form in sclerotherapy of the greater saphenous vein: initial results. *Dermatol Surg* 2003;**29**:1170–5.
- 318 Rabe E, Otto J, Schliephake D, Pannier F. Efficacy and safety of great saphenous vein sclerotherapy using standardised polidocanol foam (ESAF): a randomised controlled multicentre clinical trial. *Eur J Vasc Endovasc Surg* 2008;**35**:238–45.
- 319 Ouvry P, Allaert FA, Desnos P, Hamel-Desnos C. Efficacy of polidocanol foam versus liquid in sclerotherapy of the great saphenous vein: a multicentre randomised controlled trial with a 2-year follow-up. *Eur J Vasc Endovasc Surg* 2008;**36**:366–70.
- 320 Ukritmanoroat T. Comparison of efficacy and safety between foam sclerotherapy and conventional sclerotherapy: a controlled clinical trial. *J Med Assoc Thai* 2011;**94**(Suppl. 2):S35–40.
- 321 King T, Coulomb G, Goldman A, Sheen V, McWilliams S, Guptan RC. Experience with concomitant ultrasound-guided foam sclerotherapy and endovenous laser treatment in chronic venous disorder and its influence on Health Related Quality of Life: interim analysis of more than 1000 consecutive procedures. *Int Angiol* 2009;**28**:289–97.
- 322 Bountouroglou DG, Azzam M, Kakkos SK, Pathmarajah M, Young P, Geroulakos G. Ultrasound-guided foam sclerotherapy combined with sapheno-femoral ligation compared to surgical treatment of varicose veins: early results of a randomised controlled trial. *Eur J Vasc Endovasc Surg* 2006;**31**:93–100.
- 323 Kakkos SK, Bountouroglou DG, Azzam M, Kalodiki E, Daskalopoulos M, Geroulakos G. Effectiveness and safety of ultrasound-guided foam sclerotherapy for recurrent varicose veins: immediate results. *J Endovasc Ther* 2006;**13**:357–64.
- 324 Darvall KA, Bate GR, Adam DJ, Silverman SH, Bradbury AW. Duplex ultrasound outcomes following ultrasound-guided foam sclerotherapy of symptomatic recurrent great saphenous varicose veins. *Eur J Vasc Endovasc Surg* 2011;**42**:107–14.
- 325 Cavezzi A, Frullini A, Ricci S, Tessari L. Treatment of varicose veins by foam sclerotherapy: two clinical series. *Phlebology* 2002;**17**:13–8.
- 326 Smith PC. Chronic venous disease treated by ultrasound guided foam sclerotherapy. *Eur J Vasc Endovasc Surg* 2006;**32**:577–83.

- 327 Myers KA, Jolley D, Clough A, Kirwan J. Outcome of ultrasound-guided sclerotherapy for varicose veins: medium-term results assessed by ultrasound surveillance. *Eur J Vasc Endovasc Surg* 2007;**33**:116–21.
- 328 Rasmussen LH, Lawaetz M, Bjoern L, Vennits B, Blemings A, Eklof B. Randomized clinical trial comparing endovenous laser ablation, radiofrequency ablation, foam sclerotherapy and surgical stripping for great saphenous varicose veins. *Br J Surg* 2011;**98**:1079–87.
- 329 Shadid N, Ceulen R, Nelemans P, Dirksen C, Veraart J, Schurink GW, et al. Randomized clinical trial of ultrasound-guided foam sclerotherapy versus surgery for the incompetent great saphenous vein. *Br J Surg* 2012;**99**:1062–70.
- 330 Rathbun S, Norris A, Stoner J. Efficacy and safety of endovenous foam sclerotherapy: meta-analysis for treatment of venous disorders. *Phlebology* 2012;**27**:105–17.
- 331 Gonzalez-Zeh R, Armisen R, Barahona S. Endovenous laser and echo-guided foam ablation in great saphenous vein reflux: one-year follow-up results. *J Vasc Surg* 2008;**48**:940–6.
- 332 Bradbury AW, Bate G, Pang K, Darvall KA, Adam DJ. Ultrasound-guided foam sclerotherapy is a safe and clinically effective treatment for superficial venous reflux. *J Vasc Surg* 2010;**52**:939–45.
- 333 Rabe E, Breu F, Cavezzi A, Smith PC, Frullini A, Gillet J, et al. European guidelines for sclerotherapy in chronic venous disorders. *Phlebology* 2013.
- 334 Darvall KA, Bate GR, Adam DJ, Silverman SH, Bradbury AW. Ultrasound-guided foam sclerotherapy for the treatment of chronic venous ulceration: a preliminary study. *Eur J Vasc Endovasc Surg* 2009;**38**:764–9.
- 335 Kulkarni SR, Slim FJ, Emerson LG, Davies C, Bulbulia RA, Whyman MR, et al. Effect of foam sclerotherapy on healing and long-term recurrence in chronic venous leg ulcers. *Phlebology* 2013;**28**:140–6.
- 336 Parsi K. Catheter-directed sclerotherapy. *Phlebology* 2009;**24**:98–107.
- 337 Cavezzi A, Tessari L. Foam sclerotherapy techniques: different gases and methods of preparation, catheter versus direct injection. *Phlebology* 2009;**24**:247–51.
- 338 Asciutto G, Lindblad B. Catheter-directed foam sclerotherapy treatment of saphenous vein incompetence. *Vasa* 2012;**41**:120–4.
- 339 Tan VK, Abidin SZ, Tan SG. Medium-term results of ultrasonography-guided, catheter-assisted foam sclerotherapy of the long saphenous vein for treatment of varicose veins. *Singapore Med J* 2012;**53**:91–4.
- 340 Kaudewitz P, Klovekorn W, Rother W. Effective treatment of leg vein telangiectasia with a new 940 nm diode laser. *Dermatol Surg* 2001;**27**:101–6.
- 341 Eremia S, Li C, Umar SH. A side-by-side comparative study of 1064 nm Nd:YAG, 810 nm diode and 755 nm alexandrite lasers for treatment of 0.3–3 mm leg veins. *Dermatol Surg* 2002;**28**:224–30.
- 342 Weiss RA, Weiss MA. Early clinical results with a multiple synchronized pulse 1064 NM laser for leg telangiectasias and reticular veins. *Dermatol Surg* 1999;**25**:399–402.
- 343 Lupton JR, Alster TS, Romero P. Clinical comparison of sclerotherapy versus long-pulsed Nd:YAG laser treatment for lower extremity telangiectases. *Dermatol Surg* 2002;**28**:694–7.
- 344 Tepavcevic B, Matic P, Radak D. Comparison of sclerotherapy, laser, and radiowave coagulation in treatment of lower extremity telangiectasias. *J Cosmet Laser Ther* 2012;**14**:239–42.
- 345 Dover JS, Sadick NS, Goldman MP. The role of lasers and light sources in the treatment of leg veins. *Dermatol Surg* 1999;**25**:328–35.
- 346 Klein A, Baumler W, Koller M, Shafirstein G, Kohl EA, Landthaler M, et al. Indocyanine green-augmented diode laser therapy of telangiectatic leg veins: a randomized controlled proof-of-concept trial. *Lasers Surg Med* 2012;**44**:369–76.
- 347 Sadick NS, Weiss RA, Goldman MP. Advances in laser surgery for leg veins: bimodal wavelength approach to lower extremity vessels, new cooling techniques, and longer pulse durations. *Dermatol Surg* 2002;**28**:16–20.
- 348 McDaniel DH, Ash K, Lord J, Newman J, Adrian RM, Zukowski M. Laser therapy of spider leg veins: clinical evaluation of a new long pulsed alexandrite laser. *Dermatol Surg* 1999;**25**:52–8.
- 349 Boné SC. Tratamiento Endoluminal de las varices con laser de diodo. Estudio preliminar. *Patologia Vasculare* 1999;**5**:32–9.
- 350 Milleret R, Huot L, Nicolini P, Creton D, Roux AS, Decullier E, et al. Great saphenous vein ablation with steam injection: results of a multicentre study. *Eur J Vasc Endovasc Surg* 2013;**45**:391–6.
- 351 Elias S, Raines JK. Mechanochemical tumescentless endovenous ablation: final results of the initial clinical trial. *Phlebology* 2012;**27**:67–72.
- 352 Almeida JJ, Javier JJ, Mackay E, Bautista C, Proebstle TM. First human use of cyanoacrylate adhesive for treatment of saphenous vein incompetence. *J Vasc Surg* 2013;**1**:174–80.
- 353 Vuylsteke ME, Martinelli T, Van Dorpe J, Roelens J, Mordon S, Fourneau I. Endovenous laser ablation: the role of intraluminal blood. *Eur J Vasc Endovasc Surg* 2011;**42**:120–6.
- 354 van den Bos RR, Milleret R, Neumann M, Nijsten T. Proof-of-principle study of steam ablation as novel thermal therapy for saphenous varicose veins. *J Vasc Surg* 2011;**53**:181–6.
- 355 van den Bos R, Arends L, Kockaert M, Neumann M, Nijsten T. Endovenous therapies of lower extremity varicosities: a meta-analysis. *J Vasc Surg* 2009;**49**:230–9.
- 356 Siribumrungwong B, Noorit P, Wilasrusmee C, Attia J, Thakkinstian A. A systematic review and meta-analysis of randomised controlled trials comparing endovenous ablation and surgical intervention in patients with varicose vein. *Eur J Vasc Endovasc Surg* 2012;**44**:214–23.
- 357 Brar R, Nordon IM, Hinchliffe RJ, Loftus IM, Thompson MM. Surgical management of varicose veins: meta-analysis. *Vascular* 2010;**18**:205–20.
- 358 Murad MH, Coto-Yglesias F, Zumaeta-Garcia M, Elamin MB, Duggirala MK, Erwin PJ, et al. A systematic review and meta-analysis of the treatments of varicose veins. *J Vasc Surg* 2011;**53**:49S–65S.
- 359 Nesbitt C, Eifell RK, Coyne P, Badri H, Bhattacharya V, Stansby G. Endovenous ablation (radiofrequency and laser) and foam sclerotherapy versus conventional surgery for great saphenous vein varices. *Cochrane Database Syst Rev* 2011: CD005624.
- 360 Tellings SS, Ceulen RP, Sommer A. Surgery and endovenous techniques for the treatment of small saphenous varicose veins: a review of the literature. *Phlebology* 2011;**26**:179–84.
- 361 Carradice D, Mekako AI, Mazari FA, Samuel N, Hatfield J, Chetter IC. Clinical and technical outcomes from a randomized clinical trial of endovenous laser ablation compared with conventional surgery for great saphenous varicose veins. *Br J Surg* 2011;**98**:1117–23.

- 362 Carradice D, Mekako AI, Mazari FA, Samuel N, Hatfield J, Chetter IC. Randomized clinical trial of endovenous laser ablation compared with conventional surgery for great saphenous varicose veins. *Br J Surg* 2011;**98**:501–10.
- 363 Christenson JT, Gueddi S, Gemayel G, Bounameaux H. Prospective randomized trial comparing endovenous laser ablation and surgery for treatment of primary great saphenous varicose veins with a 2-year follow-up. *J Vasc Surg* 2010;**52**:1234–41.
- 364 Darwood RJ, Theivacumar N, Dellagrammaticas D, Mavor AI, Gough MJ. Randomized clinical trial comparing endovenous laser ablation with surgery for the treatment of primary great saphenous varicose veins. *Br J Surg* 2008;**95**:294–301.
- 365 Disselhoff BC, der Kinderen DJ, Kelder JC, Moll FL. Randomized clinical trial comparing endovenous laser with cryostripping for great saphenous varicose veins. *Br J Surg* 2008;**95**:1232–8.
- 366 Disselhoff BC, der Kinderen DJ, Kelder JC, Moll FL. Five-year results of a randomized clinical trial comparing endovenous laser ablation with cryostripping for great saphenous varicose veins. *Br J Surg* 2011;**98**:1107–11.
- 367 Kalteis M, Berger I, Messie-Werndl S, Pistrich R, Schimetta W, Polz W, et al. High ligation combined with stripping and endovenous laser ablation of the great saphenous vein: early results of a randomized controlled study. *J Vasc Surg* 2008;**47**:822–9.
- 368 Pronk P, Gauw SA, Mooij MC, Gaastra MT, Lawson JA, van Goethem AR, et al. Randomised controlled trial comparing sapheno-femoral ligation and stripping of the great saphenous vein with endovenous laser ablation (980 nm) using local tumescent anaesthesia: one year results. *Eur J Vasc Endovasc Surg* 2010;**40**:649–56.
- 369 Rasmussen LH, Bjoern L, Lawaetz M, Blemings A, Lawaetz B, Eklof B. Randomized trial comparing endovenous laser ablation of the great saphenous vein with high ligation and stripping in patients with varicose veins: short-term results. *J Vasc Surg* 2007;**46**:308–15.
- 370 Rasmussen LH, Bjoern L, Lawaetz M, Lawaetz B, Blemings A, Eklof B. Randomised clinical trial comparing endovenous laser ablation with stripping of the great saphenous vein: clinical outcome and recurrence after 2 years. *Eur J Vasc Endovasc Surg* 2010;**39**:630–5.
- 371 Helmy ElKaffas K, ElKashef O, ElBaz W. Great saphenous vein radiofrequency ablation versus standard stripping in the management of primary varicose veins — a randomized clinical trial. *Angiology* 2011;**62**:49–54.
- 372 Lurie F, Creton D, Eklof B, Kabnick LS, Kistner RL, Pichot O, et al. Prospective randomised study of endovenous radiofrequency obliteration (closure) versus ligation and vein stripping (EVOLVEs): two-year follow-up. *Eur J Vasc Endovasc Surg* 2005;**29**:67–73.
- 373 Perala J, Rautio T, Biancari F, Ohtonen P, Wiik H, Heikkinen T, et al. Radiofrequency endovenous obliteration versus stripping of the long saphenous vein in the management of primary varicose veins: 3-year outcome of a randomized study. *Ann Vasc Surg* 2005;**19**:669–72.
- 374 Rautio T, Ohinmaa A, Perala J, Ohtonen P, Heikkinen T, Wiik H, et al. Endovenous obliteration versus conventional stripping operation in the treatment of primary varicose veins: a randomized controlled trial with comparison of the costs. *J Vasc Surg* 2002;**35**:958–65.
- 375 Stotter L, Schaaf I, Bockelbrink A. Radiofrequency obliteration, invagination or cryo stripping: which is the best tolerated treatment by the patients? *Phlebology* 2005;**34**:19–24.
- 376 Lurie F, Creton D, Eklof B, Kabnick LS, Kistner RL, Pichot O, et al. Prospective randomized study of endovenous radiofrequency obliteration (closure procedure) versus ligation and stripping in a selected patient population (EVOLVEs Study). *J Vasc Surg* 2003;**38**:207–14.
- 377 Hinchliffe RJ, Ubhi J, Beech A, Ellison J, Braithwaite BD. A prospective randomised controlled trial of VNUS closure versus surgery for the treatment of recurrent long saphenous varicose veins. *Eur J Vasc Endovasc Surg* 2006;**31**:212–8.
- 378 Subramonia S, Lees T. Randomized clinical trial of radiofrequency ablation or conventional high ligation and stripping for great saphenous varicose veins. *Br J Surg* 2010;**97**:328–36.
- 379 Vuylsteke M, De Bo T, Dompe G, Di Crisci D, Abbad C, Mordon S. Endovenous laser treatment: is there a clinical difference between using a 1500 nm and a 980 nm diode laser? A multicenter randomised clinical trial. *Int Angiol* 2011;**30**:327–34.
- 380 Vuylsteke ME, Thomis S, Mahieu P, Mordon S, Fourneau I. Endovenous laser ablation of the great saphenous vein using a bare fibre versus a tulip fibre: a randomised clinical trial. *Eur J Vasc Endovasc Surg* 2012;**44**:587–92.
- 381 Almeida JI, Kaufman J, Gockeritz O, Chopra P, Evans MT, Hoheim DF, et al. Radiofrequency endovenous ClosureFAST versus laser ablation for the treatment of great saphenous reflux: a multicenter, single-blinded, randomized study (RECOVERY study). *J Vasc Interv Radiol* 2009;**20**:752–9.
- 382 Gale SS, Lee JN, Walsh ME, Wojnarowski DL, Comerota AJ. A randomized, controlled trial of endovenous thermal ablation using the 810-nm wavelength laser and the ClosurePLUS radiofrequency ablation methods for superficial venous insufficiency of the great saphenous vein. *J Vasc Surg* 2010;**52**:645–50.
- 383 Goode SD, Chowdhury A, Crockett M, Beech A, Simpson R, Richards T, et al. Laser and radiofrequency ablation study (LARA study): a randomised study comparing radiofrequency ablation and endovenous laser ablation (810 nm). *Eur J Vasc Endovasc Surg* 2010;**40**:246–53.
- 384 Nordon IM, Hinchliffe RJ, Brar R, Moxey P, Black SA, Thompson MM, et al. A prospective double-blind randomized controlled trial of radiofrequency versus laser treatment of the great saphenous vein in patients with varicose veins. *Ann Surg* 2011;**254**:876–81.
- 385 Shepherd AC, Gohel MS, Brown LC, Metcalfe MJ, Hamish M, Davies AH. Randomized clinical trial of VNUS ClosureFAST radiofrequency ablation versus laser for varicose veins. *Br J Surg* 2010;**97**:810–8.
- 386 Doganci S, Yildirim V, Demirkilic U. Does puncture site affect the rate of nerve injuries following endovenous laser ablation of the small saphenous veins? *Eur J Vasc Endovasc Surg* 2011;**41**:400–5.
- 387 Carradice D, Samuel N, Wallace T, Mazari FA, Hatfield J, Chetter I. Comparing the treatment response of great saphenous and small saphenous vein incompetence following surgery and endovenous laser ablation: a retrospective cohort study. *Phlebology* 2012;**27**:128–34.
- 388 Samuel N, Carradice D, Wallace T, Mekako A, Hatfield J, Chetter I. Randomized clinical trial of endovenous laser ablation versus conventional surgery for small saphenous varicose veins. *Ann Surg* 2013;**257**:419–26.
- 389 Samuel N, Wallace T, Carradice D, Shahin Y, Mazari FA, Chetter IC. Endovenous laser ablation in the treatment of small saphenous varicose veins: does site of access influence early outcomes? *Vasc Endovascular Surg* 2012;**46**:310–4.

- 390 Biswas S, Clark A, Shields DA. Randomised clinical trial of the duration of compression therapy after varicose vein surgery. *Eur J Vasc Endovasc Surg* 2007;**33**:631–7.
- 391 de Medeiros CA, Luccas GC. Comparison of endovenous treatment with an 810 nm laser versus conventional stripping of the great saphenous vein in patients with primary varicose veins. *Dermatol Surg* 2005;**31**:1685–94.
- 392 Vuylsteke M, van den Bussche D, Audenaert EA, Lissens P. Endovenous laser obliteration for the treatment of primary varicose veins. *Phlebology* 2006;**21**:80–7.
- 393 Prince EA, Soares GM, Silva M, Taner A, Ahn S, Dubel GJ, et al. Impact of laser fiber design on outcome of endovenous ablation of lower-extremity varicose veins: results from a single practice. *Cardiovasc Intervent Radiol* 2011;**34**:536–41.
- 394 Schwarz T, von Hodenberg E, Furtwangler C, Rastan A, Zeller T, Neumann FJ. Endovenous laser ablation of varicose veins with the 1470-nm diode laser. *J Vasc Surg* 2010;**51**:1474–8.
- 395 Puggioni A, Kalra M, Carmo M, Mozes G, Gloviczki P. Endovenous laser therapy and radiofrequency ablation of the great saphenous vein: analysis of early efficacy and complications. *J Vasc Surg* 2005;**42**:488–93.
- 396 Proebstle TM, Moehler T, Gul D, Herdemann S. Endovenous treatment of the great saphenous vein using a 1,320 nm Nd:YAG laser causes fewer side effects than using a 940 nm diode laser. *Dermatol Surg* 2005;**31**:1678–83.
- 397 Lawrence PF, Chandra A, Wu M, Rigberg D, DeRubertis B, Gelabert H, et al. Classification of proximal endovenous closure levels and treatment algorithm. *J Vasc Surg* 2010;**52**:388–93.
- 398 Knipp BS, Blackburn SA, Bloom JR, Fellows E, Laforge W, Pfeifer JR, et al. Endovenous laser ablation: venous outcomes and thrombotic complications are independent of the presence of deep venous insufficiency. *J Vasc Surg* 2008;**48**:1538–45.
- 399 Mozes G, Kalra M, Carmo M, Swenson L, Gloviczki P. Extension of saphenous thrombus into the femoral vein: a potential complication of new endovenous ablation techniques. *J Vasc Surg* 2005;**41**:130–5.
- 400 Pannier F, Rabe E, Rits J, Kadiss A, Maurins U. Endovenous laser ablation of great saphenous veins using a 1470 nm diode laser and the radial fibre – follow-up after six months. *Phlebology* 2011;**26**:35–9.
- 401 Proebstle TM, Vago B, Alm J, Gockeritz O, Lebard C, Pichot O. Treatment of the incompetent great saphenous vein by endovenous radiofrequency powered segmental thermal ablation: first clinical experience. *J Vasc Surg* 2008;**47**:151–6.
- 402 Goldman MP, Mauricio M, Rao J. Intravascular 1320-nm laser closure of the great saphenous vein: a 6- to 12-month follow-up study. *Dermatol Surg* 2004;**30**:1380–5.
- 403 Pannier F, Rabe E, Maurins U. First results with a new 1470-nm diode laser for endovenous ablation of incompetent saphenous veins. *Phlebology* 2009;**24**:26–30.
- 404 Vuylsteke ME, Mordon SR. Endovenous laser ablation: a review of mechanisms of action. *Ann Vasc Surg* 2012;**26**:424–33.
- 405 Marsden G, Perry M, Kelley K, Davies AH, Guideline Development G. Diagnosis and management of varicose veins in the legs: summary of NICE guidance. *Br Med J* 2013;**347**:f4279.
- 406 National Institute for Health and Care Excellence NICE. Varicose veins in the legs: the diagnosis and management of varicose veins. *NICE Clinical Guideline* 2013:168.
- 407 van Rij AM, Chai J, Hill GB, Christie RA. Incidence of deep vein thrombosis after varicose vein surgery. *Br J Surg* 2004;**91**:1582–5.
- 408 Geerts WH, Bergqvist D, Pineo GF, Heit JA, Samama CM, Lassen MR, et al. Prevention of venous thromboembolism: American College of Chest Physicians Evidence-Based Clinical Practice Guidelines (8th ed.). *Chest* 2008;**133**:381S–453S.
- 409 Caprini JA. Risk assessment as a guide for the prevention of the many faces of venous thromboembolism. *Am J Surg* 2010;**199**:S3–10.
- 410 Jia X, Mowatt G, Burr JM, Cassar K, Cook J, Fraser C. Systematic review of foam sclerotherapy for varicose veins. *Br J Surg* 2007;**94**:925–36.
- 411 Sarvananthan T, Shepherd AC, Willenberg T, Davies AH. Neurological complications of sclerotherapy for varicose veins. *J Vasc Surg* 2012;**55**:243–51.
- 412 Raymond-Martimbeau P. Transient adverse events positively associated with patent foramen ovale after ultrasound-guided foam sclerotherapy. *Phlebology* 2009;**24**:114–9.
- 413 Parsi K. Venous gas embolism during foam sclerotherapy of saphenous veins despite recommended treatment modifications. *Phlebology* 2011;**26**:140–7.
- 414 Figueiredo M, Araujo S, Barros Jr N, Miranda Jr F. Results of surgical treatment compared with ultrasound-guided foam sclerotherapy in patients with varicose veins: a prospective randomised study. *Eur J Vasc Endovasc Surg* 2009;**38**:758–63.
- 415 Wright D, Gobin JP, Bradbury A, Coleridge-Smith P, Spoelstra H, Berridge D, et al. Varisolve polidocanol microfoam compared with surgery or sclerotherapy in the management of varicose veins in the presence of trunk vein incompetence: European randomized controlled trial. *Phlebology* 2006;**21**:180–90.
- 416 Kalodiki E, Lattimer CR, Azzam M, Shawish E, Bountouroglou D, Geroulakos G. Long-term results of a randomized controlled trial on ultrasound-guided foam sclerotherapy combined with saphenofemoral ligation vs standard surgery for varicose veins. *J Vasc Surg* 2012;**55**:451–7.
- 417 Darke SG, Baker SJ. Ultrasound-guided foam sclerotherapy for the treatment of varicose veins. *Br J Surg* 2006;**93**:969–74.
- 418 van Eekeren RR, Boersma D, Elias S, Holewijn S, Werson DA, de Vries JP, et al. Endovenous mechanochemical ablation of great saphenous vein incompetence using the ClariVein device: a safety study. *J Endovasc Ther* 2011;**18**:328–34.
- 419 Michaels JA, Campbell WB, Brazier JE, MacIntyre JB, Palfreyman SJ, Ratcliffe J, et al. Randomised clinical trial, observational study and assessment of cost-effectiveness of the treatment of varicose veins (REACTIV trial). *Health Technol Assess* 2006;**10**. 1–196, iii–iv.
- 420 Michaels JA, Brazier JE, Campbell WB, MacIntyre JB, Palfreyman SJ, Ratcliffe J. Randomized clinical trial comparing surgery with conservative treatment for uncomplicated varicose veins. *Br J Surg* 2006;**93**:175–81.
- 421 MacKenzie RK, Allan PL, Ruckley CV, Bradbury AW. The effect of long saphenous vein stripping on deep venous reflux. *Eur J Vasc Endovasc Surg* 2004;**28**:104–7.
- 422 Sam RC, MacKenzie RK, Paisley AM, Ruckley CV, Bradbury AW. The effect of superficial venous surgery on generic health-related quality of life. *Eur J Vasc Endovasc Surg* 2004;**28**:253–6.
- 423 Winterborn RJ, Foy C, Earnshaw JJ. Causes of varicose vein recurrence: late results of a randomized controlled trial of stripping the long saphenous vein. *J Vasc Surg* 2004;**40**:634–9.
- 424 Dwerryhouse S, Davies B, Harradine K, Earnshaw JJ. Stripping the long saphenous vein reduces the rate of reoperation for

- recurrent varicose veins: five-year results of a randomized trial. *J Vasc Surg* 1999;**29**:589–92.
- 425 Miyazaki K, Nishibe T, Sata F, Murashita T, Kudo FA, Miyazaki YJ, et al. Long-term results of treatments for varicose veins due to greater saphenous vein insufficiency. *Int Angiol* 2005;**24**:282–6.
- 426 Rutgers PH, Kitslaar PJ. Randomized trial of stripping versus high ligation combined with sclerotherapy in the treatment of the incompetent greater saphenous vein. *Am J Surg* 1994;**168**:311–5.
- 427 Frings N, Nelle A, Tran P, Fischer R, Krug W. Reduction of neoreflux after correctly performed ligation of the saphenofemoral junction. A randomized trial. *Eur J Vasc Endovasc Surg* 2004;**28**:246–52.
- 428 De Maeseneer MG, Philipsen TE, Vandebroek CP, Lauwers PR, Hendriks JM, De Hert SG, et al. Closure of the cribriform fascia: an efficient anatomical barrier against post-operative neovascularisation at the saphenofemoral junction? A prospective study. *Eur J Vasc Endovasc Surg* 2007;**34**:361–6.
- 429 Winterborn RJ, Earnshaw JJ. Randomised trial of polytetrafluoroethylene patch insertion for recurrent great saphenous varicose veins. *Eur J Vasc Endovasc Surg* 2007;**34**:367–73.
- 430 Creton D, Rea B, Pittaluga P, Chastanet S, Allaert FA. Evaluation of the pain in varicose vein surgery under tumescent local anaesthesia using sodium bicarbonate as excipient without any intravenous sedation. *Phlebology* 2012;**27**:368–73.
- 431 Pittaluga P, Chastanet S, Guex JJ. Great saphenous vein stripping with preservation of sapheno-femoral confluence: hemodynamic and clinical results. *J Vasc Surg* 2008;**47**:1300–4.
- 432 Casoni P, Lefebvre-Vilardebo M, Villa F, Corona P. Great saphenous vein surgery without high ligation of the saphenofemoral junction. *J Vasc Surg* 2013;**58**:173–8.
- 433 Rasmussen LH, Lawaetz M, Serup J, Bjoern L, Vennits B, Blemler A, et al. Randomized clinical trial comparing endovenous laser ablation, radiofrequency ablation, foam sclerotherapy, and surgical stripping for great saphenous varicose veins with 3-year follow-up. *J Vasc Surg – Venous Lymphatics* 2013;**1**:349–56.
- 434 Olivencia JA. Minimally invasive vein surgery: ambulatory phlebectomy. *Tech Vasc Interv Radiol* 2003;**6**:121–4.
- 435 Ramelet AA. Phlebectomy. Technique, indications and complications. *Int Angiol* 2002;**21**:46–51.
- 436 Kabnick LS, Ombrellino M. Ambulatory phlebectomy. *Semin Intervent Radiol* 2005;**22**:218–24.
- 437 Almeida JJ, Raines JK. Ambulatory phlebectomy in the office. *Perspect Vasc Surg Endovasc Ther* 2008;**20**:348–55.
- 438 Carr SC. Update on venous procedures performed in the office setting. *Perspect Vasc Surg Endovasc Ther* 2009;**21**:21–6.
- 439 Proebstle TM, Paepcke U, Weisel G, Gass S, Weber L. High ligation and stripping of the long saphenous vein using the tumescent technique for local anesthesia. *Dermatol Surg* 1998;**24**:149–53.
- 440 Sadick NS, Wasser S. Combined endovascular laser plus ambulatory phlebectomy for the treatment of superficial venous incompetence: a 4-year perspective. *J Cosmet Laser Ther* 2007;**9**:9–13.
- 441 Kim HK, Kim HJ, Shim JH, Baek MJ, Sohn YS, Choi YH. Endovenous laser versus ambulatory phlebectomy of varicose tributaries in conjunction with endovenous laser treatment of the great or small saphenous vein. *Ann Vasc Surg* 2009;**23**:207–11.
- 442 Jung IM, Min SI, Heo SC, Ahn YJ, Hwang KT, Chung JK. Combined endovenous laser treatment and ambulatory phlebectomy for the treatment of saphenous vein incompetence. *Phlebology* 2008;**23**:172–7.
- 443 Cohn MS, Seiger E, Goldman S. Ambulatory phlebectomy using the tumescent technique for local anesthesia. *Dermatol Surg* 1995;**21**:315–8.
- 444 Ricci S. Ambulatory phlebectomy. Principles and evolution of the method. *Dermatol Surg* 1998;**24**:459–64.
- 445 Monahan DL. Can phlebectomy be deferred in the treatment of varicose veins? *J Vasc Surg* 2005;**42**:1145–9.
- 446 Welch HJ. Endovenous ablation of the great saphenous vein may avert phlebectomy for branch varicose veins. *J Vasc Surg* 2006;**44**:601–5.
- 447 Mekako A, Hatfield J, Bryce J, Heng M, Lee D, McCollum P, et al. Combined endovenous laser therapy and ambulatory phlebectomy: refinement of a new technique. *Eur J Vasc Endovasc Surg* 2006;**32**:725–9.
- 448 Carradice D, Mekako AI, Hatfield J, Chetter IC. Randomized clinical trial of concomitant or sequential phlebectomy after endovenous laser therapy for varicose veins. *Br J Surg* 2009;**96**:369–75.
- 449 Cooper DG, Hillman-Cooper CS, Barker SG, Hollingsworth SJ. Primary varicose veins: the sapheno-femoral junction, distribution of varicosities and patterns of incompetence. *Eur J Vasc Endovasc Surg* 2003;**25**:53–9.
- 450 Takase S, Pascarella L, Bergan JJ, Schmid-Schonbein GW. Hypertension-induced venous valve remodeling. *J Vasc Surg* 2004;**39**:1329–34.
- 451 Engelhorn CA, Engelhorn AL, Cassou MF, Salles-Cunha SX. Patterns of saphenous reflux in women with primary varicose veins. *J Vasc Surg* 2005;**41**:645–51.
- 452 Caggiati A, Rosi C, Heyn R, Franceschini M, Acconcia MC. Age-related variations of varicose veins anatomy. *J Vasc Surg* 2006;**44**:1291–5.
- 453 Labropoulos N, Kokkosis AA, Spentzouris G, Gasparis AP, Tassiopoulos AK. The distribution and significance of varicosities in the saphenous trunks. *J Vasc Surg* 2010;**51**:96–103.
- 454 Engelhorn CA, Manetti R, Baviera MM, Bombonato GM, Lonardoni M, Cassou MF, et al. Progression of reflux patterns in saphenous veins of women with chronic venous valvular insufficiency. *Phlebology* 2012;**27**:25–32.
- 455 Bernardini E, De Rango P, Piccioli R, Bisacci C, Pagliuca V, Genovese G, et al. Development of primary superficial venous insufficiency: the ascending theory. Observational and hemodynamic data from a 9-year experience. *Ann Vasc Surg* 2010;**24**:709–20.
- 456 Chastanet S, Pittaluga P. Patterns of reflux in the great saphenous vein system. *Phlebology* 2013;**28**(Suppl. 1):39–46.
- 457 Abu-Own A, Scurr JH, Coleridge Smith PD. Saphenous vein reflux without incompetence at the saphenofemoral junction. *Br J Surg* 1994;**81**:1452–4.
- 458 Pichot O, Sessa C, Bosson JL. Duplex imaging analysis of the long saphenous vein reflux: basis for strategy of endovenous obliteration treatment. *Int Angiol* 2002;**21**:333–6.
- 459 Wong JK, Duncan JL, Nichols DM. Whole-leg duplex mapping for varicose veins: observations on patterns of reflux in recurrent and primary legs, with clinical correlation. *Eur J Vasc Endovasc Surg* 2003;**25**:267–75.
- 460 Vidal-Michel JP, Bourrel Y, Emsallem J, Bonerandi JJ. Respect chirurgical des crosses saphenes internes moderement



- incontinentes par "effet siphon" chez les patients variqueux. *Phlébologie* 1993;**46**:143–7.
- 461 Zamboni P, Cisno C, Marchetti F, Quaglio D, Mazza P, Liboni A. Reflux elimination without any ablation or disconnection of the saphenous vein. A haemodynamic model for venous surgery. *Eur J Vasc Endovasc Surg* 2001;**21**:361–9.
- 462 Pittaluga P, Rea B, Barbe R. Méthode ASVAL (ablation sélective des varices sous anesthésie locale): Principes et résultats préliminaires. *Phlébologie* 2005;**58**:175–81.
- 463 Pittaluga P, Chastanet S, Locret T, Barbe R. The effect of isolated phlebectomy on reflux and diameter of the great saphenous vein: a prospective study. *Eur J Vasc Endovasc Surg* 2010;**40**:122–8.
- 464 Theivacumar NS, Darwood RJ, Gough MJ. Endovenous laser ablation (EVLA) of the anterior accessory great saphenous vein (AAGSV): abolition of sapheno-femoral reflux with preservation of the great saphenous vein. *Eur J Vasc Endovasc Surg* 2009;**37**:477–81.
- 465 Quill RD, Fegan WG. Reversibility of femorosaphenous reflux. *Br J Surg* 1971;**58**:389–93.
- 466 Creton D. Diameter reduction of the proximal long saphenous vein after ablation of a distal incompetent tributary. *Dermatol Surg* 1999;**25**:394–7.
- 467 Biemans AM, Van den Bos R, Hollestein LM, Maessen-Visch B, Vergouwe Y, Neumann HAM, et al. The effect of single phlebectomies or large varicose tributary on great saphenous vein reflux. *J Vasc Surg — Venous Lymf Dis* 2014;**2**:179–87.
- 468 Zamboni P, Cisno C, Marchetti F, Mazza P, Fogato L, Carandina S, et al. Minimally invasive surgical management of primary venous ulcers vs. compression treatment: a randomized clinical trial. *Eur J Vasc Endovasc Surg* 2003;**25**:313–8.
- 469 Carandina S, Mari C, De Palma M, Marcellino MG, Cisno C, Legnaro A, et al. Varicose vein stripping vs haemodynamic correction (CHIVA): a long term randomised trial. *Eur J Vasc Endovasc Surg* 2008;**35**:230–7.
- 470 Pares JO, Juan J, Tellez R, Mata A, Moreno C, Quer FX, et al. Varicose vein surgery: stripping versus the CHIVA method: a randomized controlled trial. *Ann Surg* 2010;**251**:624–31.
- 471 Cheshire N, Elias SM, Keagy B, Kolvenbach R, Leahy AL, Marston W, et al. Powered phlebectomy (TriVex) in treatment of varicose veins. *Ann Vasc Surg* 2002;**16**:488–94.
- 472 de Zeeuw R, Wittens C, Loots M, Neumann M. Transilluminated powered phlebectomy accomplished by local tumescent anaesthesia in the treatment of tributary varicose veins: preliminary clinical results. *Phlebology* 2007;**22**:90–4.
- 473 Arumugasamy M, McGreal G, O'Connor A, Kelly C, Bouchier-Hayes D, Leahy A. The technique of transilluminated powered phlebectomy — a novel, minimally invasive system for varicose vein surgery. *Eur J Vasc Endovasc Surg* 2002;**23**:180–2.
- 474 Shamiyeh A, Schrenk P, Huber E, Danis J, Wayand WU. Transilluminated powered phlebectomy: advantages and disadvantages of a new technique. *Dermatol Surg* 2003;**29**:616–9.
- 475 Scavee V, Lesceu O, Theys S, Jamart J, Louagie Y, Schoevaerdt JC. Hook phlebectomy versus transilluminated powered phlebectomy for varicose vein surgery: early results. *Eur J Vasc Endovasc Surg* 2003;**25**:473–5.
- 476 Scavee V. Transilluminated powered phlebectomy: not enough advantages? Review of the literature. *Eur J Vasc Endovasc Surg* 2006;**31**:316–9.
- 477 Passman M. Transilluminated powered phlebectomy in the treatment of varicose veins. *Vascular* 2007;**15**:262–8.
- 478 De Maeseener MGR, Hertoghs M, Lauwers K, Koeyers W, De Wolf M, Wittens C. Chronic venous insufficiency in patients with absence of the inferior vena cava. *J Vasc Surg — Venous Lymf Dis* 2013;**1**:39–44.
- 479 Hartung O, Loundou AD, Barthelemy P, Arnoux D, Boufi M, Alimi YS. Endovascular management of chronic disabling ilio-caval obstructive lesions: long-term results. *Eur J Vasc Endovasc Surg* 2009;**38**:118–24.
- 480 Nazarian GK, Austin WR, Wegryn SA, Bjarnason H, Stackhouse DJ, Castaneda-Zuniga WR, et al. Venous recanalization by metallic stents after failure of balloon angioplasty or surgery: four-year experience. *Cardiovasc Intervent Radiol* 1996;**19**:227–33.
- 481 Alhadad A, Kolbel T, Herbst A, Holst J, Alhadad H, Gottsater A. Iliocaval vein stenting: long term survey of postthrombotic symptoms and working capacity. *J Thromb Thrombolysis* 2011;**31**:211–6.
- 482 Alhalbouni S, Hingorani A, Shiferson A, Gopal K, Jung D, Novak D, et al. Iliac-femoral venous stenting for lower extremity venous stasis symptoms. *Ann Vasc Surg* 2012;**26**:185–9.
- 483 Kurklinsky AK, Bjarnason H, Friese JL, Wysokinski WE, McBane RD, Misselt A, et al. Outcomes of venoplasty with stent placement for chronic thrombosis of the iliac and femoral veins: single-center experience. *J Vasc Interv Radiol* 2012;**23**:1009–15.
- 484 Lou WS, Gu JP, He X, Chen L, Su HB, Chen GP, et al. Endovascular treatment for iliac vein compression syndrome: a comparison between the presence and absence of secondary thrombosis. *Korean J Radiol* 2009;**10**:135–43.
- 485 Meng QY, Li XQ, Qian AM, Sang HF, Rong JJ, Zhu LW. Endovascular treatment of iliac vein compression syndrome. *Chin Med J (Engl)* 2011;**124**:3281–4.
- 486 Nayak L, Hildebolt CF, Vedantham S. Postthrombotic syndrome: feasibility of a strategy of imaging-guided endovascular intervention. *J Vasc Interv Radiol* 2012;**23**:1165–73.
- 487 Neglen P, Hollis KC, Olivier J, Raju S. Stenting of the venous outflow in chronic venous disease: long-term stent-related outcome, clinical, and hemodynamic result. *J Vasc Surg* 2007;**46**:979–90.
- 488 Oguzkurt L, Tercan F, Ozkan U, Gulcan O. Iliac vein compression syndrome: outcome of endovascular treatment with long-term follow-up. *Eur J Radiol* 2008;**68**:487–92.
- 489 O'Sullivan GJ, Semba CP, Bittner CA, Kee ST, Razavi MK, Sze DY, et al. Endovascular management of iliac vein compression (May-Thurner) syndrome. *J Vasc Interv Radiol* 2000;**11**:823–36.
- 490 Raju S, Hollis K, Neglen P. Obstructive lesions of the inferior vena cava: clinical features and endovenous treatment. *J Vasc Surg* 2006;**44**:820–7.
- 491 Rosales A, Sandbaek G, Jorgensen JJ. Stenting for chronic post-thrombotic vena cava and iliofemoral venous occlusions: mid-term patency and clinical outcome. *Eur J Vasc Endovasc Surg* 2010;**40**:234–40.
- 492 Titus JM, Moise MA, Bena J, Lyden SP, Clair DG. Iliofemoral stenting for venous occlusive disease. *J Vasc Surg* 2011;**53**:706–12.
- 493 Ye K, Lu X, Li W, Huang Y, Huang X, Lu M, et al. Long-term outcomes of stent placement for symptomatic nonthrombotic iliac vein compression lesions in chronic venous disease. *J Vasc Interv Radiol* 2012;**23**:497–502.
- 494 de Wolf MAF, Arnoldussen CW, Grommes J, Hsien SG, Nelemans PJ, de Haan MW, et al. Minimally invasive

- treatment of chronic iliofemoral venous occlusive disease. *J Vasc Surg Venous Lymphatic Disord* 2013;**1**:146–53.
- 495 Garg N, Gloviczki P, Karimi KM, Duncan AA, Bjarnason H, Kalra M, et al. Factors affecting outcome of open and hybrid reconstructions for nonmalignant obstruction of iliofemoral veins and inferior vena cava. *J Vasc Surg* 2011;**53**:383–93.
- 496 Jost CJ, Gloviczki P, Cherry Jr KJ, McKusick MA, Harmsen WS, Jenkins GD, et al. Surgical reconstruction of iliofemoral veins and the inferior vena cava for nonmalignant occlusive disease. *J Vasc Surg* 2001;**33**:320–7.
- 497 AbuRahma AF, Robinson PA, Boland JP. Clinical, hemodynamic, and anatomic predictors of long-term outcome of lower extremity venovenous bypasses. *J Vasc Surg* 1991;**14**:635–44.
- 498 Belcaro G, Nicolaidis AN, Ricci A, Laurora G, Errichi BM, Christopoulos D, et al. External femoral vein valvuloplasty with limited anterior plication (LAP): a 10-year randomized, follow-up study. *Angiology* 1999;**50**:531–6.
- 499 Cheattle TR, Perrin M. Venous valve repair: early results in fifty-two cases. *J Vasc Surg* 1994;**19**:404–13.
- 500 Chen CJ, Guo SG, Luo D, Huang YQ. Full-valve annuloplasty in treatment of primary deep venous valvular incompetence of the lower extremities. *Chin Med J (Engl)* 1992;**105**:256–9.
- 501 Eriksson I, Almgren B. Influence of the profunda femoris vein on venous hemodynamics of the limb. Experience from thirty-one deep vein valve reconstructions. *J Vasc Surg* 1986;**4**:390–5.
- 502 Garcia-Rinaldi R, Soltero E, Gaviria J, Sosa J, Tucker P. Implantation of cryopreserved allograft pulmonary monocusp patch to treat nonthrombotic femoral vein incompetence. *Tex Heart Inst J* 2002;**29**:92–9.
- 503 Komai H, Juri M. Deep venous external valvuloplasty using a rigid angioscope. *Surg Today* 2010;**40**:538–42.
- 504 Lane RJ, Cuzzilla ML, McMahon CG. Intermediate to long-term results of repairing incompetent multiple deep venous valves using external valvular stenting. *ANZ J Surg* 2003;**73**:267–74.
- 505 Lehtola A, Oinonen A, Sugano N, Alback A, Lepantalo M. Deep venous reconstructions: long-term outcome in patients with primary or post-thrombotic deep venous incompetence. *Eur J Vasc Endovasc Surg* 2008;**35**:487–93.
- 506 Lugli M, Guerzoni S, Garofalo M, Smedile G, Maleti O. Neo-valve construction in deep venous incompetence. *J Vasc Surg* 2009;**49**:156–62.
- 507 Makarova NP, Lurie F, Hmelniker SM. Does surgical correction of the superficial femoral vein valve change the course of varicose disease? *J Vasc Surg* 2001;**33**:361–8.
- 508 Masuda EM, Kistner RL. Long-term results of venous valve reconstruction: a four- to twenty-one-year follow-up. *J Vasc Surg* 1994;**19**:391–403.
- 509 Perrin M, Hiltbrand B, Bayon JM. Results of valvuloplasty in patients presenting deep venous insufficiency and recurring ulceration. *Ann Vasc Surg* 1999;**13**:524–32.
- 510 Raju S, Fredericks RK, Neglen PN, Bass JD. Durability of venous valve reconstruction techniques for “primary” and post-thrombotic reflux. *J Vasc Surg* 1996;**23**:357–66.
- 511 Raju S, Hardy JD. Technical options in venous valve reconstruction. *Am J Surg* 1997;**173**:301–7.
- 512 Raju S, Berry MA, Neglen P. Transcommissural valvuloplasty: technique and results. *J Vasc Surg* 2000;**32**:969–76.
- 513 Raju S, Darcey R, Neglen P. Unexpected major role for venous stenting in deep reflux disease. *J Vasc Surg* 2010;**51**:401–8.
- 514 Rosales A, Jorgensen JJ, Slagsvold CE, Stranden E, Risum O, Kroese AJ. Venous valve reconstruction in patients with secondary chronic venous insufficiency. *Eur J Vasc Endovasc Surg* 2008;**36**:466–72.
- 515 Sottiurai VS. Surgical correction of recurrent venous ulcer. *J Cardiovasc Surg (Torino)* 1991;**32**:104–9.
- 516 Taheri SA, Heffner R, Budd T, Pollack LH. Five years’ experience with vein valve transplant. *World J Surg* 1986;**10**:935–7.
- 517 Tripathi R, Sieunarine K, Abbas M, Durrani N. Deep venous valve reconstruction for non-healing leg ulcers: techniques and results. *ANZ J Surg* 2004;**74**:34–9.
- 518 Us M, Basaran M, Sanioglu S, Ogun NT, Ozbek C, Yildirim T, et al. The use of external banding increases the durability of transcommissural external deep venous valve repair. *Eur J Vasc Endovasc Surg* 2007;**33**:494–501.
- 519 Wang SM, Hu ZJ, Li SQ, Huang XL, Ye CS. Effect of external valvuloplasty of the deep vein in the treatment of chronic venous insufficiency of the lower extremity. *J Vasc Surg* 2006;**44**:1296–300.
- 520 Hardy SC, Riding G, Abidia A. Surgery for deep venous incompetence. *Cochrane Database Syst Rev* 2004:CD001097.
- 521 Maleti O, Perrin M. Reconstructive surgery for deep vein reflux in the lower limbs: techniques, results and indications. *Eur J Vasc Endovasc Surg* 2011;**41**:837–48.
- 522 Jones L, Braithwaite BD, Selwyn D, Cooke S, Earnshaw JJ. Neovascularisation is the principal cause of varicose vein recurrence: results of a randomised trial of stripping the long saphenous vein. *Eur J Vasc Endovasc Surg* 1996;**12**:442–5.
- 523 Negus D. Recurrent varicose veins: a national problem. *Br J Surg* 1993;**80**:823–4.
- 524 Fischer R, Chandler JG, De Maeseneer MG, Frings N, Lefebvre-Vilarbedo M, Earnshaw JJ, et al. The unresolved problem of recurrent saphenofemoral reflux. *J Am Coll Surg* 2002;**195**:80–94.
- 525 Perrin MR, Guex JJ, Ruckley CV, dePalma RG, Royle JP, Eklöf B, et al. Recurrent varices after surgery (REVAS), a consensus document. REVAS group. *Cardiovasc Surg* 2000;**8**:233–45.
- 526 Perrin M, Allaert FA. Intra- and inter-observer reproducibility of the Recurrent Varicose Veins after Surgery (REVAS) classification. *Eur J Vasc Endovasc Surg* 2006;**32**:326–32.
- 527 van Rij AM, Jones GT, Hill GB, Jiang P. Neovascularization and recurrent varicose veins: more histologic and ultrasound evidence. *J Vasc Surg* 2004;**40**:296–302.
- 528 Marsh P, Holdstock J, Harrison C, Smith C, Price BA, Whiteley MS. Pelvic vein reflux in female patients with varicose veins: comparison of incidence between a specialist private vein clinic and the vascular department of a National Health Service District General Hospital. *Phlebology* 2009;**24**:108–13.
- 529 Hiromura T, Nishioka T, Nishioka S, Ikeda H, Tomita K. Reflux in the left ovarian vein: analysis of MDCT findings in asymptomatic women. *Am J Roentgenol* 2004;**183**:1411–5.
- 530 Balian E, Lasry J, Coppe G, Borie H, Leroux A, Bryon D, et al. Pelviperineal venous insufficiency and varicose veins of the lower limbs. *Phlebology* 2008;**15**:2.
- 531 Ascitutto G, Mumme A, Ascitutto KC, Geier B. Oestradiol levels in varicose vein blood of patients with and without pelvic vein incompetence (PVI): diagnostic implications. *Eur J Vasc Endovasc Surg* 2010;**40**:117–21.
- 532 Bergqvist A, Bergqvist D, Ferno M. Estrogen and progesterone receptors in vessel walls. Biochemical and immunochemical assays. *Acta Obstet Gynecol Scand* 1993;**72**:10–6.
- 533 Mashiah A, Berman V, Thole HH, Rose SS, Pasik S, Schwarz H, et al. Estrogen and progesterone receptors in normal and varicose saphenous veins. *Cardiovasc Surg* 1999;**7**:327–31.

- 534 Blomgren L, Johansson G, Emanuelsson L, Dahlberg-Akerman A, Thermaenius P, Bergqvist D. Late follow-up of a randomized trial of routine duplex imaging before varicose vein surgery. *Br J Surg* 2011;**98**:1112–6.
- 535 Theivacumar NS, Darwood RJ, Dellegrammaticas D, Mavor AI, Gough MJ. The clinical significance of below-knee great saphenous vein reflux following endovenous laser ablation of above-knee great saphenous vein. *Phlebology* 2009;**24**:17–20.
- 536 Merchant RF, Pichot O, Closure Study G. Long-term outcomes of endovenous radiofrequency obliteration of saphenous reflux as a treatment for superficial venous insufficiency. *J Vasc Surg* 2005;**42**:502–9.
- 537 Blomgren L, Johansson G, Dahlberg AA, Noren A, Brundin C, Nordstrom E, et al. Recurrent varicose veins: incidence, risk factors and groin anatomy. *Eur J Vasc Endovasc Surg* 2004;**27**:269–74.
- 538 De Maeseneer MG. The role of postoperative neovascularisation in recurrence of varicose veins: from historical background to today's evidence. *Acta Chir Belg* 2004;**104**:283–9.
- 539 Munasinghe A, Smith C, Kianifard B, Price BA, Holdstock JM, Whiteley MS. Strip-track revascularization after stripping of the great saphenous vein. *Br J Surg* 2007;**94**:840–3.
- 540 Lim CS, Gohel MS, Shepherd AC, Paleolog E, Davies AH. Venous hypoxia: a poorly studied etiological factor of varicose veins. *J Vasc Res* 2011;**48**:185–94.
- 541 Brake M, Lim CS, Shepherd AC, Shalhoub J, Davies AH. Pathogenesis and etiology of recurrent varicose veins. *J Vasc Surg* 2013;**57**:860–8.
- 542 Luebke T, Brunkwall J. Systematic review and meta-analysis of endovenous radiofrequency obliteration, endovenous laser therapy, and foam sclerotherapy for primary varicosis. *J Cardiovasc Surg (Torino)* 2008;**49**:213–33.
- 543 Allegra C, Antignani PL, Carlizza A. Recurrent varicose veins following surgical treatment: our experience with five years follow-up. *Eur J Vasc Endovasc Surg* 2007;**33**:751–6.
- 544 Gandhi A, Froghi F, Shepherd AC, Shalhoub J, Lim CS, Gohel MS, et al. A study of patient satisfaction following endothermal ablation for varicose veins. *Vasc Endovascular Surg* 2010;**44**:274–8.
- 545 Pittaluga P, Chastanet S, Locret T, Rousset O. Retrospective evaluation of the need of a redo surgery at the groin for the surgical treatment of varicose vein. *J Vasc Surg* 2010;**51**:1442–50.
- 546 De Maeseneer M. Surgery for recurrent varicose veins: toward a less-invasive approach? *Perspect Vasc Surg Endovasc Ther* 2011;**23**:244–9.
- 547 Theivacumar NS, Gough MJ. Endovenous laser ablation (EVLA) to treat recurrent varicose veins. *Eur J Vasc Endovasc Surg* 2011;**41**:691–6.
- 548 Nwaejike N, Srodon PD, Kyriakides C. Endovenous laser ablation for the treatment of recurrent varicose vein disease – a single centre experience. *Int J Surg* 2010;**8**:299–301.
- 549 van Groenendaal L, Flinkenflugel L, van der Vliet JA, Roovers EA, van Sterkenburg SM, Reijnen MM. Conventional surgery and endovenous laser ablation of recurrent varicose veins of the small saphenous vein: a retrospective clinical comparison and assessment of patient satisfaction. *Phlebology* 2010;**25**:151–7.
- 550 Dimakakos PB, Kotsis TE. Arteriovenous malformations. In: Liapis CD, editor. *Vascular Surgery; European Manual of Medicine*. New York: Springer; 2007. p. 573–83.
- 551 Redondo P. Malformaciones vasculares (I). Concepto, clasificación, fisiopatogenia y manifestaciones clínicas. *Actas Dermo-sifiliogr* 2007;**98**:141–58.
- 552 Mulliken JB, Glowacki J. Hemangiomas and vascular malformations in infants and children: a classification based on endothelial characteristics. *Plast Reconstr Surg* 1982;**69**:412–22.
- 553 Mulliken JB. Vascular malformations of the head and neck. In: Mulliken JB, Young AE, editors. *Vascular birthmarks, haemangiomas and vascular malformations*. Philadelphia: Saunders; 1988.
- 554 Belov S. Classification of congenital vascular defects. *Int Angiol* 1990;**9**:141–6.
- 555 Puig S, Aref H, Chigot V, Bonin B, Brunelle F. Classification of venous malformations in children and implications for sclerotherapy. *Pediatr Radiol* 2003;**33**:99–103.
- 556 Legiehn GM, Heran MK. Venous malformations: classification, development, diagnosis, and interventional radiologic management. *Radiol Clin North Am* 2008;**46**:545–597, vi.
- 557 Boon LM, Mulliken JB, Enjolras O, Vikkula M. Glomuvenous malformation (glomangioma) and venous malformation: distinct clinicopathologic and genetic entities. *Arch Dermatol* 2004;**140**:971–6.
- 558 Dubois J, Soulez G, Oliva VL, Berthiaume MJ, Lapierre C, Therasse E. Soft-tissue venous malformations in adult patients: imaging and therapeutic issues. *Radiographics* 2001;**21**:1519–31.
- 559 Mazoyer E, Enjolras O, Laurian C, Houdart E, Drouet L. Coagulation abnormalities associated with extensive venous malformations of the limbs: differentiation from Kasabach-Merritt syndrome. *Clin Lab Haematol* 2002;**24**:243–51.
- 560 Trop I, Dubois J, Guibaud L, Grignon A, Patriquin H, McCuaig C, et al. Soft-tissue venous malformations in pediatric and young adult patients: diagnosis with Doppler US. *Radiology* 1999;**212**:841–5.
- 561 Ernemann U, Kramer U, Miller S, Bisdas S, Rebmann H, Breuninger H, et al. Current concepts in the classification, diagnosis and treatment of vascular anomalies. *Eur J Radiol* 2010;**75**:2–11.
- 562 Enjolras O, Ciabrini D, Mazoyer E, Laurian C, Herbreteau D. Extensive pure venous malformations in the upper or lower limb: a review of 27 cases. *J Am Acad Dermatol* 1997;**36**:219–25.
- 563 Rautio R, Saarinen J, Laranne J, Salenius JP, Keski-Nisula L. Endovascular treatment of venous malformations in extremities: results of sclerotherapy and the quality of life after treatment. *Acta Radiol* 2004;**45**:397–403.
- 564 Lee BB, Do YS, Byun HS, Choo IW, Kim DI, Huh SH. Advanced management of venous malformation with ethanol sclerotherapy: mid-term results. *J Vasc Surg* 2003;**37**:533–8.
- 565 Tan KT, Kirby J, Rajan DK, Hayeems E, Beecroft JR, Simons ME. Percutaneous sodium tetradecyl sulfate sclerotherapy for peripheral venous vascular malformations: a single-center experience. *J Vasc Interv Radiol* 2007;**18**:343–51.
- 566 Blaise S, Charavin-Cocuzza M, Riom H, Brix M, Seinturier C, Diamand JM, et al. Treatment of low-flow vascular malformations by ultrasound-guided sclerotherapy with polidocanol foam: 24 cases and literature review. *Eur J Vasc Endovasc Surg* 2011;**41**:412–7.
- 567 Yamaki T, Nozaki M, Sakurai H, Takeuchi M, Soejima K, Kono T. Prospective randomized efficacy of ultrasound-guided foam sclerotherapy compared with ultrasound-guided liquid sclerotherapy in the treatment of symptomatic venous malformations. *J Vasc Surg* 2008;**47**:578–84.

- 568 Klippel M, Trenaunay P. Du naevus variqueux osteohyper-trophique. *Arch Gen Med* 1900;**3**:641–72.
- 569 Lee A, Driscoll D, Gloviczki P, Clay R, Shaughnessy W, Stans A. Evaluation and management of pain in patients with Klippel-Trenaunay syndrome: a review. *Pediatrics* 2005;**115**:744–9.
- 570 Baskerville PA, Ackroyd JS, Browse NL. The etiology of the Klippel-Trenaunay syndrome. *Ann Surg* 1985;**202**:624–7.
- 571 Servelle M, Babillot J. Les malformations des veines profondes dans le syndrome de Klippel et Trenaunay. *Phlébologie* 1980;**33**:31–6.
- 572 Tian XL, Kadaba R, You SA, Liu M, Timur AA, Yang L, et al. Identification of an angiogenic factor that when mutated causes susceptibility to Klippel-Trenaunay syndrome. *Nature* 2004;**427**:640–5.
- 573 Noel AA, Gloviczki P, Cherry Jr KJ, Rooke TW, Stanson AW, Driscoll DJ. Surgical treatment of venous malformations in Klippel-Trenaunay syndrome. *J Vasc Surg* 2000;**32**:840–7.
- 574 Chaudry MI, Manzoor MU, Turner RD, Turk AS. Diagnostic imaging of vascular anomalies. *Facial Plast Surg* 2012;**28**:563–74.
- 575 Jacob AG, Driscoll DJ, Shaughnessy WJ, Stanson AW, Clay RP, Gloviczki P. Klippel-Trenaunay syndrome: spectrum and management. *Mayo Clin Proc* 1998;**73**:28–36.
- 576 Baskerville PA, Ackroyd JS, Lea Thomas M, Browse NL. The Klippel-Trenaunay syndrome: clinical, radiological and haemodynamic features and management. *Br J Surg* 1985;**72**:232–6.
- 577 Gloviczki P, Driscoll DJ. Klippel-Trenaunay syndrome: current management. *Phlebology* 2007;**22**:291–8.
- 578 Zea MI, Hanif M, Habib M, Ansari A. Klippel-Trenaunay syndrome: a case report with brief review of literature. *J Dermatol Case Rep* 2009;**3**:56–9.
- 579 Nitecki S, Bass A. Ultrasound-guided foam sclerotherapy in patients with Klippel-Trenaunay syndrome. *Isr Med Assoc J* 2007;**9**:72–5.
- 580 Gloviczki P, Stanson AW, Stickler GB, Johnson CM, Toomey BJ, Meland NB, et al. Klippel-Trenaunay syndrome: the risks and benefits of vascular interventions. *Surgery* 1991;**110**:469–79.
- 581 Frasier K, Giangola G, Rosen R, Ginat DT. Endovascular radiofrequency ablation: a novel treatment of venous insufficiency in Klippel-Trenaunay patients. *J Vasc Surg* 2008;**47**:1339–45.
- 582 King K, Landrigan-Ossar M, Clemens R, Chaudry G, Alomari A. The use of endovenous laser treatment in toddlers. *J Vasc Interv Radiol* 2013;**24**:855–8.
- 583 Abdul-Rahman NR, Mohammad KF, Ibrahim S. Gigantism of the lower limb in Klippel-Trenaunay syndrome: anatomy of the lateral marginal vein. *Singapore Med J* 2009;**50**:e223–5.
- 584 Revencu N, Boon LM, Mulliken JB, Enjolras O, Cordisco MR, Burrows PE, et al. Parkes Weber syndrome, vein of Galen aneurysmal malformation, and other fast-flow vascular anomalies are caused by RASA1 mutations. *Hum Mutat* 2008;**29**:959–65.
- 585 Robertson DJ. Congenital arteriovenous fistulae of the extremities. *Ann R Coll Surg Engl* 1956;**18**:73–98.
- 586 Cohen Jr MM. Vascular update: morphogenesis, tumors, malformations, and molecular dimensions. *Am J Med Genet A* 2006;**140**:2013–38.
- 587 Konez O, Ruggieri M, Di Rocco C. Parkes Weber syndrome. In: Ruggieri M, Pascual-Castroviejo I, Di Rocco C, editors. *Neurocutaneous disorders phakomatoses and hamartoneoplastic syndromes*. Wien, Germany: Springer; 2008. p. 277–85.
- 588 Giron-Vallejo O, Lopez-Gutierrez JC, Fernandez-Pineda I. Diagnosis and treatment of Parkes Weber syndrome: a review of 10 consecutive patients. *Ann Vasc Surg* 2013;**27**:820–5.